[Downloaded free from http://www.jpbsonline.org on Monday, November 27, 2017, IP: 106.203.126.106]

Review Article

Molecular Pathogenesis and Diagnostic Imaging of Metastatic Jaw Tumors

Kenniyan Kumar Srichinthu, Arjun Parameshwar Raveendran[1], Periyasamy Tamilthangam[2], Joseph Joe[3], Charanya Duraisamy[4], Thukanayakanpalayam Ragunathan Yoithapprabhunath[2], Chitturi Ravi Teja[5]

Department of Oral and Maxillofacial Pathology, KSR Institute of Dental Science and Research, [2]Department of Oral and Maxillofacial Pathology, Vivekanandha Dental College for Women, Elayampalayam, Thiruchengodu, Namakkal, Tamil Nadu, [1]Departments of Oral and Maxillofacial Pathology and [3]Departments of Orthodontics, Pushpagiri College of Dental Sciences, Perumthuruthy, Kerela, [4]Department of Oral Medicine and Radiology, Regional Institute of Medical Sciences, Manipur, India, [5]Department of Oral Biology, The University of the West Indies, St. Augustine, Trinidad and Tobago

ABSTRACT

Metastasis is the spread of malignant cells from a primary tumor to distant sites through lymphatics or blood vessels. Malignant lesions metastasizing to the oral and perioral region are a rarity indeed. Malignant lesions could metastasize to both soft tissue of oral cavity and the hard tissues of the jaws and recent meta-analysis showed that metastasis is more common in the jaws than oral soft tissues because of rich vascular supply. The incidence is very low when compared to the incidence of primary oral cancers; nevertheless, one has to include in the diagnostic workup, metastatic malignant lesions, when an irregular ill-defined radiolucency or radiodensity with ragged edges in noted. It could be a challenging task for a diagnostician, in cases with the presence and location of the primary tumor is unknown. Advanced oral imaging technologies and biochemical markers play a vital role in diagnosing such lesions.

KEYWORDS: *Biochemical markers, imaging science, malignancies, metastasis, oral cancer*

INTRODUCTION

Malignant tumors involving the jaw bones are most often due to direct extension of the disease either from the oral cavity or from the surrounding tissues. Metastatic tumors of jaw bones constitutes about 1% of all the malignancies occurring in jaw and mostly affect the mandible region than the maxilla. The younger patient is affected more commonly with almost equal gender distribution. These metastatic tumors on jaws can deposit from any primary tumors arising from lungs, kidney, prostate, thyroid, and breast. In about 30% of cases, the oral lesions are the first sign of this disease and are very tough to diagnosis in histopathology because it takes the clones of primary cancer.[1-3]

The microenvironment of the bone matrix is a vast storehouse of growth factors such as platelet-derived growth factor (PDGF), insulin-like growth factor (IGF), osteoprotegerin (OPG), bone morphogenetic protein (BMP), transforming growth factor (TGF)-β, and vascular endothelial growth factor (VEGF) and these factors get released during bone remodeling.[4] The release of these factors may promote cell homing and appears to promote colonization by stimulating vicious cycle and leads to tumor cell proliferation and progression of osteolytic and osteoblastic bone lesions.[5,6] Metastatic tumor cause changes in bone architecture, which predisposes the patient to a variety of skeletal complications.

Access this article online

Quick Response Code:

Website: www.jpbsonline.org

DOI: 10.4103/jpbs.JPBS_138_17

Address for correspondence: Dr. Thukanayakanpalayam Ragunathan Yoithapprabhunath, Department of Oral and Maxillofacial Pathology, Vivekanandha Dental College for Women, Elayampalayam, Thiruchengodu, Namakkal - 637 205, Tamil Nadu, India.
E-mail: yoitha.dentist@gmail.com

This is an open access article distributed under the terms of the Creative Commons Attribution-NonCommercial-ShareAlike 3.0 License, which allows others to remix, tweak, and build upon the work non-commercially, as long as the author is credited and the new creations are licensed under the identical terms.

For reprints contact: reprints@medknow.com

How to cite this article: Srichinthu KK, Raveendran AP, Tamilthangam P, Joe J, Duraisamy C, Yoithapprabhunath TR, *et al.* Molecular pathogenesis and diagnostic imaging of metastatic jaw tumors. J Pharm Bioall Sci 2017;9:S15-22.

[Downloaded free from http://www.jpbsonline.org on Monday, November 27, 2017, IP: 106.203.126.106]

Physiology of bone formation and resorption

Bone is formed primarily of type I collagen and later gets mineralized with hydroxyapatite crystals. Continuous undergoing of osteoclast-mediated bone resorption and osteoblast-mediated bone formation are the coupled and sequential process of dynamic remodeling happening within the bone throughout the life. Osteoblasts, osteoclasts, and other cells involve a very close crosstalk within the bone microenvironment with the help of numerous growth factors, hormones, cellular molecules, and proteins, during this formation and resorption process.[7,8] Mesenchymal stem cells in the bone marrow stroma proliferate when it is stimulated by bone morphogenic proteins and other growth factors, and form pre-osteoblasts that differentiate into osteoblasts. Osteoblasts produce collagen matrix (osteoid) which is the precursor of bone and regulate bone mineralization. Bone regulating molecules such as parathyroid hormone receptors, prostaglandins, estrogen, Vitamin D3, and various cytokines will be expressed by osteoblast. They are also involved directly with the control of osteoclast differentiation through expression of receptor activator of nuclear factor κB ligand (RANKL).[7,9-15] Osteoclasts are derived from precursor cells in the monocyte-macrophage lineage. Osteoclast production is stimulated by prostaglandins, interleukin 6 (IL-6), IL-1, and macrophage colony-stimulating factors. Activation of osteoclast is based on the balance between osteoblast secreted RANKL and OPG levels. Activated osteoclasts degrade bone by binding to bone matrix through integrin proteins and secreting acid and lysosomal enzymes.[16-25] Wingless int (Wnt) pathway is also found to be a key regulator of osteoblast function and bone formation and activation of this Wnt/B-catenin signaling pathway leads to increased bone deposition [Figure 1].[7,26]

Mechanisms of Metastasis

Metastasis is the spread of malignant cells from a primary tumor to distant sites. This occurs in a series of individual steps, which is called as "metastatic cascade."

- Step 1: Epithelial-mesenchymal transition (EMT) and breach of the basement membrane barrier
- Step 2: Dissociation of tumor cells from the bulk tumor
- Step 3: Invasion into the neighboring tissue
- Step 4: Intravasation into preexisting and newly formed blood and lymph vessels (angiogenesis)
- Step 5: Transport of disseminated tumor cells through vessels
- Step 6: Extravasation of tumor cells from vessels
- Step 7: Establishment of disseminated cells (which can stay dormant for a prolonged period of time) at a secondary anatomical site and
- Step 8: Outgrowth of micrometastasis and macrometastasis/secondary tumors.[27-31]

Recent studies in this area have suggested yet another step, to be added at the beginning of the cascade and therefore designated as:

Step 0: The creation of target site before the first tumor cells arrive at this distant location, "premetastatic niche."[5,26,32,33]

Each step creates one or more physiological barriers to the spread of malignant cells. Tumor cells have to overcome all of those barriers, for successful metastasis

Microenvironment within the bone contains two groups of cells which contribute to the metastatic bone niche formation. They are stromal cells and transient cells. Stromal cells arise from mesenchymal cells in the marrow (adipocytes, fibroblasts, and osteoblasts). They sustain the differentiation and proliferation of cancer cells through molecules such as vascular cell adhesion molecule, syndecan-1, and matrix metalloproteinase 2 (MMP-2). Transient cells (erythrocytes, T-cells, and platelets) all aid tumor growth and metastases through various pathways and molecules.[7,16,34] EMT is likely to contain several intermediate steps such as downregulation of epithelial proteins, loss of cell polarity, loss of cell-cell adhesion, cell scattering, secretion of protein degrading enzymes, induction of mesenchymal proteins, and inhibition of apoptosis.[21,35-38] Continuous cycle of actin polymerization and depolymerization results in extension of cell membrane protrusions which help cell migration.[21,39]

Cell death induced by inappropriate or loss of cell adhesion is called Anoikis. When tumor cells enter unfamiliar environments, anoikis could obstruct metastasis by inducing apoptosis. Anoikis suppression, therefore, is likely to be an essential requirement for tumor cells to successfully metastasize to distant sites.[21,40,41] Tumor cell invasion alone is not sufficient to produce distant metastases but also the transport of malignant cells through blood and/or lymph vessels. Passive diffusion of nutrients and oxygen becomes rate limiting for the tumor nodule and restrict avascular tumors to grow beyond 1 mm in diameter. Hence, it is then forced to enter a state called tumor dormancy (cells cease dividing but survive in a quiescent state while waiting for appropriate environmental conditions to begin proliferation again).[42] At this stage, angiogenic switch (which is a loss of balance between stimulation and inhibition of new blood vessel growth) gets activated and the tumor grows beyond its diffusion limit.[43] The

[Downloaded free from http://www.jpbsonline.org on Monday, November 27, 2017, IP: 106.203.126.106]

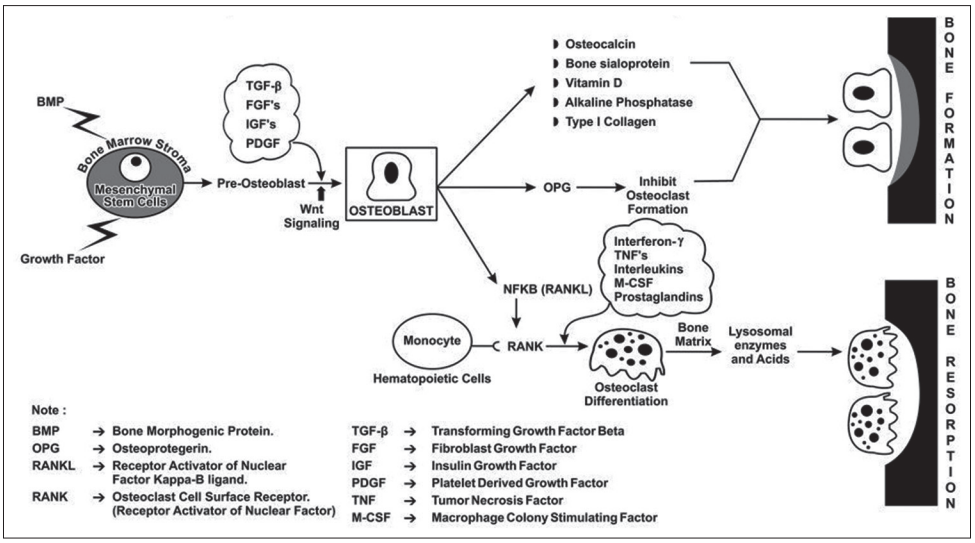

Figure 1: Physiology of bone

presence of tumor cells in regional lymph nodes draining the primary tumor site can precede distant metastasis to visceral organs.[21,44]

Earlier studies suggested that tumor-associated macrophages play a crucial role in guiding tumor cells to blood vessels and sites of intravasation (directional cell migration).[45] Extravasation of the transported tumor cell at predestined site is depended on integrins and ezrin, possibly suppressing anoikis.[46] Integrins have a vital position in the interaction of tumor cells not only with platelets and leukocytes but also with endothelial cells. The interaction of tumor cells with platelets also plays an important role in extravasation of tumor cells. Metastasis can be impaired by the presence of anticoagulation agents within the blood vessels.[21] "Soil and seed hypothesis" stating that certain tumor cells (seeds) will selectively colonize distant organs (soil) because of the presence of a favorable environment for their localization and growth. An emerging concept has recently challenged this existing model of metastasis by demonstrating that the potential to metastasize is encoded in the bulk of the tumor and is present early in tumor pathogenesis.[5,21,47]

The basic principle for the formation of a primary tumor and metastatic tumors remains same. Metastasis suppressor genes when overexpressed impair metastasis without affecting primary tumor growth.[21] Cancer stem cells (CSCs) in particular that eventually establish the macro metastases. Till date, the link between CSCs and metastasis is the overexpression of stem cell-associated genes in metastatic tumors.[21,48] Cancer-associated fibroblasts which are often referred as myofibroblast or activated fibroblast is a major component of tumor stroma. When these cells get in contact with the tumor cells, it stimulates tumor growth and angiogenesis.[21,49,50]

Table 1: Osteolytic and osteoblastic metastasis

Ostolytic metastasis	Osteoblastic metastasis
Breast, lung, myeloma, and kidney malignancies are responsible for forming the osteolytic metastasis	Prostate and carcinoid malignancies are responsible for forming the osteoblastic metastases
Originate from monocytes\ macrophage precursor in bone marrow	Originate from bone marrow stromal progenitor cell
Factors involved in the pathogenesis of osteolytic metastasis	**Factors involved in the pathogenesis of osteoblastic metastasis**
PTHrP	Wnt
Soluble RANKL	ET-1
IL-6	BMP
IL-1	IGF-1, 2
TNF-α	IL-6
IL-8	OPG
IL-11	TGF-β
M-CSF	uPA
TGF-β	PDGF-BB
Prostaglandin	FGF-1, 2, 8
VEGF	PSA
MMPs	MDA-BF-1
↓IGF, ↓PTH, ↓IL, ↓TGF-β	↑TGF-β, ↑FGF, ↑BMP, ↑MMP, ↑PDGF
Activated by RANK\RANKL\ OPG and CSF-1 signaling	Activated by Wnt signaling and ET-1

PTHrP: Parathyroid hormone-related peptide, Wnt: Wingless int, RANKL: Receptor activator of NF-Kappa B ligand, IL: Interluekin, TNF: Tumor necrosis factor, OPG: Osteoprotegerin, ET: Endothelin, BMP: Bone morphogenic protein, IGF: Insulin-like growth factor, M-CSF: Macrophage colony-stimulating factor, TGF: Transforming growth factor, uPA: Urokinase plasminogen activator, VEGF: Vascular endothelial growth factor, MMPs: Matrix metaloprotinases, PDGF: Platelet-derived growth factor, FGF: Fibroblast growth factor, PSA: Prostate-specific antigen, MDA-BF: Bone metastasis-related factor, ↓ - Downregulation and ↑ - Upregulation

[Downloaded free from http://www.jpbsonline.org on Monday, November 27, 2017, IP: 106.203.126.106]

<table>
<tr><th>Imaging techniques</th><th colspan="3">Advantages</th><th>Limitations</th></tr>
<tr><td rowspan="6">Radiograph (X-ray)</td><td colspan="3">• Most widely used method for characterizing bone metastases</td><td rowspan="6">• Insensitive in the detection of early or small metastatic lesions
• Only lesions ≥ 2 cm and loss of more than 50% of the bone mineral content at the site of disease are apparent.</td></tr>
<tr><td>PATTERN OF THE LESION</td><td>MORPHOLOGICAL ALTERATION IN BONE</td><td>RADIOGRAPHIC PICTURE</td></tr>
<tr><td>Osteolytic lesions</td><td>Destruction of bone</td><td>Generally recognized as a hole in the cortex</td></tr>
<tr><td>Osteoblastic lesions</td><td>Excess deposition of new bone</td><td>More dense bone, whiter than the surrounding bone(osteosclerotic appearance)</td></tr>
<tr><td>Osteoporotic lesions</td><td>Faded bone</td><td>Without discrete areas of cortical destruction or increased density</td></tr>
<tr><td>Mixed lesions</td><td>Combination of bone destruction and new bone deposition</td><td>Central clear area of cortical lysis surrounded by an area of increased density (sclerosis).</td></tr>
<tr><td>Computed tomography (CT)</td><td colspan="3">• Superior to radiographs
• Evaluating focal abnormalities
• Radiographically negative metastasized areas can be spotted
• Sensitive in detection of trabecular and cortical bone destruction, level of extension into soft-tissue, and involvement of neurovascular structures</td><td>• Insensitive to small intramedullary lesions in the absence of reactive new bone involvement
• Detection of early deposits within bone marrow</td></tr>
<tr><td>^{99m} Tc bone scintigraphy (^{99m} Tc methylene diphosphonate (MDP), is the most frequently used isotope.)</td><td colspan="3">• Technically effective
• Determining the extent of bone metastasis
• Differentiating metastatic tumors from traumatic fracture
• Determining therapeutic response
• Cost effective</td><td>• Sensitive but nonspecific</td></tr>
<tr><td>Magnetic Resonance Imaging (MRI)</td><td colspan="3">• Accurate technique
• More sensitive than ^{99m} Tc bone scintigraphy
• To differentiate metastasis from benign bone lesion (Bull's eye or halo sign)[88]</td><td>• Expensive
• Gadolinium (contrast agent) allergy</td></tr>
<tr><td>Fluorodeoxyglucose (FDG) Positron emission tomography (PET)</td><td colspan="3">• More sensitive than any other technique
• Identifying bone metastasis (bone marrow) at very early stage of growth</td><td>• High cost
• Limited spatial resolution
• Complementary CT scanning or MRI is required to localize an area of increased glucose metabolism
• Less sensitive to differentiate bone metastasis from osteosarcoma</td></tr>
<tr><td>Angiography</td><td colspan="3">• Shows devascularization of vascular metastases before surgical intervention</td><td>• Very limited role in the diagnosis and evaluation of bone metastasis</td></tr>
</table>

Figure 2: Advantages and limitations of imaging techniques in diagnosing metastatic jaw tumors

[Downloaded free from http://www.jpbsonline.org on Monday, November 27, 2017, IP: 106.203.126.106]

Molecular Events Involved in Metastatic Tumors of Jawbones

Large size primary cancer favors pre metastatic niche formation.[26,51,52] Chemokine receptor type 4 (CXCR4) is expressed on orthotropic cancer cells. Bone microenvironment secretes stromal derived factor-1 and generates a chemoattractant signal through its receptor ligand, for which CXCR4 responds. Marrow rich metaphysis of jaw bone has abundant sinusoids and sluggish blood flow (especially in mandibular retromolar area which has more red bone marrow than other jaw sites) influences the interaction between endothelium and tumor cells. This attachment of metastatic cells gets extravasated latter and are colonized in the bone marrow.[5,26,53-56] Parathyroid hormone-related peptide (PTHrP) upregulates RANKL expression and decreases OPG expression.[57,58] Soluble RANKL stimulates osteoclastogenesis by binding directly to RANK.[59] IL and TNF-α increases osteoclastogenesis, enhances the effect of PTHrP, promotes osteoclast activation and survival.[60,61] M-CSF upregulates RANKL expression on stromal cells. It has chemotactic role for attracting osteoclasts to resorptive sites and prolongs survival of the mature osteoclast by inhibiting apoptosis. to resorptive sites and prolongs survival of the mature osteoclast by inhibiting apoptosis.[62] TGF-β in the absence of RANKL directly stimulates osteoclast formation.[63] VEGF induces angiogenesis and promotes osteoclastogenesis.[64] MMPs help osteoclast-mediated bone resorption.[65,66]

VEGF and MDA-BF-1 play a vital role in differentiation and activation of osteoblast.[67,68] Proliferation of the osteoblast is regulated by BMP,[69] IGF's,[70] TGF-β,[71] uPA,[72] FGF's,[73] and ET-1.[74,75] OPG inhibits osteoclastic activity by binding to RANKL.[76] PDGF-BB promotes angiogenesis [Table 1].[4,77-79]

Biochemical markers

Biomarkers have been used to assess the response to therapy or for the detection of bone metastases. Osteoblastic activity is analyzed through the of levels of bone-specific alkaline phosphatase, osteocalcin, and type I procollagen C-propeptide in serum, whereas osteoclastic activity is identified through serum levels of C-terminal telopeptide of type I collagen and tartrate-resistant acid phosphatase and urinary levels of type I collagen cross-linked N-telopeptides. Urinary type I collagen crosslinked N-telopeptides and C-terminal telopeptide of type I collagen appear to be the most useful.[8]

Imaging in bone metastasis

Bone metastatic tumors primarily consist of four architectural patterns: osteolytic, osteoblastic, osteoporotic, and mixed. Bone metastases are mostly multiple during the time of diagnosis.[7] Eosinophilic granuloma, lymphoma, chronic osteomyelitis, Paget's disease, stress fractures, osteodystrophy, multiple myeloma, and secondary osteoarthritis should be considered as differential diagnosis during the imaging evaluation of jaw bones [Figure 2]. Advanced imaging aids such as radiography, computed tomography (CT), magnetic resonance imaging (MRI), bone scintigraphy, and positron emission tomography play an essential part in the detection, diagnosis, and determination of the extent of the disease, prognosis, treatment planning, and follow-up for monitoring these patients.[7,80-88]

Conclusion

Metastasis of jaw bones is one of the most debilitating problems in patients with malignancies. Prevention or limitation of bone metastasis would considerably improve the quality of lives of patients diagnosed with advanced malignancies. The detailed molecular mechanisms responsible for both osteolytic and osteoblastic metastases are just being unraveled with recent advancements in molecular biology. When bone metastases are diagnosed or suspected, further imaging-guided techniques may be required to confirm, to establish the extent of the disease, and to find the primary tumor. Radiograph, CT, MRI, bone scintigraphy, and PET are considered to be the most accurate imaging modality to date, but they still have limitations such as high cost, lower availability, lack of specificity, and the inability to detect micrometastases. Further improvement of imaging techniques is mandatory to improve their accuracy for the well-being and the quality of life in affected patients.

Financial support and sponsorship

Nil.

Conflicts of interest

There are no conflicts of interest.

References

1. Muttagi SS, Chaturvedi P, D'Cruz A, Kane S, Chaukar D, Pai P, *et al*. Metastatic tumors to the jaw bones: Retrospective analysis from an Indian tertiary referral center. Indian J Cancer 2011;48:234-9.
2. Kumar G, Manjunatha B. Metastatic tumors to the jaws and oral cavity. J Oral Maxillofac Pathol 2013;17:71-5.
3. Hirshberg A, Leibovich P, Buchner A. Metastatic tumors to the jawbones: Analysis of 390 cases. J Oral Pathol Med 1994;23:337-41.
4. Lieberman JR, Daluiski A, Einhorn TA. The role of growth factors in the repair of bone. Biology and clinical applications. J Bone Joint Surg Am 2002;84-A: 1032-44.
5. Virk MS, Jay R, Lieberman JR. Tumour metastasis to bone. Arthritis Res Ther 2007;9:1-10.
6. Bringhurst F, Demay M, Krane S, Kronenberg H. Bone and

[Downloaded free from http://www.jpbsonline.org on Monday, November 27, 2017, IP: 106.203.126.106]

mineral metabolism in health and disease. In: Kasper D, Hauser S, Longo D, Jameson J, Loscaizo J, editors. Harrison's Principles of Internal Medicine. 17th ed. New York: McGraw-Hill; 2008. p. 2365-76.
7. Theriault RL, Theriault RL. Biology of bone metastases. Cancer Control 2012;19:92-101.
8. Roodman GD. Mechanisms of bone metastasis. N Engl J Med 2004;350:1655-64.
9. Aubin JE. Bone stem cells. J Cell Biochem Suppl 1998;30-31:73-82.
10. Yang X, Karsenty G. Transcription factors in bone: Developmental and pathological aspects. Trends Mol Med 2002;8:340-5.
11. Otto F, Thornell AP, Crompton T, Denzel A, Gilmour KC, Rosewell IR, *et al.* Cbfa1, a candidate gene for cleidocranial dysplasia syndrome, is essential for osteoblast differentiation and bone development. Cell 1997;89:765-71.
12. Komori T, Yagi H, Nomura S, Yamaguchi A, Sasaki K, Deguchi K, *et al.* Targeted disruption of Cbfa1 results in a complete lack of bone formation owing to maturational arrest of osteoblasts. Cell 1997;89:755-64.
13. Stein GS, Lian JB. Molecular mechanisms mediating proliferation/differentiation interrelationships during progressive development of the osteoblast phenotype. Endocr Rev 1993;14:424-42.
14. Wozney JM. Overview of bone morphogenetic proteins. Spine (Phila Pa 1976) 2002;27:S2-8.
15. Mundy GR, Chen D, Zhao M, Dallas S, Xu C, Harris S, *et al.* Growth regulatory factors and bone. Rev Endocr Metab Disord 2001;2:105-15.
16. Roodman GD. Cell biology of the osteoclast. Exp Hematol 1999;27:1229-41.
17. Kodama H, Nose M, Niida S, Yamasaki A. Essential role of macrophage colony-stimulating factor in the osteoclast differentiation supported by stromal cells. J Exp Med 1991;173:1291-4.
18. Lacey DL, Timms E, Tan HL, Kelley MJ, Dunstan CR, Burgess T, *et al.* Osteoprotegerin ligand is a cytokine that regulates osteoclast differentiation and activation. Cell 1998;93:165-76.
19. Yasuda H, Shima N, Nakagawa N, Yamaguchi K, Kinosaki M, Mochizuki S, *et al.* Osteoclast differentiation factor is a ligand for osteoprotegerin/osteoclastogenesis-inhibitory factor and is identical to TRANCE/RANKL. Proc Natl Acad Sci U S A 1998;95:3597-602.
20. Hofbauer LC, Heufelder AE. Osteoprotegerin and its cognate ligand: A new paradigm of osteoclastogenesis. Eur J Endocrinol 1998;139:152-4.
21. Tsukii K, Shima N, Mochizuki S, Yamaguchi K, Kinosaki M, Yano K, *et al.* Osteoclast differentiation factor mediates an essential signal for bone resorption induced by 1 alpha, 25-dihydroxyvitamin D3, prostaglandin E2, or parathyroid hormone in the microenvironment of bone. Biochem Biophys Res Commun 1998;246:337-41.
22. Dougall WC, Glaccum M, Charrier K, Rohrbach K, Brasel K, De Smedt T, *et al.* RANK is essential for osteoclast and lymph node development. Genes Dev 1999;13:2412-24.
23. Simonet WS, Lacey DL, Dunstan CR, Kelley M, Chang MS, Lüthy R, *et al.* Osteoprotegerin: A novel secreted protein involved in the regulation of bone density. Cell 1997;89:309-19.
24. Mizuno A, Amizuka N, Irie K, Murakami A, Fujise N, Kanno T, *et al.* Severe osteoporosis in mice lacking osteoclastogenesis inhibitory factor/osteoprotegerin. Biochem Biophys Res Commun 1998;247:610-5.
25. Romas E. Clinical applications of RANK-ligand inhibition. Intern Med J 2009;39:110-6.
26. Feller L, Kramer B, Lemmer J. A short account of metastatic bone disease. Cancer Cell Int 2011;11:24.
27. Geiger TR, Peeper DS. Metastasis mechanisms. Biochim Biophys Acta 2009;1796:293-308.
28. Chambers AF, Groom AC, MacDonald IC. Dissemination and growth of cancer cells in metastatic sites. Nat Rev Cancer 2002;2:563-72.
29. Eccles SA, Welch DR. Metastasis: Recent discoveries and novel treatment strategies. Lancet 2007;369:1742-57.
30. Fidler IJ. The pathogenesis of cancer metastasis: The 'seed and soil' hypothesis revisited. Nat Rev Cancer 2003;3:453-8.
31. Gupta GP, Massagué J. Cancer metastasis: Building a framework. Cell 2006;127:679-95.
32. Kaplan RN, Rafii S, Lyden D. Preparing the "soil": The premetastatic niche. Cancer Res 2006;66:11089-93.
33. Kaplan RN, Riba RD, Zacharoulis S, Bramley AH, Vincent L, Costa C, *et al.* VEGFR1-positive haematopoietic bone marrow progenitors initiate the pre-metastatic niche. Nature 2005;438:820-7.
34. Bussard KM, Gay CV, Mastro AM. The bone microenvironment in metastasis; what is special about bone? Cancer Metastasis Rev 2008;27:41-55.
35. Christofori G. New signals from the invasive front. Nature 2006;441:444-50.
36. Thiery JP. Epithelial-mesenchymal transitions in tumour progression. Nat Rev Cancer 2002;2:442-54.
37. Gregory PA, Bracken CP, Bert AG, Goodall GJ. MicroRNAs as regulators of epithelial-mesenchymal transition. Cell Cycle 2008;7:3112-8.
38. Wu WS, Heinrichs S, Xu D, Garrison SP, Zambetti GP, Adams JM, *et al.* Slug antagonizes p53-mediated apoptosis of hematopoietic progenitors by repressing puma. Cell 2005;123:641-53.
39. Ghosh M, Song X, Mouneimne G, Sidani M, Lawrence DS, Condeelis JS, *et al.* Cofilin promotes actin polymerization and defines the direction of cell motility. Science 2004;304:743-6.
40. Zhu Z, Sanchez-Sweatman O, Huang X, Wiltrout R, Khokha R, Zhao Q, *et al.* Anoikis and metastatic potential of cloudman S91 melanoma cells. Cancer Res 2001;61:1707-16.
41. Liotta LA, Kohn E. Anoikis: Cancer and the homeless cell. Nature 2004;430:973-4.
42. Holash J, Maisonpierre PC, Compton D, Boland P, Alexander CR, Zagzag D, *et al.* Vessel cooption, regression, and growth in tumors mediated by angiopoietins and VEGF. Science 1999;284:1994-8.
43. Hanahan D, Folkman J. Patterns and emerging mechanisms of the angiogenic switch during tumorigenesis. Cell 1996;86:353-64.
44. Egeblad M, Werb Z. New functions for the matrix metalloproteinases in cancer progression. Nat Rev Cancer 2002;2:161-74.
45. Wyckoff J, Wang W, Lin EY, Wang Y, Pixley F, Stanley ER, *et al.* A paracrine loop between tumor cells and macrophages is required for tumor cell migration in mammary tumors. Cancer Res 2004;64:7022-9.
46. Khanna C, Wan X, Bose S, Cassaday R, Olomu O, Mendoza A, *et al.* The membrane-cytoskeleton linker ezrin is necessary for osteosarcoma metastasis. Nat Med 2004;10:182-6.
47. Paget S. The distribution of secondary growths in cancer of the

[Downloaded free from http://www.jpbsonline.org on Monday, November 27, 2017, IP: 106.203.126.106]

breast 1889. Cancer Metastasis Rev 1989;8:98-101.
48. Li F, Tiede B, Massagué J, Kang Y. Beyond tumorigenesis: Cancer stem cells in metastasis. Cell Res 2007;17:3-14.
49. Olumi AF, Grossfeld GD, Hayward SW, Carroll PR, Tlsty TD, Cunha GR, *et al.* Carcinoma-associated fibroblasts direct tumor progression of initiated human prostatic epithelium. Cancer Res 1999;59:5002-11.
50. Orimo A, Gupta PB, Sgroi DC, Arenzana-Seisdedos F, Delaunay T, Naeem R, *et al.* Stromal fibroblasts present in invasive human breast carcinomas promote tumor growth and angiogenesis through elevated SDF-1/CXCL12 secretion. Cell 2005;121:335-48.
51. Chiang AC, Massagué J. Molecular basis of metastasis. N Engl J Med 2008;359:2814-23.
52. Nguyen DX, Bos PD, Massagué J. Metastasis: From dissemination to organ-specific colonization. Nat Rev Cancer 2009;9:274-84.
53. Sun YX, Fang M, Wang J, Cooper CR, Pienta KJ, Taichman RS, *et al.* Expression and activation of alpha v beta 3 integrins by SDF-1/CXC12 increases the aggressiveness of prostate cancer cells. Prostate 2007;67:61-73.
54. Wels J, Kaplan RN, Rafii S, Lyden D. Migratory neighbors and distant invaders: Tumor-associated niche cells. Genes Dev 2008;22:559-74.
55. Wang J, Loberg R, Taichman RS. The pivotal role of CXCL12 (SDF-1)/CXCR4 axis in bone metastasis. Cancer Metastasis Rev 2006;25:573-87.
56. Kang Y, Siegel PM, Shu W, Drobnjak M, Kakonen SM, Cordón-Cardo C, *et al.* A multigenic program mediating breast cancer metastasis to bone. Cancer Cell 2003;3:537-49.
57. Yin JJ, Pollock CB, Kelly K. Mechanisms of cancer metastasis to the bone. Cell Res 2005;15:57-62.
58. Guise TA, Yin JJ, Taylor SD, Kumagai Y, Dallas M, Boyce BF, *et al.* Evidence for a causal role of parathyroid hormone-related protein in the pathogenesis of human breast cancer-mediated osteolysis. J Clin Invest 1996;98:1544-9.
59. Whang PG, Schwarz EM, Gamradt SC, Dougall WC, Lieberman JR. The effects of RANK blockade and osteoclast depletion in a model of pure osteoblastic prostate cancer metastasis in bone. J Orthop Res 2005;23:1475-83.
60. Jimi E, Nakamura I, Duong LT, Ikebe T, Takahashi N, Rodan GA, *et al.* Interleukin 1 induces multinucleation and bone-resorbing activity of osteoclasts in the absence of osteoblasts/stromal cells. Exp Cell Res 1999;247:84-93.
61. Lam J, Takeshita S, Barker JE, Kanagawa O, Ross FP, Teitelbaum SL, *et al.* TNF-alpha induces osteoclastogenesis by direct stimulation of macrophages exposed to permissive levels of RANK ligand. J Clin Invest 2000;106:1481-8.
62. Mancino AT, Klimberg VS, Yamamoto M, Manolagas SC, Abe E. Breast cancer increases osteoclastogenesis by secreting M-CSF and upregulating RANKL in stromal cells. J Surg Res 2001;100:18-24.
63. Itonaga I, Sabokbar A, Sun SG, Kudo O, Danks L, Ferguson D, *et al.* Transforming growth factor-beta induces osteoclast formation in the absence of RANKL. Bone 2004;34:57-64.
64. Peyruchaud O, Serre CM, NicAmhlaoibh R, Fournier P, Clezardin P. Angiostatin inhibits bone metastasis formation in nude mice through a direct anti-osteoclastic activity. J Biol Chem 2003;278:45826-32.
65. Nemeth JA, Yousif R, Herzog M, Che M, Upadhyay J, Shekarriz B, *et al.* Matrix metalloproteinase activity, bone matrix turnover, and tumor cell proliferation in prostate cancer bone metastasis. J Natl Cancer Inst 2002;94:17-25.
66. Gialeli C, Theocharis A D and Karamanos NK. Roles of matrix metalloproteinases in cancer progression and their pharmacological targeting. FEBS Journal 2011;278:16-27.
67. Kitagawa Y, Dai J, Zhang J, Keller JM, Nor J, Yao Z, *et al.* Vascular endothelial growth factor contributes to prostate cancer-mediated osteoblastic activity. Cancer Res 2005;65:10921-9.
68. Vakar-Lopez F, Cheng CJ, Kim J, Shi GG, Troncoso P, Tu SM, *et al.* Up-regulation of MDA-BF-1, a secreted isoform of ErbB3, in metastatic prostate cancer cells and activated osteoblasts in bone marrow. J Pathol 2004;203:688-95.
69. Bentley H, Hamdy FC, Hart KA, Seid JM, Williams JL, Johnstone D, *et al.* Expression of bone morphogenetic proteins in human prostatic adenocarcinoma and benign prostatic hyperplasia. Br J Cancer 1992;66:1159-63.
70. Fizazi K, Yang J, Peleg S, Sikes CR, Kreimann EL, Daliani D, *et al*. Prostate cancer cells-osteoblast interaction shifts expression of growth/survival-related genes in prostate cancer and reduces expression of osteoprotegerin in osteoblasts. Clin Cancer Res 2003;9:2587-97.
71. Matuo Y, Nishi N, Takasuka H, Masuda Y, Nishikawa K, Isaacs JT, *et al.* Production and significance of TGF-beta in AT-3 metastatic cell line established from the Dunning rat prostatic adenocarcinoma. Biochem Biophys Res Commun 1990;166:840-7.
72. Achbarou A, Kaiser S, Tremblay G, Ste-Marie LG, Brodt P, Goltzman D, *et al.* Urokinase overproduction results in increased skeletal metastasis by prostate cancer cells *in vivo*. Cancer Res 1994;54:2372-7.
73. Valta MP, Hentunen T, Qu Q, Valve EM, Harjula A, Seppänen JA, *et al.* Regulation of osteoblast differentiation: A novel function for fibroblast growth factor 8. Endocrinology 2006;147:2171-82.
74. Nelson JB. Endothelin receptor antagonists. World J Urol 2005;23:19-27.
75. Stern PH, Tatrai A, Semler DE, Lee SK, Lakatos P, Strieleman PJ, *et al.* Endothelin receptors, second messengers, and actions in bone. J Nutr 1995;125:2028S-32S.
76. Corey E, Brown LG, Kiefer JA, Quinn JE, Pitts TE, Blair JM, *et al.* Osteoprotegerin in prostate cancer bone metastasis. Cancer Res 2005;65:1710-8.
77. Yi B, Williams PJ, Niewolna M, Wang Y, Yoneda T. Tumor-derived platelet-derived growth factor-BB plays a critical role in osteosclerotic bone metastasis in an animal model of human breast cancer. Cancer Res 2002;62:917-23.
78. Mundy GR. Metastasis to bone: Causes, consequences and therapeutic opportunities. Nat Rev Cancer 2002;2:584-93.
79. Guise TA, Mohammad KS, Clines G, Stebbins EG, Wong DH, Higgins LS, *et al.* Basic mechanisms responsible for osteolytic and osteoblastic bone metastases. Clin Cancer Res 2006;12:6213s-6s.
80. Rybak LD, Rosenthal DI. Radiological imaging for the diagnosis of bone metastases. Q J Nucl Med 2001;45:53-64.
81. Ell PJ. Skeletal imaging in metastatic disease. Curr Opin Radiol 1991;3:791-6.
82. Available from: http://www.emedicine.medscape.com/article/387840-overview#a24. [Last accessed on 2014 Dec 10].
83. Libshitz HI, Hortobagyi GN. Radiographic evaluation of therapeutic response in bony metastases of breast cancer. Skeletal Radiol 1981;7:159-65.
84. Downey SE, Wilson M, Boggis C, Baildam AD, Howell A, Bundred NJ, *et al.* Magnetic resonance imaging of bone metastases: A diagnostic and screening technique. Br J Surg

[Downloaded free from http://www.jpbsonline.org on Monday, November 27, 2017, IP: 106.203.126.106]

1997;84:1093-4.
85. Delbeke D, Martin WH. Positron emission tomography imaging in oncology. Radiol Clin North Am 2001;39:883-917.
86. Merrick MV. Bone scintigraphy – An update. Clin Radiol 1989;40:231-2.
87. Jonsson K, Johnell O. Preoperative angiography in patients with bone metastases. Acta Radiol Diagn (Stockh) 1982;23:485-9.
88. Schweitzer ME, Levine C, Mitchell DG, Gannon FH, Gomella LG. Bull's-eyes and halos: Useful MR discriminators of osseous metastases. Radiology 1993;188:249-52.