www.jiaomr.in Volume 32 | Issue 3 | July-September 2020 ISSN 0972-1363

Journal of Indian Academy of Oral Medicine And Radiology

JIAOMR

Official Publication of Indian Academy of Oral Medicine & Radiology

Dental Council of India
भारतीय दन्त परिषद्
Approved Catagory-I Journal

Wolters Kluwer

Medknow

Review Article

Neurotrophins (NTs) and Neurotrophin Receptors (NTRs) as Emerging Therapeutic Paradigm in Head and Neck Tumors - A Mini Review

Thuckanickenpalayam Ragunathan Yoithapprabhunath, Krubakar RachelSarahVinodhini[1], Shanmugam Mohanapriya[1], Joseph Babu Susai Raj[2], Vasudevan Kalaiselvi[3], Ramadas Madhavan Nirmal[4]

Department of Oral and Maxillofacial Pathology, Vivekanandha Dental College for Women, Tamil Nadu, [1]Consultant Oral and Maxillofacial Pathology, Tamil Nadu, [2]Department of Oral Medicine and Radiology, Vivekanandha Dental College for Women, Tamil Nadu, [3]Department of Oral Medicine and Radiology, Karpaga Vinayaka Institute of Dental Sciences, Tamil Nadu, [4]Department of Oral and Maxillofacial Pathology, Rajah Muthiah Dental College and Hospital, Tamil Nadu, India

Abstract

Cells of the human biological system emerge from various concerted processes of cell growth, differentiation, repair, and regeneration to a degree. Neurotrophins (NTs) and Neurotrophin Receptors (NTRs) have robust effects on proliferation, differentiation, migration, survival, and synapse formation through physiologic regulatory signals. Dysregulation of such neurotrophic factors not only results in various age-related degenerative conditions but also paves the way to oncogenesis in neuronal and non-neuronal tissues. This review aims to highlight the emerging role of neurotrophins (NTs) and Neurotrophin Receptors (NTRs) in Oral Health and Disease and its molecular signaling pathway in physiologic and pathologic conditions. The electronic databases PubMed, MEDLINE, Scopus, and Google Scholar were searched for available data in the present review. A database search yielded more than 100 articles out of which 45 were included based on the core data. The role of NTs and NTRs in dental diseases is less explored and this was the very first attempt to collect the literature data of NTs and NTRs pertaining to head and neck tumors. The results and subsequent conclusions were extracted and reviewed. Expression of NTs and NTRs in neuronal and non-neuronal tissue is a spatial and time-bound event like odontogenesis. Recently NTs and NTRs expressions were detected in a few head and neck tumors. Unraveling the molecular signaling pathway of NTs and NTRs in head and neck tumors will help in elucidating the molecular pathogenesis and the prognosis, therefore, paving a path to expand our knowledge to understand and develop therapies for many pathologic conditions.

Keywords: Ameloblastoma, neurotrophin receptors, neurotrophins, odontogenesis

Introduction

Odontogenesis is a highly complex process involving a puzzling network of interactions and baffling signaling processes between the epithelium and the neural crest-derived ectomesenchyme. Research conducted to understand these complex networks over the past several decades has identified several novel signaling molecules, growth factors, and receptors.[1] Neurotrophins (NTs) and Neurotrophin receptors (NTRs) are one such class of growth factors that are involved in the development of dental structures. With their receptors, these distinctive factors exert their specific effects not only on neuronal cell growth but correspondingly on a wide range of non-neuronal differentiating cells.[2] It has been known that neurotrophins play a role in numerous biological functions such as cell survival, proliferation, regulation, differentiation, apoptosis, and migration. There are also shreds of evidence linking neurotrophin signaling with several pathological and regenerative processes involving the human teeth.[3] This review highlights the general character of

Access this article online

Quick Response Code:

Website: www.jiaomr.in

DOI: 10.4103/jiaomr.jiaomr_125_20

Address for correspondence:
Dr. Thuckanickenpalayam Ragunathan Yoithapprabhunath, Department of Oral and Maxillofacial Pathology, Vivekanandha Dental College for Women, Elayampalayam, Thiruchengodu, Namakkal (Dist) - 637 205, Tamil Nadu, India.
E-mail: yoitha.dentist@gmail.com

This is an open access journal, and articles are distributed under the terms of the Creative Commons Attribution-NonCommercial-ShareAlike 4.0 License, which allows others to remix, tweak, and build upon the work non-commercially, as long as appropriate credit is given and the new creations are licensed under the identical terms.

For reprints contact: reprints@medknow.com

How to cite this article: Yoithapprabhunath TR, RachelSarahVinodhini K, Mohanapriya S, Susai Raj JB, Kalaiselvi V, Nirmal RM. Neurotrophins (NTs) and Neurotrophin Receptors (NTRs) as emerging therapeutic paradigm in head and neck tumors - A mini review. J Indian Acad Oral Med Radiol 2020;32:278-83.

Received: 28-06-2020 **Revised:** 29-07-2020
Accepted: 12-08-2020 **Published:** 29-09-2020

NTs and NTRs, emphasizing their role in dental development and disease.

Neurotrophins and Neurotrophin Receptors

NTs are the target-derived polypeptides involved in regulating neuronal growth, neurogenesis, survival or death, synaptic activity, and function of the nervous system.[4] Neurotrophin functions reach beyond the neuronal tissues to include a wide range of epithelial and mesenchymal cells.[5] These NTs exist as neurotrophin precursors before being cleaved and processed as mature neurotrophins by enzymes like convertases. The processed and mature neurotrophins now have a structure with a cysteine knot which is arranged in a step-like pattern of disulfide bonds.[6]

Nerve Growth Factor (NGF), a 26-kDa homodimer of 13kDA polypeptides which is referred to as βNGF was the first identified NT.[7,8] The discovery of NGF dates back to 1950 by Rita Levi Montalcini and Viktor Hamburger during their work on the development of the nervous system and the peripheral structures it innervates. It was understood that the NGF operates on sympathetic neurons and sensory neurons originating from the neural crest.[4] Two distinguishing features of NGF behavior on neurons that distinguish it from growth factors that are guided to other types of cells are

- Its ability to control the functions of differentiated neurons, and
- The fact that it is synthesized by peripheral tissues or other neurons ('targets') that are contacted by axons of NGF-sensitive neurons that are at a considerable distance from the cell body.[9]

Following the discovery of NGF, three other neurotrophins with structural similarity were discovered, including brain-derived neurotrophic factor (BDNF), neurotrophin 3 (NT3), and neurotrophin 4/5 (NT4/5).[10] BDNF was isolated from the brain of pigs and had an amino acid similarity of 50% to NGF.[2] Neurotrophin NT3 has been cloned from several animals, while NT4 has been cloned from Xenopus laevis. In the discovery of another neurotrophin, there was a discrepancy as to whether the newly discovered neurotrophin was different from NT4 or an NT4 counterpart. Consequently, it was named as NT4 or NT5 and now this factor is being referred to as NT4/5.[11] GDNF (Glial Cell line Derived Neurotrophic Factor) is yet another discovered neurotrophic factor that is distantly related to the TGF (Transforming Growth Factor) superfamily.[12] Neurotrophin 6 and Neurotrophin 7 have been identified as novel members of the neurotrophin family that have no functional significance in human beings.[13,14]

NTs function by acting on their respective cell surface NTRs. The Trk family of tyrosine protein kinases and the p75NTR (p75 neurotrophin receptor), a member of the superfamily tumor necrosis factor, are two distinct classes of neurotrophin receptors.[15] Neurotrophin receptors can be graded as high affinity Trk receptors and low affinity p75NTR based on their binding affinity to NTs.[16] The pro-neurotrophins have high specificity towards p75NTR receptors, while the mature neurotrophins bind with low affinity to p75NTR receptors and high affinity with their respective Trk receptors.[17] Three subclasses of the Trk family, namely TrkA, TrkB, and TrkC, have been described in mammals. NGF binds specifically to Trk A, BDNF, and NT4 bind to TrkB and NT3 binds to TrkC. The p75NTR receptor, on the other hand, can not only bind to all the NTs, but it also can regulate the binding affinity of Trk receptors with their cognate ligands. p75NTRforms complexes with Trk and the resulting interactions can confer ligand selectivity on Trk receptors [Figure 1].[16]

The activation of the two receptor systems can lead to both pro-apoptotic and anti-apoptotic effects, apart from their role on differentiation, survival, and neuronal plasticity. Signal transduction through p75NTR takes place via three different pathways: JNK, NF kappa B, and ceramide.[6] The p75NTR activation triggers pro-apoptotic signaling pathways that facilitate apoptosis. This p75NTR-dependent apoptosis is brought about mainly by the binding of the proneurotrophins. However not all p75NTR expressed cells respond to the pro neurotrophins and result in cell death. It is found that pro-NGF brings about the apoptotic signaling pathway by simultaneously binding to both p75NTR and Sortilin, a member of the Vps10p-domain receptors.[18] The mature neurotrophins, on the other hand, promote survival by selectively activating the Trk receptors.[19]

Neurotrophins and Neurotrophin Receptors in Oral Embryology

NTs have long been known to be involved during neuronal development, function, and organogenesis. Their biological function has been well established in several other cells such as lymphocytes, endocrine cells, mast cells, eosinophils, and ectodermal cells such as keratinocytes and melanocytes.[20] The NTs and NTRs expression have also been studied and documented in the process of odontogenesis.

NGF expression is found during the initiation phase in both the dental epithelium and the underlying mesenchyme. In the bud stage, NGF gets expressed in the inner dental epithelium and

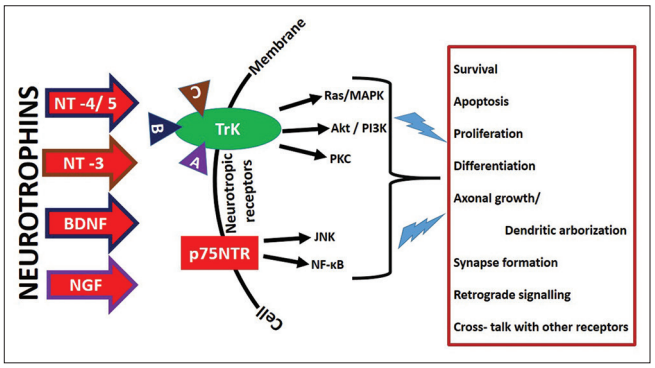

Figure 1: Ligand formation between NT's and NTR's and their molecular signaling pathway and function

the underlying condensed mesenchyme. It is also seen to be expressed in the dental follicles. During the bell stage of tooth development, it gets expressed in the stratum intermedium and postnatal expression gets limited to the cervical part of the enamel organ and the dental papilla.[5,21] Low levels of BDNF expression has been observed in the early dental organ and increased expression has been observed during the late developmental period in the pulp and the odontoblastic layer.[5]

The expression of NT3 is unique in that this neurotrophin is expressed mainly in the cervical loop region, cuspal tips, and fissure system depressions. NT4, on the other hand, is more evenly distributed in the odontogenic epithelium.[5] In the postnatal developmental period, NT4 is expressed in the ameloblasts and has been suggested to play a role in the differentiation and maintenance of ameloblasts.[3] Further studies on NT4 has shown that it also plays a protagonist in the regulation of enamel matrix proteins such as Ameloblastin.[22] The expression of GDNF was mainly seen in the odontogenic epithelium during the early stages of tooth development and later the expression pattern changed being mainly expressed in the odontoblastic layer and the sub-odontoblastic zone.[23]

The expression of p75NTR during tooth development has been detected in the inner enamel epithelium and underlying condensed ectomesenchyme during the transition of bud to the cap stage. During the cap stage, the expression becomes restricted to the inner dental epithelium except for the stratum intermedium, enamel knot, and dental papilla. During the bell stage, they are expressed in the inner enamel epithelial cells and the stratum intermedium while they are not expressed in the pre-ameloblasts and the differentiated ameloblasts.[3]

It has also been observed that the expression of p75NTR is seen along the entire inner enamel epithelium and the dental follicle before the matrix deposition by the ameloblasts. However, their expression was lost from the matrix producing cells and the dental follicle adjacent to these cells after the matrix production was initiated.[24] Another interesting study has shown that these receptors do regulate mineralization during tooth development. The p75NTRexpression positively correlated with certain mineralization-related markers like ALP, Runx2 and Col-1, and their expression gradually increased with the maturation of the developing tooth germ.[25]

The receptor TrkA was seen to be expressed in the mesenchyme surrounding the developing tooth germ during the early cap stage, while their expression became more localized in the dental papilla and the nerve fibers during the late cap stage. In the early bell stage, the expression of these receptors is seen in the inner dental epithelium, pre-ameloblasts, stratum intermedium, and the outer dental epithelium. As the development of the tooth germ progressed to the late bell stage TrkA expression was observed in the pre-ameloblasts and the differentiating ameloblasts cells but the immunoreactivity decreased in the mature ameloblasts. Likewise, the expression of TrkA was seen in the differentiating odontoblasts, and the dental follicle but significantly decreased expression was noted in the secreting odontoblasts.[26]

TrkB expression is seen during the initiation and bud stage in both the dental epithelium and mesenchyme. The expression pattern becomes localized in the cervical loop, dental papilla mesenchyme, and mesenchyme surrounding the outer dental epithelium during the cap and bell stages. It has also been observed that all the transcripts of TrkB were expressed in the dental epithelium while the dental mesenchyme showed the expression of TrkB- T1 alone.[3] TrkC expression was not observed in the developing tooth germs; however, they are seen expressed during the postnatal period in the central parts of dental papilla mesenchyme [Table 1].[21]

Neurotrophins and Neurotrophin Receptors in Dental Regeneration

The role of NTs in the regeneration of dental structures in carious and injured teeth has been documented. NGF, TrkA, and p75NTR is weakly expressed in the dental pulp fibroblasts and the odontoblasts but the expression of NGF and p75NTR was strong in the nerve fibers of the pulp in a normal functional tooth. However, NGF and TrkA have been observed to be selectively increased in the odontoblasts surrounding the injured sites in carious and injured teeth. These observations clearly indicate the possible role of neurotrophins in the regeneration processes of human teeth.[27] A study was conducted in periodontitis patients for the expression of BDNF (neurotrophin family). It was found that BDNF induces periodontal tissue regeneration and bone remodelling by activation of Cementoblast differentiation, endothelial cell migration. This suggests that BDNF has a role in bone remodelling and repair.[28]

Neurotrophins and Salivary Glands

NTs are one of the groups of growth factors secreted by the salivary glands. Studies have shown that the secretion of neurotrophins by the salivary glands correlated with immobilization stress. Under acute immobilization stress conditions, increased levels of BDNF were seen in the mouse submandibular glands further leading to the increased levels of BDNF in plasma.[29]

Neurotrophins and Neurotrophin Receptors in Tumors of Oral and Maxillofacial Region

TrkA was strongly expressed in all histological types of salivary gland ducts, whereas p75NTR expression is mainly confined to the collecting ducts.[30] One of the newly emerged tumors is Mammary analogue secretory carcinoma. The genetic hallmark of this tumor is a translocation between the variant 6 (ETV6) and neurotrophic tyrosine kinase receptor - type 3 (NTRK3) genes. This t (12;15)(p13;q25) translocation resulting in a fusion product that contains the transcriptional regulator ETV6. When ETV6 fused with the membrane receptor kinase NTRK3, activates cell proliferation and survival.[31]

Odontogenic tumors are pathology, which has a different histologic pattern and biological behavior but with similar histologic cells and malformed structures seen during odontogenesis. Ameloblastoma is the second most common odontogenic tumor which is known for its locally aggressive and invasive nature. Novel attempts were made to detect the expression of NTs and NTRs in ameloblastoma. The immunohistochemical expression pattern of p75-NTR in ameloblastoma was analyzed and compared between the follicular and plexiform type of ameloblastoma. Significant expression of p75-NTR in peripheral ameloblast like cells of follicular ameloblastoma was found when compared to plexiform type.[32] In contrast, another study was done to analyse the immunohistochemical expression pattern of TrK (A+B+C) in ameloblastoma. When the expression pattern between the follicular and plexiform type of ameloblastoma was compared, significant expression was detected in peripheral ameloblast like cells of plexiform ameloblastoma was found.[33] The pattern of immunoexpression of NGF was found in both follicular and plexiform ameloblastoma. But the intensity is more in plexiform than that of follicular ameloblastoma.[34] According to literature, binding of NGF with p75-NTR leads to Trk dependent or Trk independent receptor-mediated pathways that result in apoptosis, survival, and proliferation of tumor cells. Though there is a lack in clarity on the oncogenic pathway of ameloblastoma even after decades, the NTs and NTRs induced signaling pathways during physiologic and pathologic condition portrays the similar trails to that of ameloblastoma [Figure 2].[35]

The expression of p75NTR was specifically seen in oral squamous cell carcinoma. This indicates its invasion and poor prognosis. The neurotrophin receptor also is seen in the undifferentiated cell populations of squamous cell carcinoma.[36] In Head and Neck Oral Squamous Cell Carcinoma (HNSCC), Trks expression increased VEGF-C & VEGF-D results in the induction of neovascularization, tumor Progression, and Nodal Metastasis.[37] Expression of TrkB/BDNF activates PI3K/Akt kinase pathway, the Ras pathway, and PLC-γ1 pathway in moderately differentiated and poorly differentiated oral squamous cell carcinoma which determines tumor differentiation, tissue invasion & disease-free survival.[38]

Expression of p75NTR in HNSCC might be related to NGF-independent therapy resistance, while TrkA might transduce a survival signal of NGF and contribute in this way to improved tumor cell survival after cell cycle arrest.[39]

Neuroblastoma is a tumor that develops from immature nerve cells found in several areas of the body. It has a higher tendency to get metastasis in the mandibular jaw. NGF/Trk-A and BDNF/TrkB expression in human neuroblastomas promotes survival and induces neurite outgrowth in an autocrine/paracrine manner and its pathway may be predominantly important for growth and differentiation of neuroblastomas amplification. MYCN-amplified neuroblastoma maintains an aggressive and undifferentiated phenotype by deregulation of estrogen and NGF signaling. TrkA overexpression may overcome aggressiveness, even in tumors exhibiting MYCN oncogene amplification.[40-42] Since these molecules were considered as potential prognostic markers and targets for Neuroblastoma treatment in the post-genomic era.[43]

Neurotrophins and Neurotrophin Receptors in Neuronal/Non-Neuronal Tumors, Neuro-Degenerative Conditions and Metabolic Disorders

The dysregulation of NTs and NTRs have been shown to

Table 1: Expression of Neurotrophins and Neurotrophin Receptors during various stages of Odontogenesis

	Bud Stage	Cap Stage	Early Bell Stage	Late Bell Stage
p75NTR	Nerve fibres approaching tooth germ.[26]	Restricted to the inner dental epithelium except the stratum intermedium, enamel knot and dental papilla.[3,26,27]	Inner dental epithelium and stratum intermedium.[3,26,27]	Absent
TRK A	Both epithelium and dental mesenchyme.[26]	Dental papilla and the nerve fibres of surrounding the tooth germ.[26]	Inner dental epithelium, preameloblasts, stratum intermedium and the outer dental epithelium.[26]	Preameloblasts and the differentiating ameloblasts cells except mature ameloblasts.[26]
TRK B	Both dental epithelium and mesenchyme.[3]	Dental papilla mesenchyme and mesenchyme surrounding the outer dental epithelium.[3]	Cervical loop, dental papilla mesenchyme and mesenchyme surrounding the outer dental epithelium.[3]	Cervical loop, dental papilla mesenchyme and mesenchyme surrounding the outer dental epithelium.[3]
TRK C	Absent[27]	Absent[27]	Absent[27]	Absent[27]
NGF	Around dental epithelium and condensed ectomesenchyme.[5,21]	Absent	Absent	Restricted areas of inner dental epithelium and stratum intermedium.[5,21]
BNDF	Weak expression in dental mesenchyme surrounding the epithelium.[3]	Absent	Absent	Absent
NT 3	Dental epithelium and mesenchyme.[3]	Absent	Restricted to cervical parts of inner dental epithelium.[3]	Absent
NT 4/5	Dental epithelium.[3]	Dental epithelium.[3]	Dental epithelium.[3]	Absent

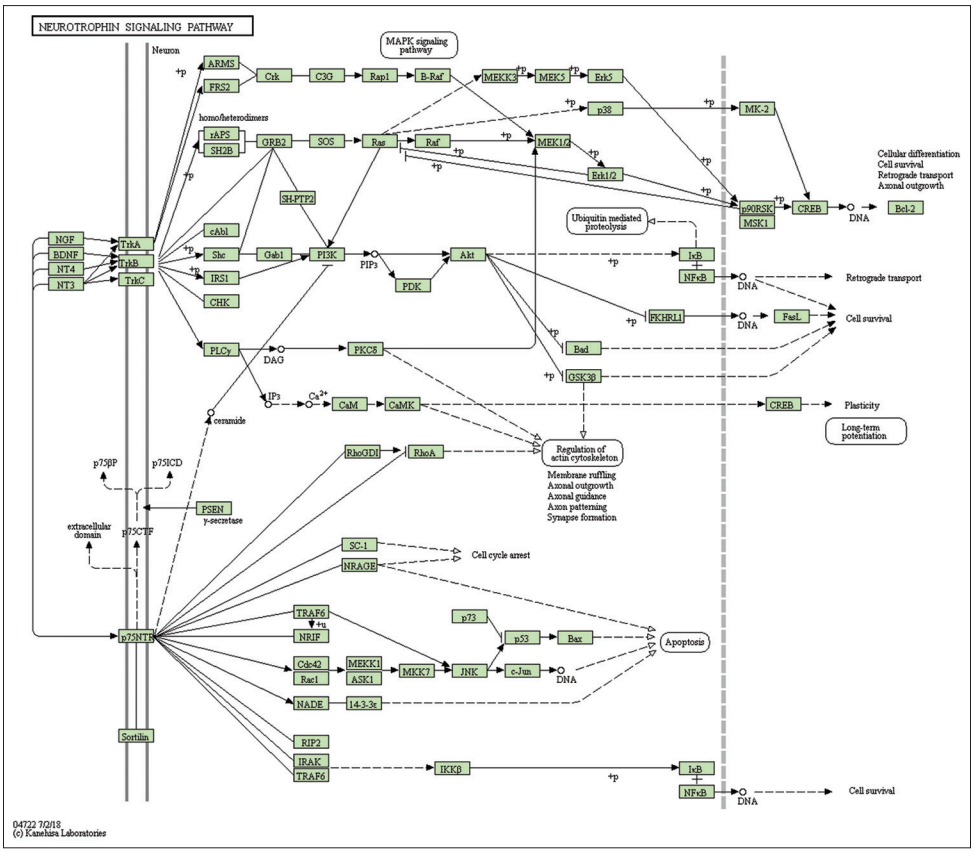

Figure 2: Neurotrophins are a family of trophic factors involved in differentiation and survival of neural cells. The neurotrophin family consists of nerve growth factor (NGF), brain derived neurotrophic factor (BDNF), neurotrophin 3 (NT-3), and neurotrophin 4 (NT-4). Neurotrophins exert their functions through engagement of Trk tyrosine kinase receptors or p75 neurotrophin receptor (p75NTR). Neurotrophin/Trk signaling is regulated by connecting a variety of intracellular signaling cascades, which include MAPK pathway, PI-3 kinase pathway, and PLC pathway, transmitting positive signals like enhanced survival and growth. On the other hand, p75NTR transmits both positive and negative signals. These signals play an important role for neural development and additional higher-order activities such as learning and memory. [Copyright Ref. no -200388, KEGG (Kyoto Encyclopedia of Genes and Genomes) - map04722 Neurotrophin signalling pathway obtained from Kanehisa Laboratories, Japan.]

play a significant role in regulating the biology of neuronal tumors and neural crest-derived tumors like ganglioneuroma, schwannoma, pheochromocytoma, melanoma, glioma, and medulloblastoma. Several nerve growth factors also mutated in cardiovascular diseases. Parkinson's disease, Alzheimer's disease, depression, shows deregulated NTs and NTRs. They also play a vital role in ontogenesis and progression of non-neuronal tumors like prostate cancer, breast cancer, melanoma, and hepatocellular carcinoma. In addition to this, neurotrophins downregulated in metabolic disorders like diabetes, obesity, hyperinsulinemia, hyperleptinaemia, and hyperactivity.[44,45]

Conclusion

NTs and NTRs' role in oncogenesis have remained unexplored in the oral and maxillofacial arena. Further studies on their role in oral diseases, especially on head and neck tumors will pave a way in non-invasive/minimal invasive or therapeutic intervention of such highly destructive tumors.

Financial support and sponsorship

Nil.

Conflicts of interest

There are no conflicts of interest.

References

1. Thesleff I. Current understanding of the process of tooth formation: Transfer from the laboratory to the clinic. Aust Dent J 2014;59(Suppl 1):48-54.
2. Milsiadis TA, Luukko K. Neurotrophins in odontogenesis. Int J Dev Biol 1995;39:195-202.
3. Iwamoto T, Yamada A, Arakaki M, Sugawara Y, Ono M, Futaki M, *et al*. Expressions and functions of neurotrophic factors in tooth development. J Oral Biosci 2011;53:13-21.
4. Kastin AJ. Neurotrophins. Handbook of Biologically Active Peptides. 2nd ed. London, UK: Academic Press Inc; 2013. p. 1639-46.
5. Nosrat CA, Fried K, Lindskog S, Olson L. Cellular expression of neurotrophin mRNAs during tooth development. Cell Tissue Res 1997;290:569-80.
6. Roux PP, Barker PA. Neurotrophin signaling through the p75 neurotrophin receptor. Prog Neurobiol 2002;67:203-33.
7. Skaper SD. Neurotrophic factors: An overview. Methods Mol Biol 2018;1727:1-17.
8. Bothwell MA, Shooter EM. Dissociation equilibrium constant of beta nerve growth factor. J Biol Chem 1977;252:8532-6.
9. Thoenen H. Neurotrophins and neuronal plasticity. Science 1995;270:593-8.
10. Reichardt LF. Neurotrophin-regulated signaling pathways. Philos Trans

R Soc Lond B Biol Sci 2006;361:1545-64.
11. Bothwell M. Functional interactions of neurotrophins and neurotrophin receptors. Annu Rev Neurosci 1995;18:223-53.
12. Lin L, Doherty D, Lile J, Bektesh S, Collins F. GDNF: A glial cell line-derived neurotrophic factor for midbrain dopaminergic neurons. Science 1993;260:1130-2.
13. Götz R, Köster R, Winkler C, Raulf F, Lottspeich F, Schartl M, *et al*. Neurotrophin-6 is a new member of the nerve growth factor family. Nature 1994;372:266-9.
14. Nilsson A, Fainzilber M, Falck P, Ibáñez CF. Neurotrophin-7: A novel member of the neurotrophin family from the zebrafish. FEBS Lett 1998;424:285-90.
15. Chao MV. Neurotrophins and their receptors: A convergence point for many signaling pathways. Nat Rev Neurosci 2003;4:299-309.
16. Chao MV, Rajagopal R, Lee FS. Neurotrophin signaling in health and disease. Clin Sci (Lond) 2006;110:167-73.
17. Segal RA. Selectivity in neurotrophin signaling: Theme and variations. Annu Rev Neurosci 2003;26:299-330.
18. Nykjaer A, Lee R, Teng K, Jansen P, Madsen P, Nielsen M, *et al*. Sortilin is essential for proNGF-induced neuronal cell death. Nature 2004;427:843-8.
19. Chao MV, Bothwell M. Neurotrophins: To cleave or not to cleave. Neuron 2002;33:9-12.
20. Skaper SD. The biology of neurotrophins, signaling pathways, and functional peptide mimetics of neurotrophins and their receptors. CNS Neurol Disord Drug Targets 2008;7:46-62.
21. Luukko K, Moshnyakov M, Sainio K, Saarma M, Sariola H, Thesleff I. Expression of neurotrophin receptors during rat tooth development is developmentally regulated, independent of innervation, and suggests functions in the regulation of morphogenesis and innervation. Dev Dyn 1996;206:87-99.
22. Yoshizaki K, Yamamoto S, Yamada A, Yuasa K, Iwamoto T, Fukumoto E, *et al*. Neurotrophic factor neurotrophin-4 regulates ameloblastin expression via full-length TrkB. J Biol Chem 2007;283:3385-91.
23. Nosrat CA, Fried K, Ebendal T, Olson L. NGF, BDNF, NT3, NT4 and GDNF in tooth development. Eur J Oral Sci 1998;106:94-9.
24. Becktor KB, Hansen BF, Nolting D, Kjaer I. Spatiotemporal expression of NGFR during prenatal human tooth development. Orthod Craniofac Res 2002;5:85-9.
25. Zhao M, Wen X, Li G, Ju Y, Wang Y, Zhou Z, *et al*. The spatiotemporal expression and mineralization regulation of p75 neurotrophin receptors in the early tooth development. Cell Prolif 2019;52:e12523.
26. Mitsiadis TA, Pagella P. Expression of nerve growth factor (NGF), TrkA, and p75NTR in developing human fetal teeth. Front Physiol 2016;7:338.
27. Mitsiadis TA, Magloire H, Pagella P. Nerve growth factor signaling in pathology and regeneration of human teeth. Sci Rep 2017;7:1327.
28. Corrêa JD, Pereira DS, Madeira MFM, Queiroz-Junior CM, Souza DG, Teixeira MM, *et al*. Brain-derived neurotrophic factor in chronic periodontitis. Mediators Inflamm 2014;2014:373765. doi: 10.1155/2014/373765.
29. Saruta J, Sato S, Tsukinoki K. The role of neurotrophins related to stress in saliva and salivary glands. Histol Histopathol 2010;25:1317-30.
30. Schenck K, Schreurs O, Hayashi K, Helgeland K. The Role of Nerve Growth Factor (NGF) and Its Precursor Forms in Oral Wound Healing. Int J Mol Sci 2017;18:386.
31. Yin LX, Ha PK. Genetic alterations in Salivary Gland cancers. Cancer 2016;122:1822-31.
32. Ragunathan YT, Madhavan NR, Mohan SP, Kumar SK. Immunohistochemical Detection of p75 Neurotrophin Receptor (p75-NTR) in Follicular and Plexiform Ameloblastoma. J Clin Diagn Res 2016;10:ZC63-6.
33. Babu JG, Vadivel I, Ragunathan YT, Nalliappan G, Janardhanam D, Ramadas MN. Immunohistochemical detection of tyrosine kinase receptor in follicular and plexiform ameloblastoma – A novel study. J Oral Maxillofac Pathol 2020;24:125-30.
34. Yoithapprabhunath TR, Renugadevi S, Ganapathy N, Dineshshankar J, Yamunadevi A, Nirmal RM. Immunohistochemical detection of nerve growth factor (NGF) in follicular and plexiform ameloblastoma – A novel study. J Pharm Bioall Sci 2020;12:S569-75.
35. Kanehisa M. Toward understanding the origin and evolution of cellular organisms. Protein Sci 2019;28:1947-51.
36. Tong D, Sun J, Huang P, Li M, Zhang F. p75 neurotrophin receptor: A potential surface marker of tongue squamous cell carcinoma stem cells. Mol Med Rep 2017;15:2521-9.
37. Sasahira T, Ueda N, Yamamoto K, Bhawal UK, Kurihara M, Kirita T, *et al*. Trks are novel oncogenes involved in the induction of neovascularization, tumor progression, and nodal metastasis in oral squamous cell carcinoma. Clin Exp Metastasis 2013;30:165-76.
38. Moriwaki K, Ayani Y, Kuwabara H, Terada T, Kawata R, Asahi M. TRKB tyrosine kinase receptor is a potential therapeutic target for poorly differentiated oral squamous cell carcinoma. Oncotarget 2018;9:25225-43.
39. Dudás J, Dietl W, Romani A, Reinold S, Glueckert R, Schrott-Fischer A, *et al*. Nerve growth factor (NGF)-receptor survival axis in head and neck squamous cell carcinoma. Int J Mol Sci 2018;19:1771.
40. Ruggeri P, Cappabianca L, Farina AR, Gneo L, Mackay AR. NGF FLIPs TrkA onto the death TRAIL in neuroblastoma cells. Cell Death Dis 2016;7:e2139.
41. Nakagawara A, Azar CG, Scavarda NJ, Brodeur GM. Expression and function of TRK-B and BDNF in human neuroblastomas. Mol Cell Biol 1994;14:759-67.
42. Dzieran J, Rodriguez Garcia A, Westermark UK, Henley AB, Eyre Sánchez E, Träger C, *et al*. MYCN-amplified neuroblastoma maintains an aggressive and undifferentiated phenotype by deregulation of estrogen and NGF signaling. Proc Natl Acad Sci U S A 2018;115:E1229-38.
43. Esposito MR, Aveic S, Seydel A, Tonini GP. Neuroblastoma treatment in the post-genomic era. J Biomed Sci 2017;24:14.
44. Kruttgen A, Schneider I, Weis J. The dark side of the NGF family: Neurotrophins in neoplasia. Brain Pathol 2006;16:304-10.
45. Marchelek-Myśliwiec M, Dutkiewicz G, Wiśniewska M, Pietrzak-Nowacka M, Ciechanowski K. Brain-derived neurotrophic factor: A new face of metabolic disorders. Ann Clin Biochem 2013;50(Pt 3):189-90.