[Downloaded free from http://www.jomfp.in on Saturday, May 9, 2020, IP: 103.70.191.6]

Original Article

Immunohistochemical detection of Tyrosine Kinase receptor (TrK) in follicular and plexiform ameloblastoma – A novel study

George Babu Jisha[1], Vadivel Ilayaraja[2], Thuckanickenpalayam Ragunathan Yoithapprabhunath[2], Nalliappan Ganapathy[2], Janardhanam Dineshshankar[2], Ramadas Madhavan Nirmal[3]

[1]Consultant Oral and Maxillofacial Pathologist, SM Dental Clinic, Erode, [2]Department of Oral and Maxillofacial Pathology, Vivekanandha Dental College for Women, Namakkal, [3]Department of Oral and Maxillofacial Pathology, Rajah Muthiah Dental College and Hospital, Chidambaram, Tamil Nadu, India

Abstract

Objectives: The objective is to analyze the immunohistochemical expression pattern of tyrosine kinase receptor (TrK) in ameloblastoma and to compare the immunohistochemical expression pattern of TrK among the histological types of ameloblastoma, follicular and plexiform patterns.

Materials and Methods: Forty ameloblastomas (20 follicular and 20 plexiform) were immunostained with anti-human TrK mouse IgG monoclonal antibody, and the pattern of staining is statistically analyzed.

Results: Total 20 (4 follicular and 16 plexiform) out of 40 ameloblastomas showed immunoreactivity to TrK. Only the peripheral preameloblast like tall columnar cells showed reactivity, whereas the stellate reticulum like cells is immunonegative. The staining pattern was membranous in the immunoreactive cells. The Chi-square value for the immunoexpression between follicular and plexiform ameloblastoma was statistically significant with a $P < 0.005$. The results were studied with the downstream pathways from the literature, and a possible mechanism has been proposed.

Conclusion: The expression pattern of TrK is found to be more in plexiform ameloblastoma than follicular ameloblastoma.

Keywords: Ameloblastoma, immunohistochemistry, neurotrophins, odontogenic tumor, tyrosine kinase receptor

Address for correspondence: Dr. Thuckanickenpalayam Ragunathan Yoithapprabhunath, Department of Oral and Maxillofacial Pathology, Vivekanandha Dental College for Women, Elayampalayam, Thiruchengodu, Namakkal - 637 205, Tamil Nadu, India.
E-mail: yoitha.dentist@gmail.com

Submitted: 23-Jul-2019, **Accepted:** 31-Jan-2020, **Published:** 08-May-2020

INTRODUCTION

Ameloblastoma is a benign odontogenic neoplasm of the jaw. It holds a unique position among benign tumors with a high propensity for recurrence and also due to its locally destructive and invasive nature. It is the second common tumor of the jaw following odontoma. The preponderance of this tumor is seen around the third decade of life with equal gender predilection.[1] This tumor has an origin from the prehistoric era, and it is proved through archaeologically obtained skeletons.[2] The common site of occurrence is the mandibular posterior region followed by the maxillary posteriors. Ameloblastoma clinically presents as a slow-growing swelling of the jaw without any associated pain, leading to facial deformity. On radiographic examination, radiolucency is appreciated with thinning of cortices, root resorption of the associated teeth can also be appreciated.[3] The origin of this

Access this article online

Quick Response Code:

Website: www.jomfp.in

DOI: 10.4103/jomfp.JOMFP_220_19

This is an open access journal, and articles are distributed under the terms of the Creative Commons Attribution-NonCommercial-ShareAlike 4.0 License, which allows others to remix, tweak, and build upon the work non-commercially, as long as appropriate credit is given and the new creations are licensed under the identical terms.

For reprints contact: reprints@medknow.com

How to cite this article: Jisha GB, Ilayaraja V, Yoithapprabhunath TR, Ganapathy N, Dineshshankar J, Nirmal RM. Immunohistochemical detection of Tyrosine Kinase receptor (TrK) in follicular and plexiform ameloblastoma – A novel study. J Oral Maxillofac Pathol 2020;24:125-30.

[Downloaded free from http://www.jomfp.in on Saturday, May 9, 2020, IP: 103.70.191.6]

tumor is thought to arise from cells of the dental lamina and resembles structures of the cap/bell stage of the developing tooth, i.e., odontogenic epithelium without ectomesenchyme and with the presence of mature fibrous stroma.[4] The pathogenesis of the ameloblastoma is unclear. The recent genetic theory elucidates the involvement of the BRAF protein mutation associated with mitogen-activated protein kinase pathway (MAPK) activation results in tumorigenesis/progression of ameloblastoma.[5] Microscopically, it resembles an enamel organ of a developing tooth which lacks dental hard tissue formation. Its aggressiveness is owed to the fact that the tumor is similar to enamel organ.[6,7] Ameloblastoma has two types of cells with different proliferative activity and these activities are based on their cytological pattern and histological variant. The peripheral ameloblast-like cells are known for their anti-apoptotic character, while the central stellate reticulum-like cells are known for their proapoptotic activity.[8]

Neurotrophins are proteins with specific role on nonneuronal and neuronal cells. Brain-derived neurotrophic factor (BDNF), nerve growth factor (NGF), neurotrophin-3, and neurotrophin-4 are the four different types of neurotrophins. Low-affinity receptors – p75NTR and high-affinity receptors – tyrosine kinase receptor (TrK) are present in the family of neurotrophins. These neurotrophins bind to their corresponding receptors on the surface of responsive cells to carry out their biological effect. p75NTR binds to all proteins belonging to the family of neurotrophins. The activation of p75NTR induces cell apoptosis and cell survival by activating Jun N-terminal kinase (JNK) pathway and nuclear factor-kappa B-cell (NF-κB) pathway, respectively. The TrK family consists of three genes namely TrKA, TrKB, and TrKC. Trk receptors are activated by the neurotrophins and they mediate various activities. The activation of TrKA is done by NGF, while TrKB is activated by brain-derived neurotrophic factor (BDNF) and NT-4/5, whereas TrKC is activated by NT-3. TrK receptors activation leads to cell differentiation, survival, proliferation, and apoptosis through PI3K/Akt pathway, Ras/MAPK pathway, and phospholipase C gamma 1 (PLC-γ1) pathway.[9,10]

The immunoreactivity of TrKs, p75NTR, and neurotrophins is studied in the various stages of odontogenesis. Varied immunoexpression was evident in preameloblast cells during both presecretory and secretory stages.[11,12] Morphologically, similar cells resembling preameloblast were seen in peripheral layer of the ameloblastoma, but they are functionally immature.[13] This study will evaluate the immunoreactivity of TrK receptor in follicular and plexiform types of ameloblastoma.

MATERIALS AND METHODS

Study samples consist of 40 paraffin-embedded tissue blocks were selected from the archives. The study sample comprises of 20 follicular ameloblastoma and 20 plexiform ameloblastoma. Two serial sections of 4–4.5 microns thickness of the study samples were sectioned. For each specimen, one slide was stained with hematoxylin and eosin to confirm the diagnosis, and another was used for immunohistochemical analysis. In all cases, under the hematoxylin and eosin staining, morphological analysis disclosed the presence of more than one histological pattern of ameloblastoma and the pattern which predominated was considered for final diagnosis. Tissue showing follicular and plexiform histological variants of ameloblastoma alone included for the study. Clinical types of ameloblastoma, other histological variants of ameloblastoma other than follicular and plexiform type and recurrent ameloblastoma were excluded from the study. Immunohistochemical procedure standardization was done using nerve tissue as a positive control. The other sections of study samples were stained immunohistochemically using Rabbit Monoclonal Anti-TrK A + B + C antibody (ab 181560 - Abcam, Inc., USA) primary antibody and treated with secondary antibody tagged with horseradish peroxidase (HRP) polymer (DAKO REAL En Vision, Denmark).

Interpretation of staining

The immunostained slides were observed for positivity under 10×/40× magnifications and recorded with a high-quality photomicrograph. The positive reaction was indicated by brown precipitate in both cytoplasm and nucleus of the peripheral and central cells of ameloblastoma. All areas in each section were examined and analyzed. The intensity which was predominant in these fields were taken into consideration. The staining was scored by evaluating the positive and negative immunoreactivity of each slide. Immunoreactivity was evaluated depending on the staining intensity as negative (−), positive (+), and strongly positive (++) and given scores 0, 1, and 2, respectively.

Statistical analysis

Software used was Statistical package for social science SPSS version 16 (IBM CORP, Chicago, IL, USA). The level of significance ($P < 0.05$) was employed in all statistical comparisons. Quantitative data were recorded as mean ± standard deviation. The expressions of TrK A + B + C between follicular and plexiform type of ameloblastoma were analyzed statistically using Chi-square test.

[Downloaded free from http://www.jomfp.in on Saturday, May 9, 2020, IP: 103.70.191.6]

RESULTS

Among 40 cases of central ameloblastoma, 20 cases were follicular types and 20 cases were plexiform types. Among follicular ameloblastoma, 80% of samples showed negative immunoreactivity [Figure 1] which accounts for about 80% and only 4 samples which is about 20% showed positive immunoreactivity for TrK A + B + C. Among plexiform ameloblastoma 9 samples showed positive immunoreactivity [Figure 2]. Whereas 5 samples showed strongly positive immunoreactivity [Figure 3] and 6 had negative immunoreactivity for TrK A + B + C. Thus, in plexiform ameloblastoma, there was an overall 70% positive immunoreactivity and 30% negative immunoreactivity [Table 1].

The immunoexpression of TrK between the follicular ameloblastoma and plexiform ameloblastoma showed significance with the $P = 0.003$.

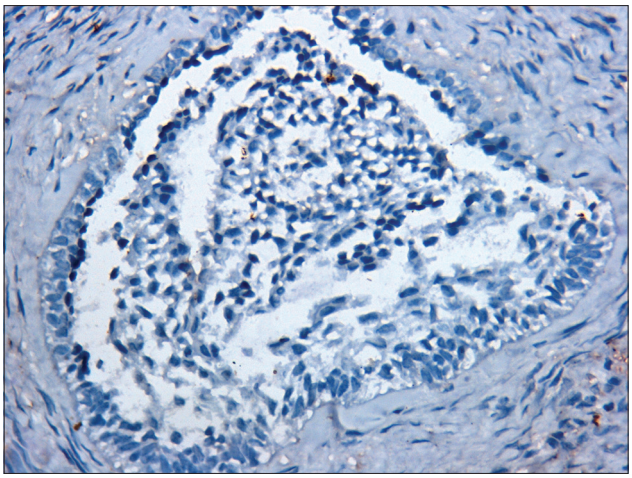

Figure 1: Follicular ameloblastoma showing negative tyrosine kinase receptor immunoexpression in peripheral cells (Photomicrograph, ×40)

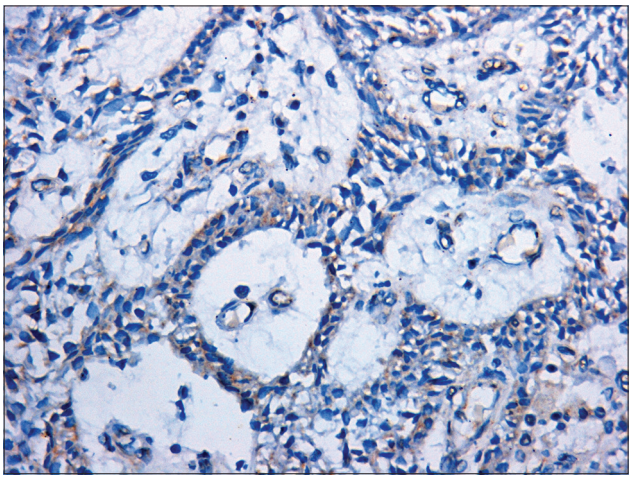

Figure 2: Plexiform ameloblastoma showing mild positive tyrosine kinase receptor immunoexpression in peripheral cells (Photomicrograph, ×40)

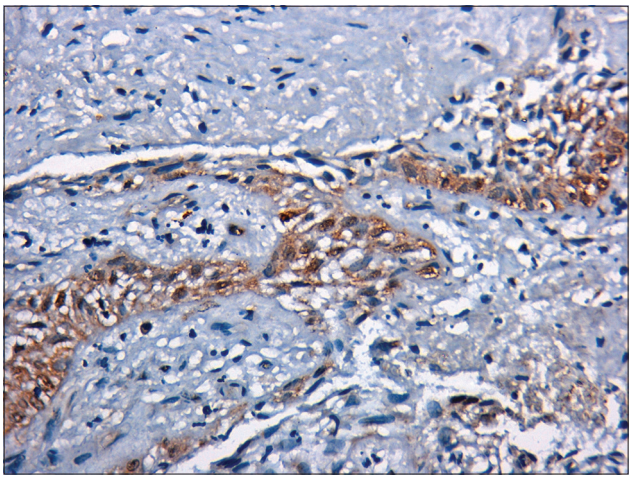

Figure 3: Plexiform ameloblastoma showing intense positive tyrosine kinase receptor immunoexpression in peripheral cells (Photomicrograph, ×40)

DISCUSSION

Robinson described ameloblastoma as a benign tumor that is usually "unicentric, nonfunctional, intermittent in growth, anatomically benign and clinically persistent."[1] In histopathology, ameloblastoma cells show various proliferating activities based on the histological type and cytological pattern. With molecular studies, the implication of both apoptosis and the proliferating activity of the cell were found during the development of ameloblastoma.[8] The peripheral tall columnar cells of ameloblastoma with reversal of polarity which resembles enamel matrix producing ameloblast cells of odontogenesis was found to be functionally immature due to the unexpressed enamel forming proteins.[13] Till date, surgery is regarded as only treatment of choice.[14]

Neurotrophins with it is high- and low-affinity receptors, mediate several pathways which play a role in the survival, differentiation and death, of nonneuronal and neuronal cells.[15-19] Literature reports spatiotemporal immunoexpression of high- and low-affinity neurotrophins receptors, and neurotrophins were detected during odontogenesis.[11,12,20]

Becktor *et al*., in 2002 and Christensen *et al*., in 1993, studied the immunoreactivity of p75-NTR in the developing tooth. They observed a positive immunoreactivity of p75-NTR along the entire inner enamel epithelium and in the dental follicles. With the gradual deposition of matrix and with the differentiation of inner enamel epithelial cells, the immunoreactivity for low-affinity p75-NTR disappeared.[21,22]

[Downloaded free from http://www.jomfp.in on Saturday, May 9, 2020, IP: 103.70.191.6]

Table 1: Comparison of two histological growth pattern of follicular and plexiform ameloblastoma with respect to labeling index of Tyrosin Kinase Receptor by Chi-square test

Groups	Total number of cases	Number of strongly positive cases (%)	Number of positive cases (%)	Number of negative cases (%)	χ^2	*P*
Plexiform ameloblastoma	20	5 (25)	9 (45)	6 (30)	11.469	0.003
Follicular ameloblastoma	20	0	4 (20)	16 (80)		

Ragunathan *et al*., in 2016, observed the expression of low-affinity p75-NTR in ameloblastoma. Two variants of ameloblastoma were observed for immunoreactivity in his study namely follicular and plexiform variants. Positive immunoreactivity was seen in peripheral ameloblast-like cells of both the variants of ameloblastoma. Positivity was seen predominantly in follicular variant of ameloblastoma which constituted about 83.3%. Plexiform variant of ameloblastoma had relatively less positive immunoreactivity of about 10% when compared to the follicular variant.[1]

Mitsiadis and Pagella, in 1995, observed that the immunoreactivity for TrK to be positive in preameloblast cells in early and late bell stages of odontogenesis. Even differentiating ameloblasts had positive immunoreactivity in these stages of tooth development, but the staining intensity got decreased as the maturation of ameloblast was taking place.[12]

In the present study, immunoexpression for TrK A + B + C was restricted only to the cell membrane of cuboidal or columnar type of peripheral cells of the tumor islands and cords. Immunoexpression was positive in peripheral cells of plexiform ameloblastoma cases (70%) comparing to that of follicular ameloblastoma cases (4%). This reveals that there is a significant difference in the expression of TrK A + B + C between follicular ameloblastoma and plexiform ameloblastoma. This was in divergence to the study by Ragunathan *et al*., 2016, on p75NTR in follicular and plexiform ameloblastoma. Significant expression of high-affinity Trk receptor in peripheral ameloblast-like cells of plexiform ameloblastoma was appreciated in the present study, whereas the low-affinity p75NTR expression was significant in the peripheral ameloblast-like cell of follicular ameloblastoma.[1]

Kumamoto and Ooya, in 2007, have evaluated the immunoreactivity for pAkt and PI3K in his study using 18 cases of plexiform ameloblastoma and 22 cases of follicular ameloblastoma. This study result showed that there was a strong immunoreactivity in peripheral ameloblast-like cells and weak reactivity in central stellate reticulum like cells, which was similar to the expression in our study. The level of immunoreactivity to PI3K was significantly higher in plexiform ameloblastoma than in follicular ameloblastoma. The increased expression of pAkt and PI3K suggest its role in tumorigenesis by activating the Akt signaling cascade.[23]

Binding of neurotrophins with their kindred TrK receptors activates Ras/MAPK pathway, phosphatidylinositol-3 kinase (PI3K)/Akt pathway, and PLC-g pathway which promotes cell survival, proliferation, differentiation, and apoptosis.[24-26]

NGF/TrKA overexpression has been reported with oral squamous cell carcinoma, adenoid cystic carcinoma, ovarian carcinomas, pancreatic cancer, and breast carcinomas which results in tumor cell proliferation, survival, migration, progression, enhanced anoikis, resistance, perineural invasion, poor patient outcome, and metastasis. BDNF/TrKB ligand overexpression was found in different cancers including neuroblastoma and cancers of nonneuronal origin such as head and neck, lung, breast, stomach, and colon cancers. Both NGF/TrKA and BDNF/TrKB expression in mentioned tumors promotes angiogenesis by inducing the expression of proangiogenic factors such as vascular endothelial growth factor (VEGF) and transforming growth factor-beta (TGF-β).[27]

From these literatures, the cell survival property of ameloblastoma is predominantly contributed by the ameloblast like cells present at the periphery. These cells have anti-apoptotic property and proliferative capacity. Molecular pathways in ameloblastoma growth and survival have been studied in recent years. The contributing role of TrK receptor in this entity is still not known. TrK receptor can mediate various intracellular signaling cascade through the PI3K/Akt kinase pathway, the Ras pathway, and PLC-γ1 pathway. The association between p75NTR and TrK and its downstream molecules in ameloblastoma was not made through previous studies. This limits the present study in finding out the complete detail of TrK role in follicular and plexiform ameloblastoma.

Further researches are needed to evaluate the role of individual TrK receptors namely TrKA, TrKB, and TrKC and its ligand formations with the NTs on the variants of ameloblastoma to analyze the reason behind the differed biological behavior among them and to account a detailed signaling cascade in this tumor.

[Downloaded free from http://www.jomfp.in on Saturday, May 9, 2020, IP: 103.70.191.6]

CONCLUSION

The positive expression of TrK in ameloblastoma helps in the elucidation of the possible intracellular signal regulation mechanism in this tumor survival and proliferation. Thus, TrK could play a possible role of an activator in this tumor initiation, patternization, proliferation, and tumor progression. The varied expression of TrK could be the possible reason behind the differed biological behavior between follicular and plexiform ameloblastoma. Further studies focusing on the possible pathway connecting TrK and other prognostic molecular markers of ameloblastoma will unravel the ground-breaking function play by it.

By obtaining clear knowledge on altered molecular signaling pathways in this neoplasia will definitely elucidate mechanisms of tumorigenesis, tumor differentiation, and tumor progression which may bring us to nonsurgical approach for ameloblastoma treatment in near future. Further scientific researches and evidence are needed for the thorough knowledge about the relationship of TrK and the ameloblastoma tumor progression and proliferation. Further researches are needed to evaluate the role of individual TrK receptors namely TrKA, TrKB and TrKC on the variants of ameloblastoma to analyze the reason behind the differed biological behavior among them and to account a detailed signaling cascade in this tumor. Using the keywords: TrK, ameloblastoma (follicular and plexiform) in Google and PubMed search, no study was available that showed the immunohistochemical analysis of TrK in ameloblastoma tumors. To the best of our knowledge, this was the very first study made to analyze the immunoexpression and to find the possible role of TrK in ameloblastoma.

Acknowledgment

The authors are grateful to Dr. Sekar Balakrishnan, M. D. S., Professor and Head, Department of Oral and Maxillofacial Pathology, Vinayaka Missions Sankarachariyar Dental College and Hospital, and Dr. Jayakumar Dinakar, M. D. S., Professor and Head, Department of Oral and Maxillofacial Pathology, Ramakrishna Dental College and Hospital, for helping out in conducting this study.

Financial support and sponsorship

Nil.

Conflicts of interest

There are no conflicts of interest.

REFERENCES

1. Ragunathan YT, Madhavan NR, Mohan SP, Kumar SK. Immunohistochemical detection of p75 neurotrophin receptor (p75-NTR) in follicular and plexiform ameloblastoma. J Clin Diagn Res 2016;10:ZC63-6.
2. Yoithapprabhunath TR, Nirmal RM, Ganapathy N, Mohanapriya S, Renugadevi S, Aravindhan R, *et al*. Meta-terminology of ameloblastoma. J Pharm Bioallied Sci 2019;11:S140-5.
3. McClary AC, West RB, McClary AC, Pollack JR, Fischbein NJ, Holsinger CF, *et al*. Ameloblastoma: A clinical review and trends in management. Eur Arch Otorhinolaryngol 2016;273:1649-61.
4. Brown NA, Betz BL. Ameloblastoma: A review of recent molecular pathogenetic discoveries. Biomark Cancer 2015;7:19-24.
5. Wright JM, Soluk Tekkesin M. Odontogenic tumors: Where are we in 2017? J Istanb Univ Fac Dent 2017;51:S10-30.
6. Liu H, Yan X, Pandya M, Luan X, Diekwisch TG. Daughters of the enamel organ: Development, fate, and function of the stratum intermedium, stellate reticulum, and outer enamel epithelium. Stem Cells Dev 2016;25:1580-90.
7. Masthan KM, Anitha N, Krupaa J, Manikkam S. Ameloblastoma. J Pharm Bioallied Sci 2015;7:S167-70.
8. Sandra F, Nakamura N, Mitsuyasu T, Shiratsuchi Y, Ohishi M. Two relatively distinct patterns of ameloblastoma: An anti-apoptotic proliferating site in the outer layer (periphery) and a pro-apoptotic differentiating site in the inner layer (centre). Histopathology 2001;39:93-8.
9. Chao MV, Rajagopal R, Lee FS. Neurotrophin signalling in health and disease. Clin Sci (Lond) 2006;110:167-73.
10. Skaper SD. The biology of neurotrophins, signalling pathways, and functional peptide mimetics of neurotrophins and their receptors. CNS Neurol Disord Drug Targets 2008;7:46-62.
11. Mitsiadis TA, Luukko K. Neurotrophins in odontogenesis. Int J Dev Biol 1995;39:195-202.
12. Mitsiadis TA, Pagella P. Expression of nerve growth factor (NGF), TrkA, and p75(NTR) in developing human fetal teeth. Front Physiol 2016;7:338.
13. Saku T, Okabe H, Shimokawa H. Immunohistochemical demonstration of enamel proteins in odontogenic tumors. J Oral Pathol Med 1992;21:113-9.
14. Sauk JJ, Nikitakis NG, Scheper MA. Are we on the brink of nonsurgical treatment for ameloblastoma? Oral Surg Oral Med Oral Pathol Oral Radiol Endod 2010;110:68-78.
15. Kaplan DR, Miller FD. Neurotrophin signal transduction in the nervous system. Curr Opin Neurobiol 2000;10:381-91.
16. Rabizadeh S, Bredesen DE. Ten years on: Mediation of cell death by the common neurotrophin receptor p75(NTR). Cytokine Growth Factor Rev 2003;14:225-39.
17. Barbacid M. The trk family of neurotrophin receptors. J Neurobiol 1994;25:1386-403.
18. Barbacid M. Structural and functional properties of the TRK family of neurotrophin receptors. Ann N Y Acad Sci 1995;766:442-58.
19. Patapoutian A, Reichardt LF. Trk receptors: Mediators of neurotrophin action. Curr Opin Neurobiol 2001;11:272-80.
20. Nosrat CA, Fried K, Ebendal T, Olson L. NGF, BDNF, NT3, NT4 and GDNF in tooth development. Eur J Oral Sci. 1998;106 Suppl 1:94–99.
21. Becktor KB, Hansen BF, Nolting D, Kjaer I. Spatiotemporal expression of NGFR during pre-natal human tooth development. Orthod Craniofac Res 2002;5:85-9.
22. Christensen LR, Møllgård K, Kjaer I, Janas MS. Immunocytochemical demonstration of nerve growth factor receptor (NGF-R) in developing human fetal teeth. Anat Embryol (Berl) 1993;188:247-55.
23. Kumamoto H, Ooya K. Immunohistochemical detection of

[Downloaded free from http://www.jomfp.in on Saturday, May 9, 2020, IP: 103.70.191.6]

phosphorylated Akt, PI3K, and PTEN in ameloblastic tumors. Oral Dis 2007;13:461-7.
24. Reichardt LF. Neurotrophin-regulated signalling pathways. Philos Trans R Soc Lond B Biol Sci 2006;361:1545-64.
25. Tan F, Thiele CJ, Li Z. Neurotrophin signaling in cancer. Kostrzewa RM, editor. Handbook of Neurotoxicity New York: Springer; 2014. p. 1825-47.
26. Griffin N, Faulkner S, Jobling P, Hondermarck H. Targeting neurotrophin signaling in cancer: The renaissance. Pharmacol Res 2018;135:12-7.
27. Chopin V, Lagadec C, Toillon RA, Le Bourhis X. Neurotrophin signaling in cancer stem cells. Cell Mol Life Sci 2016;73:1859-70.