[Downloaded free from http://www.jpbsonline.org on Sunday, August 30, 2020, IP: 157.50.48.58]

Original Article

Immunohistochemical Detection of Nerve Growth Factor (NGF) in Follicular and Plexiform Ameloblastoma – A Novel Study

Thuckanickenpalayam Ragunathan Yoithapprabhunath[1], Seeni Renugadevi[1], Nalliappan Ganapathy[1], Janardhanam Dineshshankar[1], Andamuthu Yamunadevi[1], Ramadas Madhavan Nirmal[2]

[1]Department of Oral and Maxillofacial Pathology, Vivekanandha Dental College for Women, Thiruchengodu, Tamil Nadu, India, [2]Department of Oral and Maxillofacial Pathology, Rajah Muthiah Dental College and Hospital, Chidambaram, Tamil Nadu, India

Abstract

Background: Ameloblastoma is the second most common odontogenic tumor that holds a unique position among benign tumors due to its locally destructive and invasive nature. The differed tumor biology behind follicular and plexiform ameloblastoma is always an enigma. Nerve growth factor (NGF), a neurotrophin that plays a major role during odontogenesis, could also possibly play a role in the pathogenesis of odontogenic tumors such as ameloblastoma. With this background, the study was aimed to investigate the expression of NGF in follicular and plexiform ameloblastoma. **Objectives:** The objectives of this study were to analyze the immunohistochemical expression pattern of NGF in ameloblastoma and to compare the immunohistochemical expression pattern of NGF among the follicular and plexiform histological types of ameloblastoma. **Materials and Methods:** Forty histological sections of ameloblastomas (20 follicular and 20 plexiform) were stained immunohistochemically with anti-human NGF mouse IgG monoclonal antibody and the staining was analyzed statistically. **Results:** Almost all the 40 ameloblastoma samples (20 follicular and 20 plexiform) showed positive immunoreactivity to NGF. Both peripheral pre-ameloblast-like tall columnar cells and central stellate-reticulum-like cells showed positive reactivity. The pattern of staining was membranous in the immunoreactive cells. The χ^2 value for the immunoexpression between follicular and plexiform ameloblastoma was statistically significant with a *P* value <0.002. A possible mechanism has been proposed after studying the results with the downstream pathways obtained from literature. **Conclusion:** The pattern of expression of NGF is seen in both follicular and plexiform ameloblastoma. But the intensity is more in plexiform than that of follicular ameloblastoma.

Keywords: *Ameloblastoma, immunohistochemistry, nerve growth factor, neurotrophin receptor, neurotrophins, odontogenic tumor*

Received : 17-02-2020.
Accepted : 06-03-2020.
Published : 28-08-2020.

Introduction

Ameloblastoma has been known as one of the rare oral epithelial odontogenic tumors of benign nature, resulting from the cellular components of the enamel organ. Being the second most common odontogenic tumor, ameloblastoma presents as an extensive clinical entity with histological diversity and accounts for about 1%–2% of all maxillary and mandibular cysts and tumors. This tumor affects individuals belonging to the fourth decade of life. Clinically, ameloblastoma presents variably like an asymptomatic mandibular displacement owing to their

Access this article online

Quick Response Code:

Website: www.jpbsonline.org

DOI: 10.4103/jpbs.JPBS_185_20

Address for correspondence: Dr. Yoithapprabhunath Thuckanickenpalayam Ragunathan, Department of Oral and Maxillofacial Pathology, Vivekanandha Dental College for Women, Elayampalayam, Thiruchengodu, Namakkal (Dist) 637205, Tamil Nadu, India.
E-mail: yoitha.dentist@gmail.com

This is an open access journal, and articles are distributed under the terms of the Creative Commons Attribution-NonCommercial-ShareAlike 4.0 License, which allows others to remix, tweak, and build upon the work non-commercially, as long as appropriate credit is given and the new creations are licensed under the identical terms.

For reprints contact: reprints@medknow.com

How to cite this article: Yoithapprabhunath TR, Renugadevi S, Ganapathy N, Dineshshankar J, Yamunadevi A, Nirmal RM. Immunohistochemical detection of nerve growth factor (NGF) in follicular and plexiform ameloblastoma – A novel study. J Pharm Bioall Sci 2020;12:S569-75.

[Downloaded free from http://www.jpbsonline.org on Sunday, August 30, 2020, IP: 157.50.48.58]

slow growth. Pain and paresthesia are rare presentations and in general the dental apparatus associated with these tumors can either be impacted or displaced.[1]

Ameloblastoma was described by Robinson as a benign tumor that is usually "unicentric, non-functional, intermittent in growth, anatomically benign and clinically persistent."[2] The following are the several histopathological subtypes—follicular, plexiform, acanthomatous, desmoplastic, granular cell, and basal cell pattern that may occur singly or in combination of two or more types. The most commonly encountered are the follicular and plexiform variants accounting for 32.5% and 28.2.%, respectively, which is followed by the acanthomatous subtype 12.1%, whereas the extremely uncommon desmoplastic variant has incidence rates ranging from 4% to 13%. However, the following, acanthomatous, granular cell, basal cell, and desmoplastic, variants have been considered as the subsets of follicular ameloblastoma.

Ameloblastoma has been defined by World Health Organization (1992) as a polymorphic neoplasm consisting of proliferating odontogenic epithelium, usually occurring in two main patterns. In the follicular type of pattern, the tumor consists of enamel-organ-like islands or follicles of epithelial cells, whereas in the plexiform type the epithelium forms continuous anastomosing strands. Commonly, both types of the epithelial tumor components are embedded in a mature, connective tissue stroma. Other variants of ameloblastoma such as acanthomatous, granular cell, desmoplastic, basal cell, clear cell, keratoameloblastoma, hemangiomatous, and papilliferous keratoameloblastoma were also described.[3] Hence, follicular and plexiform types are the major histological variants of ameloblastoma.

This tumor is thought to arise from odontogenic epithelium without ectomesenchyme and with presence of mature fibrous connective tissue stroma. Histologically, the tumor resembles an enamel organ of a developing tooth, which lacks dental hard-tissue formation. The aggressiveness of the tumor is attributed to the fact that the tumor is similar to enamel organ. The proliferating activities of ameloblastoma cells vary and depend on factors such as histological type and cytological pattern. The key feature regarding this tumor is that both features such as apoptosis and proliferative activity of the cells have been implicated in ameloblastoma development.[4] Ameloblastoma, irrespective of its clinical and histological variants, has two relatively distinct patterns: peripheral ameloblast-like cells showing antiapoptotic proliferating pattern and central stellate-reticulum-like cells showing proapoptotic activity and differentiation.[5]

The oncogenic transformation of odontogenic epithelium to ameloblastoma is mediated by molecular and genetic factors that is known to be strongly linked to multiple gene dysregulation associated with *mitogen-activated protein kinase*, *sonic hedgehog*, and *WNT/beta-catenin* signaling pathways.[6]

Neurotrophic factors, which are soluble growth factors, are predominantly expressed in vertebrate nervous systems and have been well characterized for playing a vital role in neural tissues. Studies have revealed that neurotrophin factors and their receptors are also expressed in numerous nonneural tissues that play a potential role in major biological functions, such as regulation of cellular proliferation, survival, migration, and differentiation. The family of neurotrophic factors are defined by their similarities in structure and function to four ligands, namely *nerve growth factor (NGF)*, *brain-derived neurotrophic factor (BDNF)*, *neurotrophin-3 (NT-3)*, and *neurotrophin-4* (*NT-4*, also known as *NT-5*). They activate two different receptors, *TrK* (*tyrosine kinase*) and *p75NTR*, the latter of which is a member of the tumor necrosis factor receptor superfamily.[7]

NGF being a trophic factor promotes the survival of sensory and sympathetic neurons both *in vitro* and *in vivo*. The hypoplasia of the corresponding sensory and sympathetic ganglia has been associated with the denervation of the peripheral organs leading to diminished *NGF* secretion from the periphery. The presence of such a vital factor for neuronal survival, however, was recognized earlier. The actual discovery of *NGF* by Rita Levi-Montalcini around the middle of the twentieth century was made possible in *in vitro* bioassays. A pronounced neurite outgrowth from chicken embryo neuronal tissue was observed when it was placed next to mouse sarcoma tissue pieces. These pioneering experiments indirectly established the fact that not only peripheral tissues, but also neoplastic tissues are rich sources of *NGF*.[8]

NGF and its receptors (*TrK A* and *p75NTR*) influence the activity of the peripheral and central nervous system by playing a potential role in the following processes of proliferation, differentiation, and survival. The expression of *NGF* and its receptors has been demonstrated by various experimental studies in primitive neural crest-derived cells as well as in other tumor cell lines derived from neuroblastoma, lymphoma, glioma, medulloblastoma, adrenal tumors, and melanoma.[9]

[Downloaded free from http://www.jpbsonline.org on Sunday, August 30, 2020, IP: 157.50.48.58]

The binding of neurotrophins with *TrK* and *p75NTR* was studied in odontogenesis. A positive immunoreaction for *NGF* was observed in cells such as ameloblasts, stratum intermedium, odontoblasts, and cells of the sub-odontoblastic layer.[10] Similar kind of cells with functional immaturity (ameloblast-like cells) were seen in ameloblastoma. These cells have a major role to play in the process of proliferation and survival of tumor. Around the clock, researchers were working to find the minimal or nonsurgical treatment for tumors. This study was aimed to evaluate the immunoreactivity of *NGF* in follicular and plexiform types of ameloblastoma and the possible role played by *NGF* in the biological behavior, and to an extent could unravel the complexity of molecular pathogenesis of ameloblastoma.

Materials and Methods

Study samples consisting of 40 paraffin-embedded formalin-fixed tissue blocks obtained from the archives of the department comprised 20 follicular and 20 plexiform types of ameloblastoma. Two serial sections of 3–4.5 µm thickness of the study samples were sectioned. One section was stained using hematoxylin and eosin stain; this helped in confirming the histological pattern of ameloblastoma. The other sections of study samples were stained immunohistochemically using *anti-NGF* (sc-365944; Santa Cruz Biotechnologies, Dallas, TX). Immunohistochemical procedure standardization was performed using nerve tissue as positive control.

Interpretation of staining

The immunohistochemically stained slides were observed for positive immunoreaction under 10×/40× magnifications and recorded with a high-quality photomicrograph. The positive reaction was indicated by brown precipitate in both cytoplasm and nucleus of the peripheral and central cells of ameloblastoma. Immunohistochemical reactivity was evaluated according to Nunia *et al.*[11] depending on the staining intensity as mild positivity (+), moderate positivity (++), and strong positivity (+++).

Statistical analysis

Software used was Statistical Package for Social Science (SPSS), version 16.0 (IBM Corp, Chicago, IL). The level of significance ($P < 0.05$) was employed in all statistical comparisons. Quantitative data were recorded as mean ± standard deviation. The expressions of *NGF* between follicular and plexiform type of ameloblastoma were analyzed statistically. An unpaired *t* test was used to compare the staining intensity between follicular and plexiform ameloblastoma. A χ^2 test was employed to determine the magnitude of expression between follicular and plexiform ameloblastoma.

Institutional ethical committee

The study details have been presented in Institutional ethical committee (IEC) and clearance certificate was obtained (IEC no.: VDCW/IEC/79/2017).

Results

Of the 40 samples taken for study, all the samples (100%) showed positivity for *NGF* antibody. An overall assessment of all the 40 (100%) samples showed 17 (42.5%) with mild immunoreactivity, 13 (32.5%) with moderate immunoreactivity, and 10 (25%) with strong immunoreactivity [Table 1]. Among the 20 follicular samples taken for the study, 14 (35%) samples showed mild positivity [Figure 1], 4 (10%) samples showed moderate positivity [Figure 2], and 2 (5%) samples showed strong positivity [Figure 3] for the *NGF* antibody. And among the 20 plexiform samples, 3 (7.5%) samples showed mild positivity [Figure 4], 9 (22.5%) samples showed moderate positivity [Figure 5], and 8 (20%) samples showed strong positivity [Figure 6]. The tall columnar cells in the periphery and the stellate-reticulum-like cells in the center showed cytoplasmic positivity both in follicular and plexiform ameloblastoma. Among the 20 (100%) follicular ameloblastoma samples, 14 (70%) showed mild positivity, 4 (20%) showed moderate positivity, and 2 (10%) showed strong positivity, whereas among the 20 (100%) plexiform ameloblastoma samples, 3 (15%) showed mild positivity, 9 (45%) showed moderate

Table 1: Comparison of magnitude of expression of NGF between follicular and plexiform ameloblastoma

Type of ameloblastoma	Magnitude of expression*			Total
	+	++	+++	
Follicular*	14 (35%)	4 (10%)	2 (5%)	20 (50%)
Plexiform*	3 (7.5%)	9 (22.5%)	8 (20%)	20 (50%)
Total	17 (42.5%)	13 (32.5%)	10 (25%)	40 (100%)

χ^2 value = 12.64, degrees of freedom = 2

*χ^2 test

[Downloaded free from http://www.jpbsonline.org on Sunday, August 30, 2020, IP: 157.50.48.58]

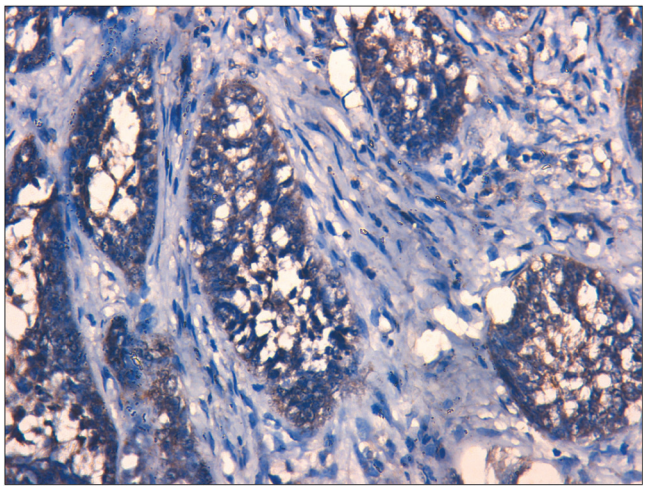

Figure 1: Photomicrograph of follicular ameloblastoma—mild (+) positivity (40×)

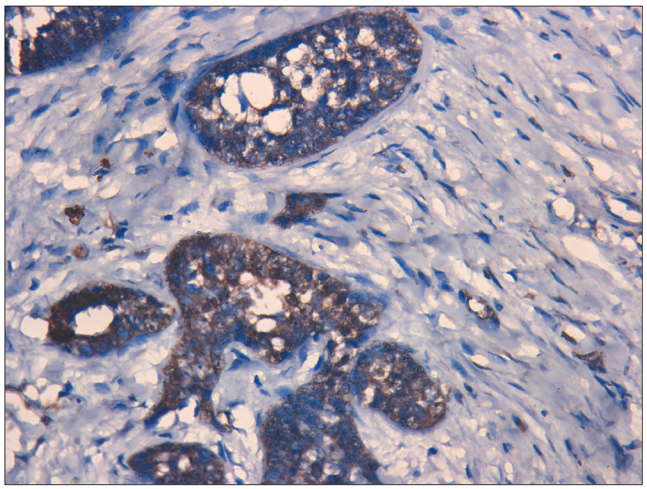

Figure 2: Photomicrograph of follicular ameloblastoma—moderate (++) positivity (40×)

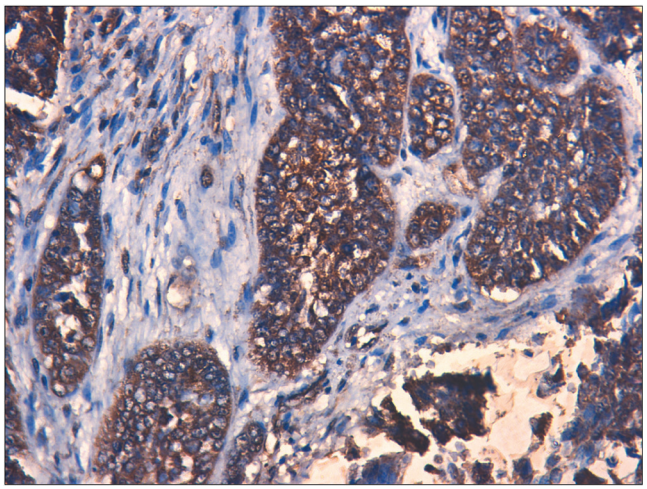

Figure 3: Photomicrograph of follicular ameloblastoma—strong (+++) positivity (40×)

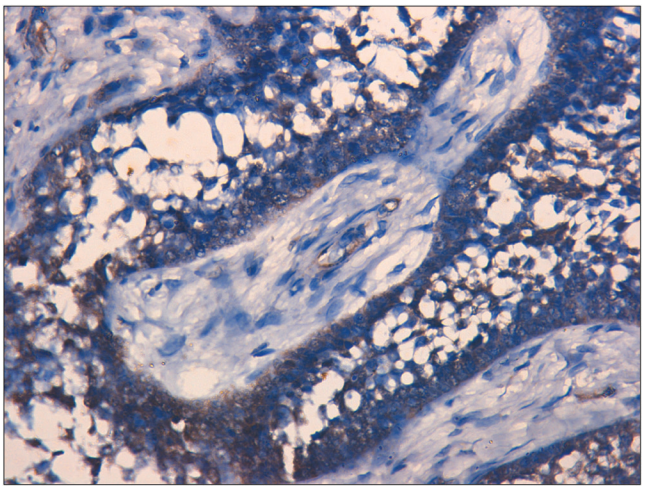

Figure 4: Photomicrograph of plexiform ameloblastoma—mild (+) positivity (40×)

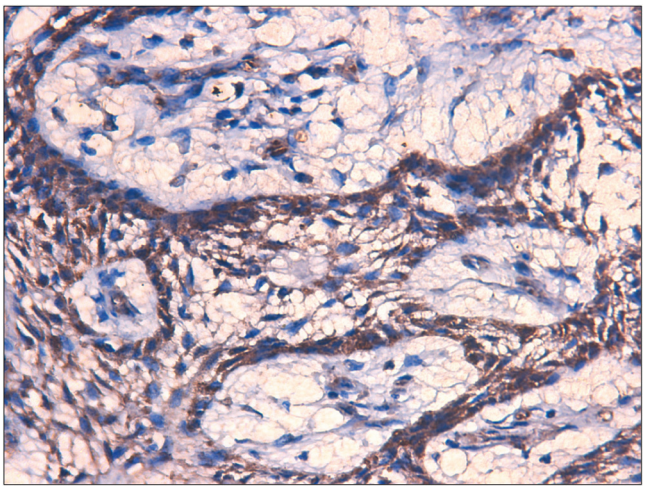

Figure 5: Photomicrograph of plexiform ameloblastoma—moderate (++) positivity (40×)

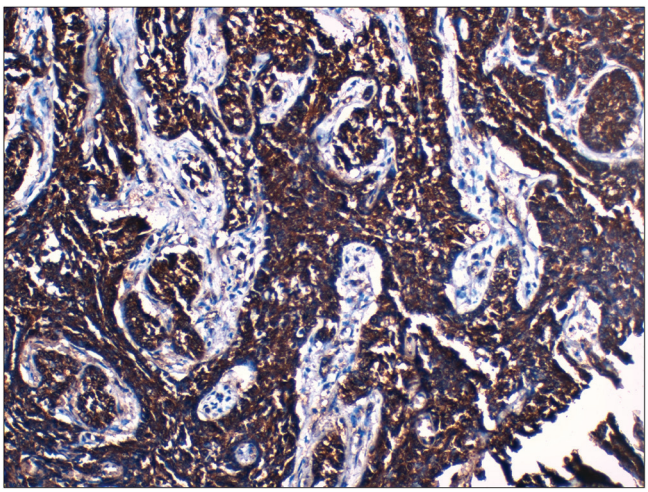

Figure 6: Photomicrograph of plexiform ameloblastoma—strong (+++) positivity (40×)

[Downloaded free from http://www.jpbsonline.org on Sunday, August 30, 2020, IP: 157.50.48.58]

positivity, and 8 (40%) showed strong positivity, respectively.

The immunoexpression of *NGF* between the follicular ameloblastoma and plexiform ameloblastoma showed significance with the *P* value of 0.002 [Table 2].

Discussion

Ameloblastoma has been known as one of the rare oral epithelial odontogenic tumors of benign nature, resulting from the cellular components of the enamel organ. Being the second most common odontogenic tumor, ameloblastoma presents as an extensive clinical entity with histological diversity and accounts for approximately 1%–2% of all maxillary and mandibular cysts and tumors. This tumor affects individuals belonging to the fourth decade of life. Clinically, ameloblastoma presents variably like an asymptomatic mandibular displacement owing to their slow growth. Pain and paresthesia are rare presentations, and in general, the dental apparatus associated with these tumors can either be impacted or displaced.[1]

Ameloblastoma is known to have two relatively distinct patterns of cells, namely the peripheral proliferating antiapoptotic cells and central differentiating proapoptotic cells. Luo *et al.*[12] studied the positive immunoexpression of B cell lymphoma 2 (Bcl-2) in follicular and plexiform ameloblastoma, and positive immunoreactivity was seen in the ameloblast-like cells situated in the peripheral areas of follicular and plexiform ameloblastoma. Follicular variant was found to have an increased immunoreactivity when compared to plexiform type.[12,13]

Neurotrophins are soluble growth factors, known to be predominantly expressed in vertebrate nervous systems and have been well characterized for playing vital role in neural tissues. The neurotrophins that have been isolated so far are NGF, BDNF, NT-3, and NT-4 (also known as NT-5). Neurotrophins, on binding with its high (TrKA) and low (p75NTR) affinity receptors, mediate several physiological pathways, which plays key role in the survival, differentiation, and death of neuronal and nonneuronal cells.[14] They also play an important role in tumor initiation, promotion, and progression of prostate cancer, breast cancer, melanoma, and hepatocellular carcinoma. In oral and maxillofacial region, their expression was found in oral squamous cell carcinoma.[15] In addition to this, neurotrophins were downregulated in metabolic disorders such as diabetes, obesity, hyperinsulinemia, hyperleptinemia, and hyperactivity.[16]

Mitsiadis and Pagella[17] found that NGF expression was seen in the epithelium during the early tooth development stages, followed by p75NTR and TrKA, which are first expressed in the mesenchyme. NGF, p75NTR, and TrKA expression have been observed in the dental follicle, which gives rise to the future periodontium of developing human tooth germs. NGF and TrKA are seen distributed in the proliferating cells of the inner dental epithelium, as well as in the cells such as pre-ameloblasts and the enamel-secreting ameloblasts at the later stages of tooth formation. It has been suggested that in both mesenchymal and epithelial components of the developing human teeth, NGF is known to play a regulatory role.[17] Similar kind of functionally immature ameloblast-like cells were found in the periphery of the tumor component in ameloblastoma.

In this study, a total of 40 (20 follicular and 20 plexiform) samples of ameloblastoma were included. Among the follicular variant (20 samples, 100%), 14 (70%) samples showed mild positivity, 4 (20%) samples showed moderate positivity, and 2 (10%) showed strong positivity for NGF antibody. Similarly, among the plexiform variant (20 samples, 100%), 3 (15%) showed mild positivity, 9 (45%) showed moderate positivity, and 8 (40%) showed strong positivity.

Guttridge *et al.*[18] stated that transcriptional factor nuclear factor κ-light-chain-enhancer of activated B cells (NF-κB) controls apoptosis by expression of inducible target genes and mediates cell growth. NF-κB controls important functions such as pRb hyperphosphorylation and activation of cyclin D1 expression to promote G1-S progression in cell cycle.[18] Hendarmin *et al.*,[19] in their study, have observed the immunoexpression of anti-p65 NF-κB with varying immunoreactivity in both the peripheral and central cells of ameloblastoma. It was elucidated that follicular variant had stronger immunoexpression of p65 NF-κB in the peripheral cells than the central stellate reticulum-like cells.[19] Kumar *et al.*[20] have reported the diffuse expression of cyclin D1 in both peripheral basal cells, supporting its role in proliferation and in central

Table 2: Comparison of expression of NGF between follicular and plexiform types of ameloblastoma

Type	*N*	Mean	SD	*t* value	*df*	*P* value
Follicular*	20	2.45	1.66	3.35	38	0.002*
Plexiform*	20	4.65	2.41			

*$P < 0.05$ – statistically significant

[Downloaded free from http://www.jpbsonline.org on Sunday, August 30, 2020, IP: 157.50.48.58]

stellate reticulum-like cells, suggesting its role in the differentiation.

In tumor development and progression, NGF binding with NTRs (TrKs and p75NTR) activates NF-κB via the subsequent activation of phosphatidylinositol 3-kinase (PI3K) and protein kinase B (PKB or Akt), leading to cell survival. The constitutively active Akt stimulates IKK activity by phosphorylation, which then subsequently phosphorylates IκB protein, inducing an enhanced activation of the NF-κB transcription factor, leading to the process of cell survival.[9] A strong pAkt and PI3K expression was seen in the peripheral columnar or cuboidal cells and a weak expression in the central polyhedral cells.[21] In this study, a positive immunoreactivity for anti-NGF was found in both peripheral ameloblast-like cells and stellate reticulum-like cells of plexiform and follicular ameloblastomas.

TrK activates rat sarcoma (Ras), which in turn initiates the mitogen-activated protein kinase (MAPK) pathway. The activated Ras leads to the activation of a phosphorylation cascade, where rapidly accelerated fibrosarcoma (Raf), MAPK kinase (MEK), and extracellular receptor kinase (ERK) are subsequently phosphorylated, resulting in ERK translocation to the nucleus where it can activate a number of transcription factors. The MAPK signaling pathway acts as a potent mediator of various processes like cell proliferation, differentiation, migration, and survival in ameloblastoma. The binding of NGF to TrKA mediates the MAPK signaling pathway, leading to cell survival and cell differentiation. MAPK mutations were reported in ameloblastoma, suggesting a possible role in the ameloblastoma pathogenesis. It was found that plexiform ameloblastoma showed slightly stronger expression of Ras/MAPK signaling molecules than follicular ameloblastoma.[22-24]

Ragunathan *et al.*[25] studied the pattern of expression of low affinity p75NTR in ameloblastoma. Follicular and plexiform variants of ameloblastoma were analyzed for the immunoreactivity. Positive immunoreactivity was observed in the peripheral ameloblast-like cells of both the variants of ameloblastoma. It was also found that the positivity was comparatively higher in follicular variant of ameloblastoma, which constituted approximately 83.3%. Plexiform variant of ameloblastoma had relatively less positive immunoexpression of approximately 10% when compared to the follicular variant.[25] Jisha *et al.*[26] studied the pattern of expression of high affinity neurotrophin receptor, TrK A+B+C in ameloblastoma. It was also found that the immunopositivity was comparatively higher in plexiform ameloblastoma, which constituted approximately 70%, than follicular ameloblastoma, which relatively had 20% positive immunopositivity. Immunopositivity was observed only in the peripheral ameloblast-like cells of both the variants of ameloblastoma.[26] In this study, positive immunoreactivity to anti-NGF was observed in the peripheral ameloblast-like cells of all the cases. Strong positivity (+++) was observed in 40% plexiform ameloblastoma when compared to that of follicular ameloblastoma (10%).

Literature indicated that NTRs (TrKs and p75NTR) support the processes such as cellular differentiation, growth, migration, and also plays an important role in the regulation of NFκB signal transduction. Binding of NGF with p75NTR-dependent or p75NTR-independent TrK receptor-mediated pathways, results in various cellular activities such as apoptosis, survival, differentiation, growth, and migration of many neuroectoderm derived cells and also plays a vital role in the deregulation of PI3K/Akt-induced NF-κB or BRAF intermediated Ras/MAPK signal transduction pathways.[4,27]

So far, immunohistochemical expression and possible role of p75NTR and TrK (A+B+C) in follicular and plexiform ameloblastoma has been established with the literature. The potential role of NGF in ameloblastoma pathogenesis has not been studied before. In this study, immunoreactivity of NGF and its possible molecular mechanism has been studied by reviewing the literature. NGF along with its neurotrophin receptors (p75NTR and TrKs) is known to play a key role in the cell proliferation and differentiation, which determines the differed biological behavior between follicular and plexiform ameloblastoma. But the molecular signaling mechanism behind stellate reticulum-like cells taking up anti-NGF immunoexpression was not understood.

Conclusion

The positive expression of NGF, along with NTRs, deregulates Akt/PI3K and MAPK pathways through cyclin D1, NF-κB, Ras, and BRAF. Expression of NGF could be one of the many possible reasons behind the differing biological behavior between follicular and plexiform ameloblastoma. Further research and evidence are needed for thorough knowledge about the relationship of neurotrophins and their role in tumor biology of ameloblastoma. Obtaining a clear knowledge on the altered molecular signaling pathways will help in elucidating the tumor biology of ameloblastoma, which may lead us to nonsurgical treatment approach in near future. Future research works are needed to detect, identify, and analyze the individual TrKs (TrKA, TrKB, TrKC) along with other

[Downloaded free from http://www.jpbsonline.org on Sunday, August 30, 2020, IP: 157.50.48.58]

neurotrophins (such as BDNF, NT-3, and NT-4/5) and their downstream signaling pathways in ameloblastoma to analyze the reason behind the differed biological behavior among them and to account a detailed signaling cascade of this tumor. Using the key words: NGF, ameloblastoma (follicular, plexiform) in Google, Scopus, and PubMed search, it was found that no study was available that showed the immunohistochemical analysis of NGF in ameloblastoma. To the best of our knowledge, this was the very first study made to analyze the immunoexpression and to find the possible role of NGF in ameloblastoma.

Acknowledgement

We are grateful to Prof. Dr. B. Sekar, MDS, Head, and Dr. K. Indra Priyadarshini, MDS, Reader, Department of Oral and Maxillofacial Pathology, Vinayaka Missions Sankarachariyar Dental College and Hospital, Tamil Nadu, India, for helping us in conducting this study.

Financial support and sponsorship

Nil.

Conflicts of interest

There are no conflicts of interest.

References

1. Masthan KM, Anitha N, Krupaa J, Manikkam S. Ameloblastoma. J Pharm Bioallied Sci 2015;7:S167-70.
2. Yoithapprabhunath TR, Nirmal RM, Ganapathy N, Mohanapriya S, Renugadevi S, Aravindhan R, *et al*. Meta-terminology of ameloblastoma. J Pharm Bioall Sci 2019;11:S140-5.
3. Reichart PA, Philipsen HP, Sonner S. Ameloblastoma: biological profile of 3677 cases. Eur J Cancer B Oral Oncol 1995;31B:86-99.
4. Jhamb T, Kramer JM. Molecular concepts in the pathogenesis of ameloblastoma: implications for therapeutics. Exp Mol Pathol 2014;97:345-53.
5. Sandra F, Nakamura N, Mitsuyasu T. Two relatively distinct patterns of ameloblastoma: an anti-apoptotic proliferating site in the outer layer (periphery) and a pro-apoptotic differentiating site in the inner layer (centre). Histopathol 2001;39:93-8.
6. Effiom OA, Ogundana OM, Akinshipo AO, Akintoye SO. Ameloblastoma: current etiopathological concepts and management. Oral Dis 2018;24:307-16.
7. Iwamoto T, Yamada A, Arakaki M, Sugawara Y, Ono M, Futaki M, *et al*. Expressions and functions of neurotrophic factors in tooth development. J Oral Biosci 2011;53:13-21.
8. Demir IE, Tieftrunk E, Schorn S, Friess H, Ceyhan GO. Nerve growth factor & TrkA as novel therapeutic targets in cancer. Biochim Biophys Acta 2016;1866:37-50.
9. Aloe L, Rocco ML, Balzamino BO, Micera A. Nerve growth factor: role in growth, differentiation and controlling cancer cell development. J Exp Clin Cancer Res 2016;35:116.
10. Mitsiadis TA, Luukko K. Neurotrophins in odontogenesis. Int J Dev Biol 1995;39:195-202.
11. Nunia K, Urs AB, Kumar P. Interplay between MMP-9 and TIMP-2 regulates ameloblastoma behavior and tooth morphogenesis. Appl Immunohistochem Mol Morphol 2016;24:364-72.
12. Luo HY, Yu SF, Li TJ. Differential expression of apoptosis-related proteins in various cellular components of ameloblastomas. Int J Oral Maxillofac Surg 2006;35:750-5.
13. Gomes CC, Duarte AP, Diniz MG, Gomez RS. Review article: current concepts of ameloblastoma pathogenesis. J Oral Pathol Med 2010;39:585-91.
14. Chao MV. Neurotrophins and their receptors: a convergence point for many signaling pathways. Nat Rev Neurosci 2003;4:299-309.
15. Moriwaki K, Ayani Y, Kuwabara H, Terada T, Kawata R, Asahi M. TRKB tyrosine kinase receptor is a potential therapeutic target for poorly differentiated oral squamous cell carcinoma. Oncotarget 2018;9:25225-43.
16. Marchelek-Myśliwiec M, Dutkiewicz G, Wiśniewska M, Pietrzak-Nowacka M, Ciechanowski K. Brain-derived neurotrophic factor: a new face of metabolic disorders. Ann Clin Biochem 2013;50:189-90.
17. Mitsiadis TA, Pagella P. Expression of nerve growth factor (NGF), TrkA, and p75NTR in developing human fetal teeth. Front Physiol 2016;7:338.
18. Guttridge DC, Albanese C, Reuther JY, Pestell RG, Baldwin AS Jr. NF-kappaB controls cell growth and differentiation through transcriptional regulation of cyclin D1. Mol Cell Biol 1999;19:5785-99.
19. Hendarmin L, Kawano S, Yoshiga D. An anti-apoptotic role of NF-κB in TNFα induced apoptosis in an ameloblastoma cell line. Oral Sci Inter 2008;5:96-103.
20. Kumar H, Vandana R, Kumar G. Immunohistochemical expression of cyclin D1 in ameloblastomas and adenomatoid odontogenic tumours. J Oral Maxillofac Pathol 2011;15:283-7.
21. Kumamoto H, Ooya K. Immunohistochemical detection of phosphorylated Akt, PI3K, and PTEN in ameloblastic tumours. Oral Dis 2007;13:461-7.
22. Kumamoto H, Takahashi N, Ooya K. K-Ras gene status and expression of Ras/mitogen-activated protein kinase (MAPK) signaling molecules in ameloblastomas. J Oral Pathol Med 2004;33:360-7.
23. You Z, Liu SP, Du J, Wu YH, Zhang SZ. Advancements in MAPK signaling pathways and MAPK-targeted therapies for ameloblastoma: a review. J Oral Pathol Med 2019;48:201-5.
24. Brown NA, Betz BL. Ameloblastoma: a review of recent molecular pathogenetic discoveries. Biomark Cancer 2015;7:19-24.
25. Ragunathan YT, Madhavan NR, Mohan SP, Kumar SK. Immunohistochemical detection of p75 neurotrophin receptor (p75-NTR) in follicular and plexiform ameloblastoma. J Clin Diagn Res 2016;10:ZC63-6.
26. Jisha GB, Ilayaraja V, Yoithapprabhunath TR, Ganapathy N, Dineshshankar J, Nirmal RM. Immunohistochemical detection of Tyrosine Kinase receptor (TrK) in follicular and plexiform ameloblastoma – A novel study. J Oral Maxillofac Pathol 2020;24:125-30.
27. Li N, Sui J, Liu H, Zhong M, Zhang M, Wang Y, *et al*. Expression of phosphorylated Akt/mTOR and clinical significance in human ameloblastoma. Int J Clin Exp Med 2015;8:5236-44.