[Downloaded free from http://www.jomfp.in on Wednesday, January 20, 2021, IP: 157.49.192.193]

Original Article

Immunohistochemical analysis of Nuclear Factor-kappa B (NF-κB) between follicular and plexiform ameloblastomas: A pilot study

Muniapillai Sivakumar[1], Thuckanaickenpalayam Ragunathan Yoithapprabhunath[2], Ramadas Madhavan Nirmal[3], Veeran Veeravarmal[3], Janardhanam Dineshshankar[2], Ramamoorthy Amsaveni[3]

[1]Department of Oral and Maxillofacial Pathology, Madha Dental College and Hospital, Chennai, [2]Department of Oral and Maxillofacial Pathology, Vivekanandha Dental College for Women, Namakkal, [3]Department of Oral and Maxillofacial Pathology, Rajah Muthiah Dental College and Hospital, Chidambaram, Tamil Nadu, India

Abstract

Background: Ameloblastoma among benign tumors holds a unique position by its locally destructive and invasive nature. Tumors that originate from the odontogenic apparatus or its remnants in the jaws show diverse clinical presentations, behavior and histologic patterns. The differed biological behavior behind follicular and plexiform ameloblastomas has never attained completeness because of the lack of rhythmic correlation regarding the exact mechanism. Nuclear factor-kappa B (NF-κB) pathways play a crucial role in survival, death and differentiation during physiologic and pathologic conditions. With this background, the study has been aimed to investigate the expression of NF-κB in follicular and plexiform ameloblastomas.

Objective: The objective of this study was to analyze the immunohistochemical expression pattern of NF-κB in ameloblastoma and to compare the immunohistochemical expression pattern of NF-κB among the histological types of ameloblastoma, follicular and plexiform patterns.

Methodology: Total 20 ameloblastomas (10 follicular, 10 plexiform) were immunostained with antihuman NF-κB p65 mouse IgG monoclonal antibody, and the pattern of staining is statistically analyzed using Chi-square test with the level of significance ($P < 0.05$).

Results: Twelve (3 follicular, 9 plexiform) out of 20 ameloblastomas showed immunoreactivity to NF-κB p65. In ameloblastoma, only the peripheral preameloblast-like tall columnar cells showed reactivity, whereas the stellate reticulum-like cells are immunonegative. The staining pattern was membranous in the immunoreactive cells. The results were studied with the associated and inducing pathways from the literature, and a possible mechanism has been proposed.

Conclusion: The expression pattern of NF-κB was found to be higher in plexiform ameloblastoma than follicular ameloblastoma.

Keywords: Ameloblastoma, nuclear factor-kappa B, odontogenic tumors

Address for correspondence: Dr. Thuckanaickenpalayam Ragunathan Yoithapprabhunath, Department of Oral and Maxillofacial Pathology, Vivekanandha Dental College for Women, Elayampalayam, Thiruchengodu, Namakkal - 637 205, Tamil Nadu, India.
E-mail: yoitha.dentist@gmail.com

Submitted: 12-Apr-2020, **Revised:** 13-Aug-2020, **Accepted:** 04-Sep-2020, **Published:** 09-Jan-2021

Access this article online

Quick Response Code:

Website: www.jomfp.in

DOI: 10.4103/jomfp.JOMFP_150_20

This is an open access journal, and articles are distributed under the terms of the Creative Commons Attribution-NonCommercial-ShareAlike 4.0 License, which allows others to remix, tweak, and build upon the work non-commercially, as long as appropriate credit is given and the new creations are licensed under the identical terms.

For reprints contact: WKHLRPMedknow_reprints@wolterskluwer.com

How to cite this article: Sivakumar M, Yoithapprabhunath TR, Nirmal RM, Veeravarmal V, Dineshshankar J, Amsaveni R. Immunohistochemical analysis of Nuclear Factor-kappa B (NF-κB) between follicular and plexiform ameloblastomas: A pilot study. J Oral Maxillofac Pathol 2020;24:466-71.

[Downloaded free from http://www.jomfp.in on Wednesday, January 20, 2021, IP: 157.49.192.193]

INTRODUCTION

Ameloblastoma is an aggressive benign epithelial odontogenic tumor; therefore, it is found exclusively within the maxillofacial skeleton or overlying tooth-bearing areas or alveolar mucosa in the edentulous areas. Despite being a benign tumor, it is locally aggressive and has a high recurrence rate. If left untreated, they often lead to extensive tissue destruction and deformity.[1,2] This tumor was found even from the prehistoric era through the archaeologically obtained human skeletons.[3] In recent years, ameloblastoma has undergone constant modifications in terminology and classification with the introduction of prospective views based on updates on current genetic studies.[4] The proliferating activities of ameloblastoma cells vary depending on the histological type and cytological pattern. The key feature regarding this tumor is that both apoptosis and the proliferating activity of the cell are implicated in the development of ameloblastoma. The biology of tumors demonstrates relatively two distinct patterns: (1) anti-apoptotic proliferating site in the outer layer (periphery) and (2) proapoptotic differentiating site in the inner layer (center) of the tumor component. The peripheral cells of the tumor which has chosen the cell survival mode are considered as the reason behind the progression of the disease leading to expansile jaw lesion. Survivin, bcl-2 and bcl-X were observed more predominantly in the outer layer cells of ameloblastoma, but pro-apoptotic molecules such as Fas, FasL and caspase-3 are expressed in central stellate reticulum-like cells.[5,6] Both clinical and histological subtypes of ameloblastoma have different biological behaviors depending on the growth pattern.[7]

Nuclear factor-kappa B (NF-κB) was first discovered as a transcription factor in B-cells that binds to the 11-base pair sequence enhancer element controlling immunoglobulin kappa light chain expression.[8] It is involved in numerous signaling events [Figure 1], and it is very difficult to see a physiologic or pathologic occasion without its contribution.[9]

The transcription factor NF-κB plays a vital role in regulating various mechanisms through control over the expression of various genes which are involved in immune response, oncogenesis, differentiation, proliferation, apoptosis and angiogenesis.[10] The role of NF-κB has been studied in many tumors such as colitis-associated cancer,[11] hepatocellular carcinoma,[12] oral squamous cell carcinoma[13] and in many lymphoid malignancies[14] and shown to have an association in tumorigenesis.[15]

Previous studies have been conducted to explore the expression pattern and anti-apoptotic role of NF-κB in ameloblastoma.[16] However, there are no studies that have attempted to find the expression of NF-κB among follicular and plexiform ameloblastomas. With this background, the immunohistochemical study is aimed to analyze the immunohistochemical expression pattern NF-κB in ameloblastoma and to compare the immunohistochemical expression pattern of NF-κB among follicular and plexiform types of ameloblastoma.

METHODOLOGY

Study samples consisting of 20 paraffin-embedded formalin-fixed tissue blocks obtained from the archives of the department comprised 10 follicular and 10 plexiform types of ameloblastoma. All the samples selected for the study were from archives. The study details have been presented in the institutional ethics committee (IEC), and ethical clearance certificate was obtained (IEC no. VDCW/IEC/148/2018).

All the 20 cases were subjected to immunohistochemistry to evaluate the expression of NF-κB. The prepared sections were covered completely with optimally diluted mouse monoclonal anti NF-κB p65 (sc-8008, Santa Cruz Biotechnology, USA) in 1:50 dilutions in phosphate buffered saline for 1½ hours. Then, the sections were then washed and treated with secondary antibody tagged with poly horseradish peroxidase enzyme (Dako REAL EnVision, Denmark) for 30 min. The slides were then treated with freshly prepared 3,3' diaminobenzidine tetrahydrochloride solution for 5 min following which it was washed and treated with Mayer's hematoxylin, dehydrated in graded alcohol (50%, 70%, 90% and 100%), cleared with xylene and mounted using dibutyl phthalate xylene, a nonaqueous permanent mounting medium.

Interpretation of staining

The immunostained slides were observed for positivity under ×10/×40 magnifications and recorded with a high-quality photomicrograph. The positive reaction was indicated by brown precipitate in both cytoplasm and nucleus of the peripheral and central cells of ameloblastoma. All areas in each section were examined and analyzed, the intensity which was predominant in these fields was taken into consideration. The staining was scored by evaluating the positive and negative immunoreactivity of each slide. The scores for positive immunoreactivity were given as 2 and for negative immunoreactivity as 1.

[Downloaded free from http://www.jomfp.in on Wednesday, January 20, 2021, IP: 157.49.192.193]

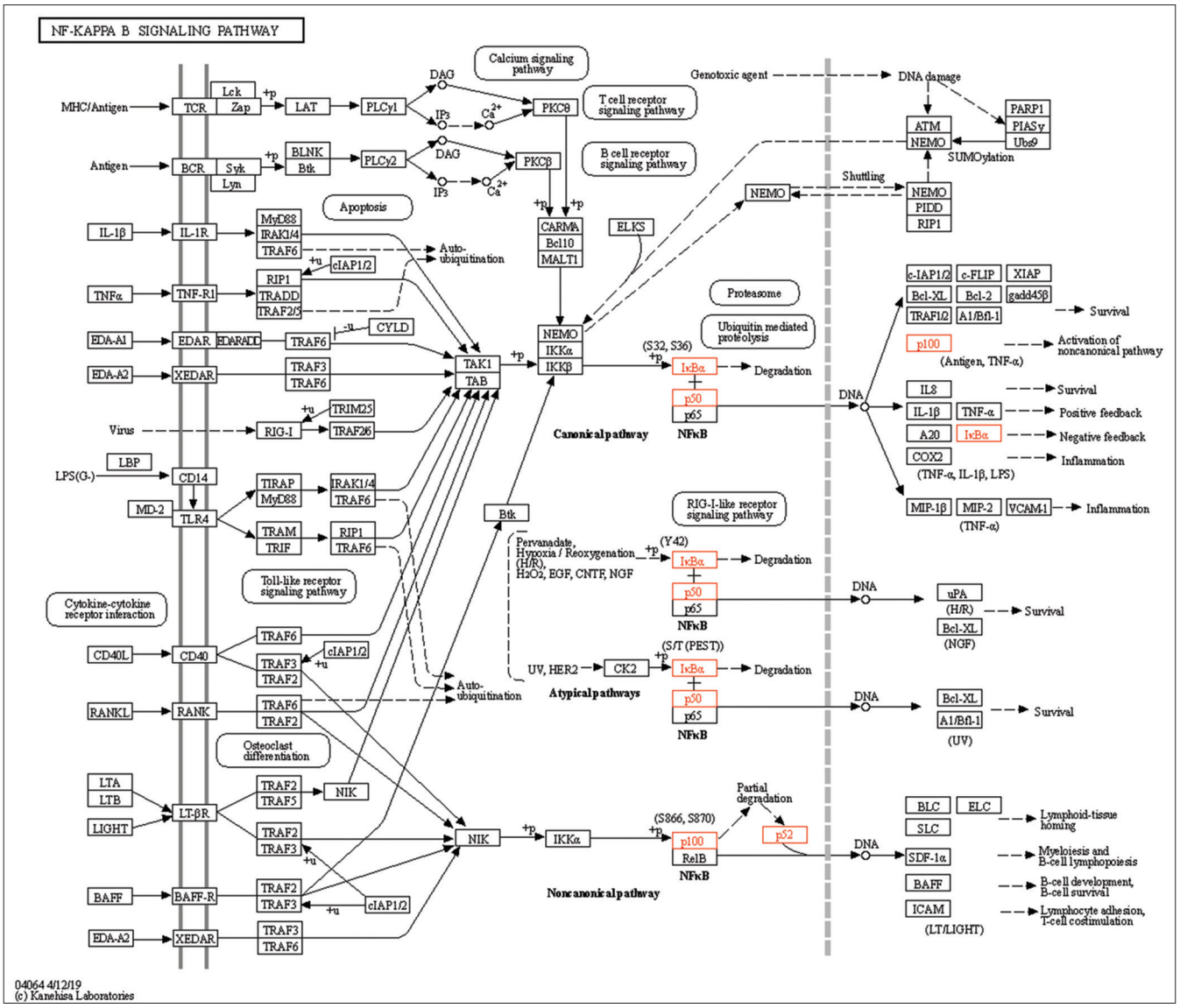

Figure 1: Nuclear factor-kappa B (NF-kappa B) is the generic name of a family of transcription factors that function as dimers and regulate genes involved in immunity, inflammation and cell survival. There are several pathways leading to NF-kappa B-activation. The canonical pathway is induced by tumour necrosis factor-alpha (TNF-alpha), interleukin-1 (IL-1) or byproducts of bacterial and viral infections. This pathway relies on IKK- mediated IkappaB-alpha phosphorylation on Ser32 and 36, leading to its degradation, which allows the p50/p65 NF-kappa B dimer to enter the nucleus and activate gene transcription. Atypical pathways are IKK-independent and rely on phosphorylation of IkappaB-alpha on Tyr42 or on Ser residues in IkappaB-alpha PEST domain. The non-canonical pathway is triggered by particular members of the TNFR superfamily, such as lymphotoxin-beta (LT-beta) or BAFF. It involves NIK and IKK-alpha-mediated p100 phosphorylation and processing to p52, resulting in nuclear translocation of p52/RelB heterodimers. [Copyright permission for KEGG (Kyoto Encyclopedia of Genes and Genomes) - map04064 NF-κB signalling pathway obtained from Kanehisa Laboratories, Japan. Ref.No-200501]

Statistical analysis

The Statistical Package for the Social Sciences (SPSS) software version 16.0 (IBM Corp, Chicago, IL, USA) was used. The level of significance ($P < 0.05$) was employed in all statistical comparisons. Quantitative data were recorded as mean ± standard deviation. The expressions of anti-NF-κB p65 between follicular and plexiform types of ameloblastoma were analyzed statistically using Chi-square test.

RESULTS

Among 20 cases of central ameloblastoma, 10 cases were follicular types and 10 cases were plexiform types. The positivity was predominantly observed in the peripheral tall columnar ameloblast-like cells, and the central stellate reticulum-like cells showed scattered positivity in a very few cases [Figures 2 and 3]. Among 10 cases of central follicular ameloblastoma, 3 cases (30%) showed positive immunoreactivity and the remaining

[Downloaded free from http://www.jomfp.in on Wednesday, January 20, 2021, IP: 157.49.192.193]

Table 1: The expression of nuclear factor-kappa B compared between central follicular and central plexiform ameloblastomas by Chi-square test

Groups	Total number of cases	Number of positive cases (%)	Number of negative cases (%)	χ^2	P
Follicular (central)	10	3 (30)	7 (70)	7.500	0.006 significant ($P<0.05$)
Plexiform (central)	10	9 (90)	1 (10)		

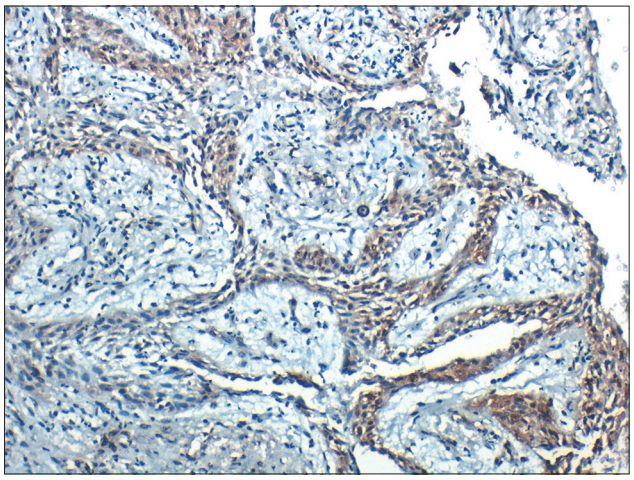

Figure 2: Plexiform ameloblastoma showing positive nuclear factor-kappa B immunoexpression in peripheral cells (Photomicrograph ×20)

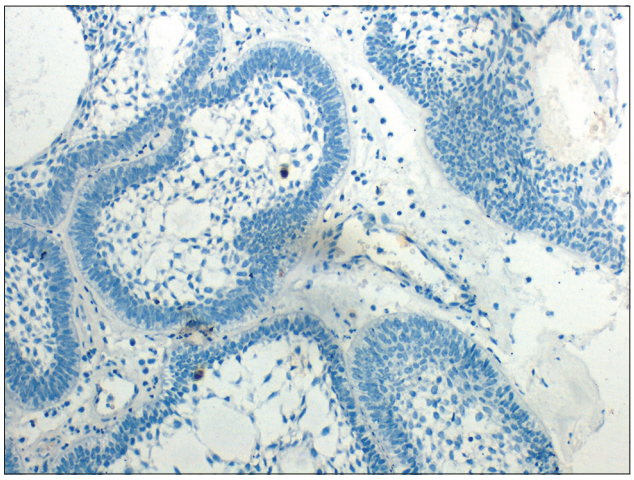

Figure 3: Follicular ameloblastoma showing negative nuclear factor-kappa B immunoexpression in peripheral cells (Photomicrograph ×20)

cases were negative (70%). Among 10 central plexiform cases, 9 cases (90%) showed positive immunoreactivity. The expression of NF-κB was compared between central follicular ameloblastoma and central plexiform ameloblastoma statistically using Chi-square test. The results were statistically significant between these two groups [Table 1].

DISCUSSION

Among the odontogenic neoplasms occurring in the jaws, ameloblastoma is unique because of its locally invasive behavior and high recurrence rate. Considerable molecular signaling variation exists among different clinical and histological patterns of ameloblastoma for which researches trying to identify the possible regulatory mechanism. Such investigations on tumor biology of ameloblastoma can lead to new non-surgical/minimal invasive therapeutic avenue.

The biological behavior (proliferation, apoptosis, matrix degradation and invasiveness) of these tumors varies within its histological types. Both apoptosis and the proliferating activity of the cells are implicated in the development of ameloblastoma.[5] The differed biological behavior behind follicular and plexiform ameloblastomas has never attained completeness because of the lack of rhythmic correlation regarding the exact mechanism.

Ameloblastoma, irrespective of its clinical and histological variants, has two relatively distinct patterns: peripheral ameloblast like cells demonstrating anti apoptotic proliferating pattern and central stellate reticulum like demonstrating pro-apoptotic and differentiation pattern. The expression of the molecular signals such as bcl 2 and bcl X,[5] proliferating cell nuclear antigen (PCNA) and Ki 67,[17] telomerase activity and telomerase reverse transcriptase (TERT),[18] survivin,[19] Ras/mitogen activated protein kinase (MAPK),[20] Akt, phosphatidylinositol 3 kinase (PI3K) and Phosphatase and tensin homolog deleted on chromosome 10 (PTEN),[21] tumor necrosis factor (TNF) α,[22] NF-κB,[16] cyclin D1,[23] FGFR2–RAS–BRAF,[24] cellular Myelocytomatosis (c- Myc),[25] and focal adhesion kinase (FAK)[26] shows the anti apoptotic/survival or proliferation behavior of the peripheral cells of ameloblastoma. The proapoptotic or cell death in the central stellate reticulum-like cells was activated through caspase-3, cytochrome c, apoptotic peptidase-activating factor 1, caspase-9, apoptosis-inducing factor and BAX.[5,27]

NF-κB is a double-edged sword. It induces both cell survival and apoptosis through the different regulatory mechanisms. NF-κB activation and its role in the survival of cancer cells are well documented in the literature. NF-κB targets many genes that facilitate inflammation (TNF, interleukin [IL]-1 and chemokines), cellular immortality (telomerase), cell survival (bcl-XL, cIAP, XIAP and cFLIP), angiogenesis (vascular endothelial growth factor, TNF, IL-1 and IL-8), proliferation (TNF, IL-1, IL-6,

[Downloaded free from http://www.jomfp.in on Wednesday, January 20, 2021, IP: 157.49.192.193]

cyclin D1 and c-Myc), tumor promotion (COX-2, iNOS, MMP-9 and uPA) and metastasis (ICAM-1, VCAM-1 and ELAM-1).[28] NF-κB regulates the downstream molecules and influences cell survival of tumor cells.

The expression of NF-κB has been reported more predominantly in the outer layer than the inner layer of ameloblastoma. However, the expression pattern among follicular and plexiform ameloblastomas has not been characterized.[16] In the present study, positive immunoexpression of anti-NF-κB p65 was found in 60% of the ameloblastoma cases and immunoexpression was found in peripheral ameloblast-like cells. The immunoexpression was restricted to the cell membrane of cuboidal or columnar type of peripheral cells of the tumor islands and cords. None of the central (stellate like) cells or stromal components stained positive for NF ϰB p65. There was a significant difference in the immunoexpression of anti-NF-κB p65 in plexiform ameloblastoma (90%) compared to that of follicular ameloblastoma (30%).

Neurotrophins (nerve growth factor [NGF], brain-derived neurotrophic factor, neurotrophin-3 and neurotrophin-4/5) and neurotrophin receptors (TrK A + B + C and p75-NTR) are a class of growth factors and play a major role in numerous biological functions such as cell survival, proliferation, regulation, differentiation, apoptosis and migration not only on neuronal cell growth but also correspondingly on a wide range of nonneuronal differentiating cells.[29] Their role in physiologic and pathologic conditions via Ras/MAPK pathway, PI3K pathway, Phospholipase C Gamma (PLCg) pathways, NF-ϰB signaling pathway and c Jun N terminal kinase signaling pathway has been established through early researches.[30] Positive anti-p75-NTR immunoexpression was found in the peripheral cells of follicular ameloblastoma (83.3%) comparing to that of plexiform ameloblastoma cases (10%).[31] The upregulation of p75-NTR could suppress NF-κB through IκB kinase.[32] In another study, the immunoexpression of anti-TrK A + B + C was found positive in peripheral ameloblastoma-like cells of plexiform ameloblastoma (70%) comparing to that of follicular ameloblastoma (4%) and the expression restricted to the cell membrane of cuboidal or columnar type of peripheral cells of the tumor islands and cords. This revealed a significant difference in the expression of anti-TrK A + B + C between follicular ameloblastoma and plexiform ameloblastoma.[33] The immunoexpression of NGF was studied between follicular and plexiform ameloblastomas. All the samples showed immunopositivity, but the intensity was strong in plexiform variant compared to follicular variant.[34] NGF ligand binding to p75NTR signals both pro survival and pro apoptotic effects and these functions are modulated by TrK.[35] In the present study, differed immunoexpression of NF ϰB was possibly due to the binding of neurotrophins(NGF) with p75NTR/TrK in peripheral ameloblast like cells of follicular and plexiform ameloblastomas.[9]

NF-κB activation affects hallmarks of the tumor through the transcription of genes involved in cell proliferation, survival, angiogenesis, inflammation and tumor promotion and metastasis.[36] There is a lack in the rhythmic correlation of the pathogenesis of ameloblastoma which causes hindrance to the nonsurgical treatment.[37] These findings suggest that the expression of neurotrophin receptors (p75NTR and TrK A + B + C) and neurotrophins like NGF in the peripheral ameloblast-like cells which were established through the previous study could be a possible reason behind the altered regulation of NF-κB in follicular and plexiform ameloblastomas.

CONCLUSION

By analyzing the course of literature, the expression of cell proliferating proteins (Ki-67 and PCNA), cell survival regulators (TERT and c-Myc), cell cycle regulators (cyclins), anti-apoptotic proteins (bcl-2 and bcl-X), cell proliferation enzymes (PCNA) and tumor progression molecules (MMP-9 and TIMP-1) was controlled through NF-κB signaling mechanism. The variation in the expression of NF-κB among follicular and plexiform ameloblastomas could be one of the possible reasons behind the differed biological behavior. Further studies on this pathway will lead us toward the targeted therapy with minimal surgical intervention for the betterment of the diseased.

Financial support and sponsorship
Nil.

Conflicts of interest
There are no conflicts of interest.

REFERENCES

1. Patsa S, Jadav RB, Halder GC, Ray JG, Datta S, Deb T. Demographic and histopathological variation of ameloblastoma: A hospital-based study. J Oral Maxillofac Pathol 2016;20:230-3.
2. Isolan CP, Moreira AG, Edges A, Post LK, Aitken-Saavedra JP. Successful conservative treatment of a mandibular unicystic ameloblastoma: 13-year follow-up. J Clin Exp Dent 2018;10:e1123-e1126.
3. Yoithapprabhunath TR, Nirmal RM, Ganapathy N, Mohanapriya S, Renugadevi S, Aravindhan R, *et al*,. Meta-terminology of Ameloblastoma. J Pharm Bioall Sci 2019;11:S140-5.
4. Soluk-Tekkeşin M, Wright JM. The World Health Organization classification of odontogenic lesions: A summary of the changes of the 2017 (4th) Edition. Turk Patoloji Derg 2018;34:1-18.
5. Sandra F, Nakamura N, Mitsuyasu T, Shiratsuchi Y, Ohishi M. Two relatively distinct patterns of ameloblastoma: An anti-apoptotic

[Downloaded free from http://www.jomfp.in on Wednesday, January 20, 2021, IP: 157.49.192.193]

proliferating site in the outer layer (periphery) and a pro-apoptotic differentiating site in the inner layer (center). Histopathology 2001;39:93-98.
6. González-González R, Molina-Frechero N, Damian-Matsumura P, Salazar-Rodriguez S, Bologna-Molina R. Immunohistochemical expression of Survivin and its relationship with cell apoptosis and proliferation in ameloblastomas. Dis Markers 2015;2015:301781.
7. Masthan KM, Anitha N, Krupaa J, Manikkam S. Ameloblastoma. J Pharm Bioallied Sci 2015;7:S167-70.
8. Taniguchi K, Karin M. NF-κB, inflammation, immunity and cancer: Coming of age. Nat Rev Immunol 2018;18:309-24.
9. Kanehisa M. Toward understanding the origin and evolution of cellular organisms. Protein Sci 2019;28:1947-51.
10. Zhang Q, Lenardo MJ, Baltimore D. 30 years of NF-κB: A blossoming of relevance to human pathobiology. Cell 2017;168:37-57.
11. Viennois E, Chen F, Merlin D. NF-κB pathway in colitis-associated cancers. Transl Gastrointest Cancer 2013;2:21-9.
12. Li W, Tan D, Zenali MJ, Brown RE. Constitutive activation of nuclear factor-kappa B (NF-kB) signaling pathway in fibrolamellar hepatocellular carcinoma. Int J Clin Exp Pathol 2009;3:238-43.
13. Rao SK, Pavicevic Z, Du Z, Kim JG, Fan M, Jiao Y, *et al*. Pro-inflammatory genes as biomarkers and therapeutic targets in oral squamous cell carcinoma. J Biol Chem 2010;285:32512-21.
14. Horie R. Molecularly-targeted Strategy and NF-κB in lymphoid malignancies. J Clin Exp Hematop 2013;53:185-95.
15. Xia Y, Shen S, Verma IM. NF-κB, an active player in human cancers. Cancer Immunol Res 2014;2:823-30.
16. Hendarmin L, Kanawa S, Yoshiga D. Anti-apoptotic role of NF-κB in TNF-α-induced apoptosis in an ameloblastoma cell line. Oral Sci Int 2008:96-103.
17. Sandra F, Mitsuyasu T, Nakamura N, Shiratsuchi Y, Ohishi M. Immunohistochemical evaluation of PCNA and Ki-67 in ameloblastoma. Oral Oncol 2001;37:193-8.
18. Kumamoto H, Kinouchi Y, Ooya K. Telomerase activity and telomerase reverse transciptase (TERT) expression in ameloblastomas. J Oral Pathol Med 2001;30:231-6.
19. Kumamoto H, Ooya K. Expression of survivin and X chromosome-linked inhibitor of apoptosis protein in ameloblastomas. Virchows Arch 2004;444:164-70.
20. Kumamoto H, Takahashi N, Ooya K. K-Ras gene status and expression of Ras/mitogen-activated protein kinase (MAPK) signaling molecules in ameloblastomas. J Oral Pathol Med 2004;33:360-7.
21. Kumamoto H, Ooya K. Immunohistochemical detection of phosphorylated Akt, PI3K, and PTEN in ameloblastic tumors. Oral Dis 2007;13:461-7.
22. Hendarmin L, Sandra F, Nakao Y, Ohishi M, Nakamura N. TNFalpha played a role in induction of Akt and MAPK signals in ameloblastoma. Oral Oncol 2005;41:375-82.
23. Kumar H, Vandana R, Kumar G. Immunohistochemical expression of cyclin D1 in ameloblastomas and adenomatoid odontogenic tumors. J Oral Maxillofac Pathol 2011;15:283-7.
24. Brown NA, Rolland D, McHugh JB, Weigelin HC, Zhao L, Lim MS, *et al*. Activating FGFR2-RAS-BRAF mutations in ameloblastoma. Clin Cancer Res 2014;20:5517-26.
25. Moosvi Z, Rekha K. c-Myc oncogene expression in selected odontogenic cysts and tumors: An immunohistochemical study. J Oral Maxillofac Pathol 2013;17:51-6.
26. Patil S, Sarode GS, Sarode SC, Anand R, Patil S. Focal adhesion kinase expression in ameloblastoma: A preliminary observational study. J Clin Diagn Res 2017;11:ZC47-50.
27. Kumamoto H, Kimi K, Ooya K. Immunohistochemical analysis of apoptosis-related factors (Fas, Fas ligand, caspase-3 and single-stranded DNA) in ameloblastomas. J Oral Pathol Med 2001;30:596-602.
28. Bharti AC, Aggarwal BB. Nuclear factor-kappa B and cancer: Its role in prevention and therapy. Biochem Pharmacol 2002;64:883-8.
29. Tan F, Thiele CJ, Li Z. Neurotrophin signaling in cancer. In: Kostrzewa RM, editor. Handbook of Neurotoxicity. NewYork: Springer; 2014. p. 1825-47.
30. Mitsiadis TA, Pagella P. Expression of Nerve Growth Factor (NGF), TrkA, and p75(NTR) in Developing Human Fetal Teeth. Front Physiol 2016;7:338.
31. Ragunathan YT, Madhavan NR, Mohan SP, Kumar SK. Immunohistochemical Detection of p75 Neurotrophin Receptor (p75-NTR) in Follicular and Plexiform Ameloblastoma. J Clin Diagn Res 2016;10:ZC63-6.
32. Yuanlong H, Haifeng J, Xiaoyin Z, Jialin S, Jie L, Li Y, *et al*. The inhibitory effect of p75 neurotrophin receptor on growth of human hepatocellular carcinoma cells. Cancer Lett 2008;268:110-9.
33. Jisha GB, Ilayaraja V, Yoithapprabhunath TR, Ganapathy N, Dineshshankar J, Nirmal RM. Immunohistochemical detection of Tyrosine Kinase receptor (TrK) in follicular and plexiform ameloblastoma-A novel study. J Oral Maxillofac Pathol 2020;24:125-30.
34. Yoithapprabhunath TR, Renugadevi S, Ganapathy N, Dineshshankar J, Yamunadevi A, Nirmal RM. Immunohistochemical detection of nerve growth factor (NGF) in follicular and plexiform ameloblastoma – A novel study. J Pharm Bioall Sci 2020;12:S569-75.
35. Rabizadeh S, Bredesen DE. Ten years on: Mediation of cell death by the common neurotrophin receptor p75(NTR). Cytokine Growth Factor Rev 2003;14:225-39.
36. Amit S, Ben-Neriah Y. NF-kappaB activation in cancer: A challenge for ubiquitination- and proteasome-based therapeutic approach. Semin Cancer Biol 2003;13:15-28.
37. Jhamb T, Kramer JM. Molecular concepts in the pathogenesis of ameloblastoma: Implications for therapeutics. Exp Mol Pathol 2014;97:345-53.