[Downloaded free from http://www.jpbsonline.org on Wednesday, July 13, 2022, IP: 103.70.191.6]

Original Article

Cyclooxygenase-2 (COX-2) Expression in Oral Submucous Fibrosis and Oral Squamous Cell Carcinoma: An Immunohistochemical Study

Potsangbam Aparnadevi, Ramdas M. Nirmal[2], Veeran Veeravarmal[2], Doddabasavaiah Basavapur Nandini[3], Chandrasekaran Kalyani[4], Deepak N. Singh[1], Thuckanaickenpalayam Ragunathan Yoithapprabhunath[5]

Departments of Oral Pathology and Microbiology and, Dental College, Regional Institute of Medical Sciences, Imphal, Manipur, India, [1]Oral Medicine and Radiology, Dental College, Regional Institute of Medical Sciences, Imphal, Manipur, India, [2]Department of Oral and Maxillofacial Pathology, Rajah Muthiah Dental College and Hospital, Annamalai University, Chidambaram, Tamil Nadu, India, [3]Department of Oral Pathology and Microbiology, Dental College, Regional Institute of Medical Sciences, Imphal, Manipur, India, [4]Independent Researcher, Consultant Oral Pathologist, Tamil Nadu, India, [5]Department of Oral and Maxillofacial Pathology, Vivekanandha Dental College for Women, Tamil Nadu, India

Submitted: 27-Jan-2022.
Revised: 14-Feb-2022.
Accepted: 15-Feb-2022.
Published: 13-Jul-2022.

ABSTRACT

Introduction: Growing evidence has shown that cyclooxygenase-2 (COX-2), an enzyme capable of catalyzing prostaglandin production, plays a key role in carcinogenesis. Selective COX-2 inhibitors have been shown to reduce the establishment of tumors such as oral squamous cell carcinoma (OSCC) and premalignant conditions such oral submucous fibrosis (OSMF) in experimental models. The aim of this study was to investigate the immunohistochemical expression of COX-2 in OSCC and OSMF with the normal oral mucosa as control.

Material and Methods: Forty-five formalin-fixed paraffin-embedded samples comprising 20 OSCC, 20 OSMF, and 5 normal oral mucosa specimens were withdrawn from the archives of the Department of Oral and Maxillofacial Pathology for immunohistochemical examination for COX-2 expression. Negative and less than 5% COX-2 positivity was considered negative expressions, while greater than or equal to 5% COX-2 positivity was considered positive expression. The data obtained were statistically analyzed.

Results: The difference in percentages of expression in normal mucosa, OSCC, and OSMF was highly significant ($P < 0.01$). In comparison to normal mucosa, OSCC and OSMF had an increased level of COX-2 expression. However, there was an insignificant difference between the various histological gradings of OSCC and OSMF.

Conclusion: The results of the present study confirm the role of COX-2 in carcinogenesis and in the progression of premalignant conditions to malignancy.

KEYWORDS: *Cyclooxygenase 2, dysplasia, oral squamous cell carcinoma, oral submucous fibrosis, premalignant, tobacco*

INTRODUCTION

Oral cancer accounts for 2–4% of all cancer cases in the world. Oral cancer is more common in India, with an incidence of around 45%. Oral cancer refers to a group of malignancies that can affect any part of the oral cavity, pharyngeal regions, or salivary glands and is sometimes interchangeably used with oral squamous cell carcinoma (OSCC), the most common of all oral neoplasms. OSCC is believed to account for more than 90% of all oral neoplasms. Tobacco smokers have a 6-fold increased chance of acquiring oral cancer than nonsmokers. Alcohol users are also 6 times more likely to acquire oral cancer than nondrinkers. When both habits are combined, the individuals have a 15-fold increased risk of oral cancer compared to nonusers. Patients infected with human immunodeficiency virus, human papillomavirus (HPV), Epstein–Barr virus, Hepatitis C virus, B-cell Hodgkin lymphoma,

Access this article online

Quick Response Code:

Website: www.jpbsonline.org

DOI: 10.4103/jpbs.jpbs_135_22

Address for correspondence: Dr. Potsangbam Aparnadevi, Department of Oral Pathology and Microbiology, Dental College, Regional Institute of Medical Sciences, Imphal - 795 004, Manipur, India.
E-mail: draparna1983@gmail.com

This is an open access article distributed under the terms of the Creative Commons Attribution-NonCommercial-ShareAlike 4.0 License, which allows others to remix, tweak, and build upon the work non-commercially, as long as the author is credited and the new creations are licensed under the identical terms.

For reprints contact: WKHLRPMedknow_reprints@wolterskluwer.com

How to cite this article: Aparnadevi P, Nirmal RM, Veeravarmal V, Nandini DB, Kalyani C, Singh DN, *et al.* Cyclooxygenase-2 (COX-2) expression in oral submucous fibrosis and oral squamous cell carcinoma: An immunohistochemical study. J Pharm Bioall Sci 2022;14:S769-73.

[Downloaded free from http://www.jpbsonline.org on Wednesday, July 13, 2022, IP: 103.70.191.6]

patients undergoing organ transplants, and those on immunosuppressive medication are at a higher risk of developing OSCC.[1]

Oral submucous fibrosis (OSMF) is a chronic, debilitating illness that causes epithelial atrophy and tissue fibrosis leading to burning sensation in the mouth, trismus, dysphagia, and altered taste sensation. OSMF is well established as a precursor to oral cancer with a malignant transformation rate of 1.5–15%. OSMF is common in women than men and usually seen in 20–40 years of age. The risk factors of OSMF include chewing betel nut/arecanut, spicy foods, and deficiency of iron, vitamin B, C, HPV infection, and genetic mutations. When there is combined habit of betel nut and tobacco, risk of malignant transformation is higher. Histologically, three grades (I–III) of OSMF are described.[2-4]

In numerous premalignant and malignant lesions, cyclooxygenase-2 (COX-2) is elevated, resulting in increased synthesis of prostaglandins (PGs) such as prostaglandin E2 (PGE2). It has the ability to influence various aspects of carcinogenesis, including angiogenesis, invasion, and proliferation.[5] Oral cancer tissues exhibit 50 times more COX-2 mRNA than noncancer areas, whereas oral mucosa of smokers expresses 4-fold more COX-2 mRNA than nonsmokers.[6] COX-2 is also commonly produced in oral malignant tumors. OSMF is also linked to inflammatory changes in some phases of the disease. PG is a major inflammatory mediator whose production is regulated by a number of enzymes such as COX-2.[7] COX-2 overexpression has been linked to increased tumor vascularity, PGE2 levels, vascular endothelial growth factor, and peroxisome proliferator-activated receptor, with a combination of high COX-2 and high PGE2 levels being linked to a lower 5-year survival rate.[8-11]

The purpose of the present study is to evaluate the expression of COX-2 immunoexpression in the tissues of normal, OSMF, and OSCC patients.

Materials and Methods

Sampling

A total of 45 formalin-fixed paraffin-embedded samples were retrieved from the archives of the Department of Oral and Maxillofacial Pathology, Rajah Muthiah Dental College and Hospital, Annamalai University, comprising 20 OSCC (14 well, 5 moderate, 1 poorly differentiated), 20 OSMF (8 histological grade I, 7 grade II, 5 grade III), and 5 normal oral mucosa specimens. The study was approved by the Institutional Ethics Committee. Hematoxylin and eosin were used to stain 3–5 micron sections prepared from formalin-fixed paraffin-embedded blocks. The histologic grades of OSMF and OSCC were classified according to the World Health Organization Classification of Tumors[12] by two independent pathologists who had no prior knowledge of the clinical data. In cases where the pathologists had varying opinions, the final evaluation was reached after consensus discussions. Patients who had not received any treatment for their premalignant condition were included in the sample as controls.

Immunohistochemistry

Primary rabbit monoclonal antibody (BioGenex Life Sciences Pvt. Ltd., India) was used to immunostain the prepared sections for COX-2 expression. In a humidified compartment, sections were incubated overnight at 4°C with a primary antibody. The sections were stained the next day with a labeled Horse Radish Peroxidase secondary antibody solution (Scy Tek Laboratories, USA). 0–5% 3-Diaminobenzidine tetrahydrochloride in phosphate-buffered saline was used to reveal bound peroxidase. Sections were then dehydrated, cleansed, and mounted. COX-2 positive cells that stained positive for immunohistochemistry were manually counted.

The stained sections were examined for the positivity of expression of COX-2. The percentage of tumor cells, positive for COX-2 expression, was used to determine the level of positivity. Negative and less than 5% COX-2 positivity was considered as negative expression and greater than or equal to 5% COX-2 positivity as positive expression. Photomicrographs were taken from selected areas under 10X and 40X magnifications. The scoring was performed as per Sappayatosok *et al.*,[13] where 0 denoted no stained cells; 1 referred to less than 25% of cells showing positivity; 2 referred to 25–50% of cells showing positivity; 3 referred to 50–75% of cells showing positivity; and 4 referred to greater than 75% of cells showing positivity. The intensity of staining (viewed at a magnification of ×100) was on the following scale: 0, no staining seen; 1+, mild staining; 2+, moderate staining; and 3+, intense staining. The scores of area and intensity of staining were combined to give a value between 0 and 7.

Statistical analysis

Data were analyzed usingStatistical Packages for Social Sciences (IBM SPSS Statistics, SPSS South Asia Pvt Ltd., Bangalore, for Windows, Version 26.0). The Kruskal–Wallis test was used to compare the three groups in terms of immunoreactivity. Mann–Whitney test and Chi-square test were used to evaluate the association between COX-2 expression and various grades of OSMF and OSCC. For the comparison of COX-2 expression in OSMF between those with/without dysplasia, the Mann–Whitney test was used.

[Downloaded free from http://www.jpbsonline.org on Wednesday, July 13, 2022, IP: 103.70.191.6]

Results

Histologically confirmed specimens (n = 45) of OSCC, OSMF, and normal oral mucosa were subjected to standard immunohistochemical techniques for comparison of COX-2 expression. Grading of the study sample was done following the histopathological observation.

COX-2 was not expressed in normal mucosa. COX-2 was expressed in 20% (4 cases) of OSMF and 70% (14 cases) of OSCC [Table 1]. There was a statistically significant difference observed in COX-2 expression between the three examined groups, as well as between OSCC and normal oral mucosa, OSCC, and OSMF ($P < 0.01$) [Table 1, Figures 1 and 2].

The OSMF samples were classified into grades I– III, while OSCC samples were categorized as well-differentiated (W), moderately differentiated (M), and poorly differentiated (P). COX-2 was expressed in four cases of OSMF (three grade I, one grade II, and zero in grade III). COX 2 was expressed in 14 cases of OSCC. The difference was insignificant between different grades of OSCC and different grades of OSMF ($P > 0.05$) [Tables 2 and 3].

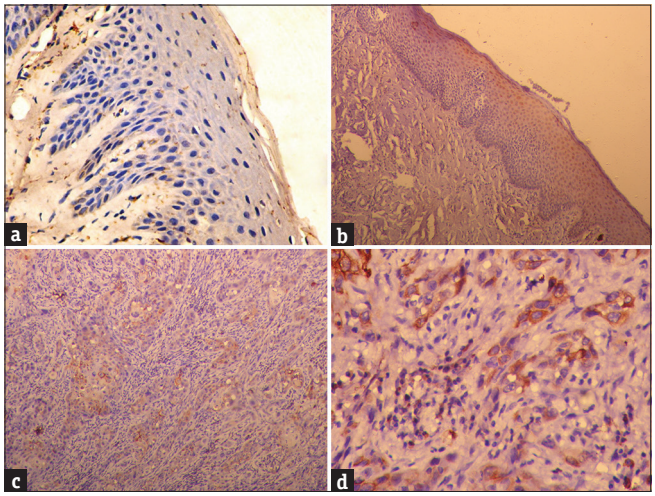

Figure 1: Immunohisto chemistry expression of COX-2. (a) Normal mucosa showing negative COX-2 expression (40×), (b) positive immunoreactivity for COX-2 expres sion in OSMF (10×), (c) generalized COX-2 expression (10×) in OSCC (W), and (d) COX-2 expression (40×) in OSCC (M)

In this study, five cases of OSMF specimens had Grade I dysplasia (mild), four cases had Grade II dysplasia (moderate), and three cases had Grade III dysplasia (severe). No significant difference was seen in COX-2 expression between OSMF with dysplasia (12 cases) compared to OSMF without dysplasia (8 cases).

Discussion

In this study, COX-2 was not expressed in normal mucosa. The current study found that OSCC had higher COX-2 expression than OSMF and normal oral mucosa, indicating that COX-2 plays a role in carcinogenesis. COX-2 overexpression has been seen in a variety of human malignancies, including head and neck cancers and esophageal cancers. The chemopreventive effects of selective COX-2 inhibitors, as well as their inhibitory effect on tumor growth and metastasis, and augmentation of the anticancer benefits of radiotherapy and chemotherapy in experimental animals and human models indicate that this protein plays a role in cancer.[14]

The findings of this study on grades of malignancy are consistent with prior studies that established no association between COX-2 expression and grading of malignancy. There was an insignificant difference in COX-2 expression between different histological grades of OSCC in the study conducted by Seyedmajidi

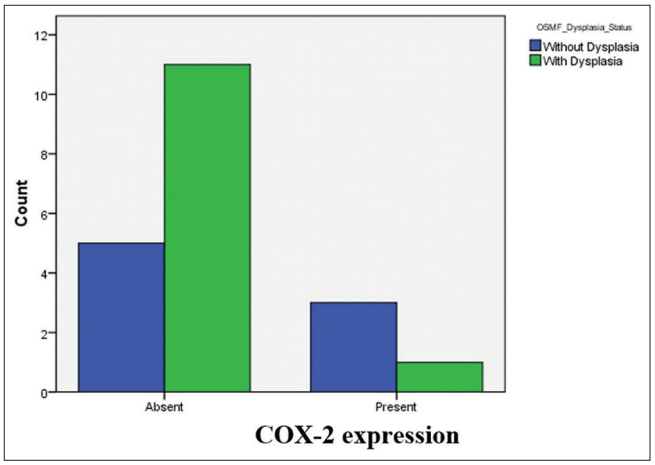

Figure 2: COX-2 expression between OSMF with dysplasia and without dysplasia

Table 1: COX-2 expression in normal, OSMF, and OSCC

Groups	COX-2 Expression		n	Chi-square test	P	Intergroup comparison		
	Positive	Negative				Normal-OSMF	Normal-OSCC	OSMF-OSCC
Normal	0	5	5	13.85	0.001**	0.29	0.006**	0.002**
OSMF	4	16	20					
OSCC	14	6	20					
Total	18	27	45					

**Highly significant

[Downloaded free from http://www.jpbsonline.org on Wednesday, July 13, 2022, IP: 103.70.191.6]

Table 2: Variation in COX-2 expression among the different grades of OSMF

OSMF Grading	*n*	Chi-square test	*P*	Intergroup comparison		
				I-II	I-III	II-III
Grade I	8	2.78	0.25	0.33	0.13	0.40
Grade II	7					
Grade III	5					
Total	20					

Table 3: Variation in COX-2 expression among the different grades of OSCC

OSCC Dysplasia status	*n*	Chi-square test	*P*	Intergroup comparison		
				P-M	P-W	M-W
Poorly differentiated (P)	1	3.49	0.18	1.00	0.41	0.09
Moderately differentiated (M)	5					
Well differentiated (W)	14					
Total	20					

et al.,[14] Pandey *et al.*,[15] Amirchaghmaghi *et al.*,[16] and Itoh *et al.*[17] These findings supported the outcome of the present study. On the other hand, our observations contradict previous studies that found an inverse relationship between COX-2 expression and histological grade of malignancy, as well as evidence that demonstrated COX-2 expression is higher in poorly differentiated OSCC.[18-21]

The primary regulating enzyme in tissue inflammation, PG-endoperoxide synthase, also known as cyclooxygenase (COX), is found in two isoforms: COX-1 and COX-2. It is undetectable in normal tissue but induced by proinflammatory mediators or mitogenic stimuli. Overexpression of COX-2, an inducible form of COX, derived from arachidonic acid, has been found to promote cancer by activating carcinogens, cytokines, neoangiogenesis, enhancing progression, and suppressing apoptosis. Researchers noted that alterations in COX gene expression precede molecular changes in oral premalignant conditions.[22]

The inflammatory process is accountable for about 15% of all malignancies. Emerging research suggests a link between OSCC and chronic inflammation. Oral inflammatory disorders such as oral lichen planus, OSMF, and oral discoid lupus are significant risk factors for the development and progression of OSCC. Activated cytokines, chemokines, PGE2, COX-2, reactive oxygen species, and different transcription factors such as interleukins, tumor growth factors abound in the tumor microenvironment. These proinflammatory mediators promote tumorigenesis by inducing proliferation, epithelial-to-mesenchymal transition, and invasion in genetically predisposed lesions or in tumor-suppressor genes and/or oncogenes with mutations.[23]

COX-2 levels have also been seen in potentially premalignant oral lesions. Tissue inflammation is thought to play a role in the development of tissue fibrosis. OSMF is a potentially malignant condition in which immunoinflammatory mechanisms are known to play a role in pathophysiology and malignant transformation. There is a dearth of studies in the literature to evaluate the COX-2 expression in OSMF.

In present study, COX-2 expression was slightly higher in OSMF than normal mucosa though result was not significant. This was contradictory to findings of Rangaswamy *et al.* and Tsai *et al.*[22,24] The difference was highly significant between OSMF and OSCC. COX-2 expression was much higher in OSMF specimens, and it was detected commonly in epithelial cells, endothelial cells, and fibroblasts. COX-2 expression was also elevated in cells treated with arecoline as early as half an hour, indicating that COX-2 is an early cellular response. When gingival keratinocytes were exposed to extracts of areca nut produces 1.4–3.4 times more PGE2 and 1.1–1.7 times more PGE1 was observed.[22] COX-2 was expressed in four cases of OSMF (three Grade I, one grade II, and zero in grade III), which may be explained by the fact that inflammation is more in early OSMF. The difference was insignificant between different histologic grades of OSMF similar to Rangaswamy *et al.*[22] There was no significant difference in expression of COX-2 in OSMF with dysplasia compared to OSMF without dysplasia similar to Rangaswamy *et al.*[22]

COX-2 is also known to have an important role in tumorigenesis-associated processes such as apoptosis, angiogenesis, and immunomodulation. As a result, COX2-based therapies, such as COX-2 inhibitors, have a lot of promising results to be used as adjuvants to improve overall response rates or as targeted medicines for head and neck patients.[6]

The wide variation in pathways and factors leading to oral carcinogenesis may influence the increased expression of COX-2 during oral carcinogenesis, which may depend on the developmental stage of the tumor, as well as etiologic factors such as the types of mutations and distinct types of injuries affecting different regions.[14] Furthermore, considerable research is necessary to clarify which of these processes has a greater role in the development and progression of OSCC. Moreover, studies indicate that COX-2 can be identified as an important determinant or a marker in determining prognosis and treatment strategies for OSCC and OSMF.[9,22,23]

[Downloaded free from http://www.jpbsonline.org on Wednesday, July 13, 2022, IP: 103.70.191.6]

Conclusion

The present study indicates that COX-2 expression may be a crucial factor or predictor of the malignant transformation of premalignant lesions in the oral cavity or in the formation of mucosal premalignant lesions. Further research studies on this aspect provide insight into early intervention measures with COX inhibitors or immune modulators for the welfare of mankind.

Financial support and sponsorship

Nil.

Conflicts of interest

There are no conflicts of interest.

References

1. Markopoulos AK. Current aspects on oral squamous cell carcinoma. Open Dent J 2012;6:126-30.
2. Shih Y, Wang T, Shieh T, Tseng Y. Oral submucous fibrosis: A review on etiopathogenesis, diagnosis, and therapy. Int J Mol Sci 2019;20:2940.
3. Yoithapprabhunath TR, Maheswaran T, Dineshshankar J, Anusushanth A, Sindhuja P, Sitra G. Pathogenesis and therapeutic intervention of oral submucous fibrosis. J Pharm Bioallied Sci 2013;5:85-8.
4. Gupta P, Sinor P, Bhonsle R, Pawar V. Oral submucous fibrosis in India: A new epidemic? Natl Med J India 1998;11:113-6.
5. Søland TM, Husvik C, Koppang HA, Boysen M, Sandvik L, Clausen OPF, *et al*. A study of phosphorylated ERK1/2 and COX-2 in early stage (T1–T2) oral squamous cell carcinomas. Oral Pathol Med 2008;37:535-42.
6. Frejborg E, Salo T, Salem A. Role of cyclooxygenase-2 in head and neck tumorigenesis. Int J Mol Sci 2020;21:9246.
7. Tilakaratne WM, Klinikowski MF, Saku T, Peters TJ, Warnakulasuriya S. Oral submucous fibrosis: Review on aetiology and pathogenesis. Oral Oncol 2006;42:561-8.
8. Chan G, Boyle JO, Yang EK, Zhang F, Sacks PG, Shah JP, *et al*. Cyclooxygenase-2 expression is up-regulated in squamous cell carcinoma of the head and neck. Cancer Res 1999;59:991-4.
9. Chang BW, Kim DH, Kowalski DP, Burleson JA, Son YH, Wilson LD. Prognostic significance of Cyclooxygenase-2 in oropharyngeal squamous cell carcinoma. Clin Cancer Res 2004;10:1678-84.
10. Jaeckel EC, Raja S, Tan J, Das SK, Dey SK, Girod DA, *et al*. Correlation of expression of cyclooxygenase-2, vascular endothelial growth factor, and peroxisome proliferator-activated receptor [δ] with head and neck squamous cell carcinoma. Arch Otolaryngol Head Neck Surg 2001;127:1253-66.
11. Gallo O, Franchi A, Magnelli L, Sardi I, Vannacci A, Boddi V, *et al*. Cyclooxygenase-2 pathway correlates with VEGF expression in head and neck cancer. Implications for tumor angiogenesis and metastasis. Neoplasia 2001;3:53-61.
12. Barnes L, Eveson JW, Reichart PA, Sidranskiy D. World Health Organization Classification of Tumours. Pathology and Genetics of Head and Neck Tumours. 1st ed. Lyon, France: IARC Press; 2005.
13. Sappayatosok K, Maneerat Y, Swasdison S, Viriyavejakul P, Dhanuthai K, Zwang J, *et al*. Expression of pro-inflammatory protein, iNOS, VEGF and COX-2 in oral squamous cell carcinoma (OSCC), relationship with angiogenesis and their clinico-pathological correlation. Med Oral Patol Oral Cir Bucal 2009;14:E319-24.
14. Seyedmajidi M, Shafaee S, Siadati S, Khorasani M, Bijani A, Ghasemi N. Cyclo-oxygenase-2 expression in oral squamous cell carcinoma. J Can Res Ther 2014;10:1024-9.
15. Pandey M, Prakash O, Santhi WS, Soumithran CS, Pillai RM. Overexpression of COX-2 gene in oral cancer is independent of stage of disease and degree of differentiation. Int J Oral Maxillofac Surg 2008;37:379-83.
16. Amirchaghmaghi M, Mohtasham N, Mozaffari PM. Comparison of COX2 expression between oral squamous cell carcinoma, leukoplakia and normal mucosa. J Contemp Dent Pract 2012;13:205-9.
17. Itoh S, Matsui K, Furuta I, Takano Y. Immunohistochemical study on overexpression of cyclooxygenase-2 in squamous cell carcinoma of the oral cavity: Its importance as a prognostic predictor. Oral Oncol 2003;39:829-35.
18. Nagatsuka H, Siar CH, Tsujigiwa H, Naomoto Y, Han PP, Gunduz M, *et al*. Heparanase and cyclooxygenase-2 gene and protein expressions during progression of oral epithelial dysplasia to carcinoma. Ann Diagn Pathol 2012;16:354-61.
19. Shibata M, Kodani I, Osaki M, Araki K, Adachi H, Ryoke K, *et al*. Cyclo-oxygenase-1 and -2 expression in human oral mucosa, dysplasias and squamous cell carcinomas and their pathological significance. Oral Oncol 2005;41:304-12.
20. Cao XP, Zhang ST, Wu HY, Liu XJ, Zhang YY. Relationship between the expression of cyclooxygenase-2 and microvessel density in oral squamous cell carcinoma. Hua Xi Kou Qiang Yi Xue Za Zhi 2005;23:431-3.
21. Renkonen J, Wolff H, Paavonen T. Expression of cyclo-oxygenase-2 in human tongue carcinoma and its precursor lesions. Virchows Arch 2002;440:594-7.
22. Rangaswamy S, Chikkalingaiah RG, Sharada P, Kumar VK. Expression of cyclooxygenase 2 in oral submucous fibrosis: An immunohistochemical pilot study. J Oral Maxillofac Pathol 2019;23:301.
23. Niklander SE. Inflammatory mediators in oral cancer: Pathogenic mechanisms and diagnostic potential. Front Oral Health 2021;2:642238.
24. Tsai CH, Chou MY, Chang YC. The up-regulation of cyclooxygenase-2 expression in human buccal mucosal fibroblasts by arecoline: A possible role in the pathogenesis of oral submucous fibrosis. J Oral Pathol Med 2003;32:146-53.