Downloaded from http://journals.lww.com/jpat by BhDMf5ePHKav1zEoum1tQfN4a+kJLhEZgbsIHo4XMi0hCywCX1AWnYQp/IlQrHD3i3D0OdRyi7TvSFl4Cf3VC1y0abggQZXdgGj2MwlZLeI= on 05/10/2023

Original Article

Analysis of Inheritance patterns, gender dimorphism and their correlation in lip and palm prints – A cross-sectional study

Raviteja Vanguru, Swetha Pasupuleti, Ravikanth Manyam, Alapati Naga Supriya, Birajdar Smita Shrishail, Thuckanaickenpalayam Ragunathan Yoithapprabhunath[1]

Department of Oral Pathology, Vishnu Dental College, Andhra Pradesh, [1]Vivekanandha Dental College for Women, Tamil Nadu, India

Abstract

Background: Forensic sciences deal with key areas to be included in judicial makeup that has been approved by both the court and the scientific community, which distinguishes truth from counterfeit. Lip and palmprints are one of a kind and do not change during the lifetime of a person unless any pathologies.

Objectives: To evaluate the heritability, and gender dimorphism of lip and palm prints among parents and their offspring.

Methods: A total of 280 participants were included in the study. Lip and palm prints were collected from participants using a digital camera. The photographic data obtained is subjected to Adobe Photoshop and analysed for inheritance. Gender dimorphism is evaluated by the predominant lip pattern and palm ridge count in four designated areas.

Results: A positive resemblance of 28.4% was found between parents and offspring in lips, and for the right palm, it was 60.2% and 55.12% for the left palm (principal lines) which are statistically insignificant. In all six quadrants, the most predominant lip pattern found in males is type 5, and in females, type 1^{1}. The mean palm ridge density was significantly higher among females than males in all designated areas.

Conclusion: The digital method of analysing lip and palm print images with Adobe Photoshop 7 software is a convenient method that allows for better visualisation and easier lip and palm print recording and identification. Considerable inheritance patterns and gender dimorphism were observed that aid in personal identification.

Keywords: Correlation, forensic identification, gender dimorphism, heritability, inheritance, lip prints, palmprints

Address for correspondence: Dr. Raviteja Vanguru, Department of Oral Pathology, Vishnu Dental College, Andhra Pradesh, India.
E-mail: vanguriraviteja55@gmail.com

Submitted: 22-Dec-2022, **Revised:** 02-Feb-2023, **Accepted:** 16-Feb-2023, **Published:** 21-Mar-2023

INTRODUCTION

Forensic sciences deal with key areas to be included in judicial makeup that has been approved by both the court and the scientific community, which distinguishes truth from forged.[1,2] Identification of individuals is a crucial task in forensic investigation.[3,4] Forensic odontology approaches include rugoscopy, cheiloscopy, bite marks,

Access this article online

Quick Response Code:

Website: www.jomfp.in

DOI: 10.4103/jomfp.jomfp_535_22

This is an open access journal, and articles are distributed under the terms of the Creative Commons Attribution-NonCommercial-ShareAlike 4.0 License, which allows others to remix, tweak, and build upon the work non-commercially, as long as appropriate credit is given and the new creations are licensed under the identical terms.

For reprints contact: WKHLRPMedknow_reprints@wolterskluwer.com

How to cite this article: Vanguru R, Pasupuleti S, Manyam R, Supriya AN, Shrishail BS, Yoithapprabhunath TR. Analysis of Inheritance patterns, gender dimorphism and their correlation in lip and palm prints – A cross-sectional study. J Oral Maxillofac Pathol 2023;27:130-7.

Downloaded from http://journals.lww.com/jpat by BhDMf5ePHKav1zEoum1tQfN4a+kJLhEZgbsIHo4XMi0hCywCX1AWnYQp/IlQrHD3i3D0OdRyi7TvSFl4Cf3VC1y0abggQZXdgGj2MwlZLeI= on 05/10/2023

radiographs, photographs, and molecular methods among which lip and palmprints are unique due to their stable physical form during the entire lifetime of a person.[2,4-7]

The study of lip prints is defined as cheiloscopy and its importance was first mentioned by Fischer in 1902. Later they were used in the field of criminology by Diou de Lille in 1930.[2] Development of the lip starts in the fifth week *in vitro* and by the ninth week, the formation of the upper lip development is completed and does not change for the rest of human life, unless a pathology or severe trauma occurs.[8-11] Lip prints are the fissures and lines found in the transition zone between the inner labial mucosa and the outer skin of the lips.[2,4,9,10,12-19] They are verified to recover after undergoing alterations like minor trauma, inflammation, and diseases like herpes; hence, they play a beneficial role in human identification.[2,8,12]

Although there are several classifications for lip prints, the most widely used classification was by Suzuki and Tsuchihashi and it is as follows[2,5,7,8,12-15]: [Figure 1].

1. Type I: vertical grooves that run across the entire lip.
2. Type I': vertical grooves that do not cover the entire lip.
3. Type II: Branched grooves.
4. Type III: Intersected grooves.
5. Type IV: Reticular grooves.
6. Type V: Grooves that cannot be morphologically distinguished.

The connecting link between lip prints and palmprints is recommended as the uniqueness of lip prints in an individual are analogues to palmprints because of their property of absolute identity.[16]

The science of dermatoglyphics involves the study of palmprints and fingerprints and was coined by Cummins and Midlo in 1926.[2,17-20] Palmprints are more distinctive than fingerprints because they include more information.[2,17] Detailed analysis of palmprints has become vital to identifying the suspect and the related crime scene. Jain and Feng have mentioned that about 30% of the latent prints recovered from crime scenes are from palms.[21,22]

The classification given by Wu *et al.*[18] was followed in the study for the palm inheritance analysis [Figure 2].

Category 1: Palmprints with one principal line.
Category 2: Palmprints with two principal lines and no intersection.
Category 3: Palmprints with two principal lines and one intersection.
Category 4: Palmprints with three principal lines and no intersection.
Category 5: Palmprints with three principal lines and one intersection.
Category 6: Palmprints with three principal lines and more than one intersection

Dermatoglyphic prints are produced before the 19th week of pregnancy and are usually resistant to alterations due to age or environmental circumstances.[23,24] They are more often the product of a biogenetic impact than the physical environment. Only prenatal exogenic or genetic factors can cause palm ridge injury and divergence from their typical configuration. It has been proven that sex chromosomes are one of the variables that influence dermatoglyphic changes during maturation.[25] The presence of the Y chromosome, as well as high testosterone levels, causes a delay in maturation.[19]

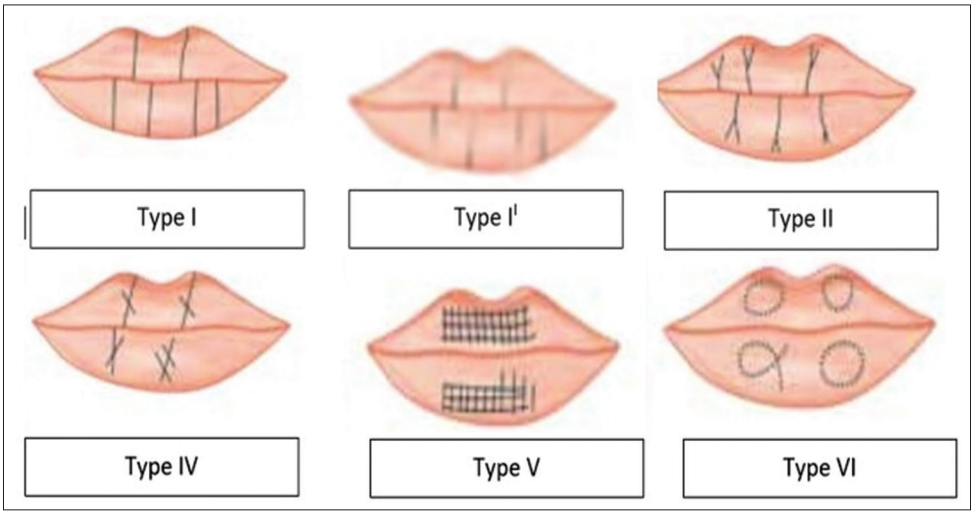

Figure 1: Lip print classification by Suzuki and Tsuchihashi

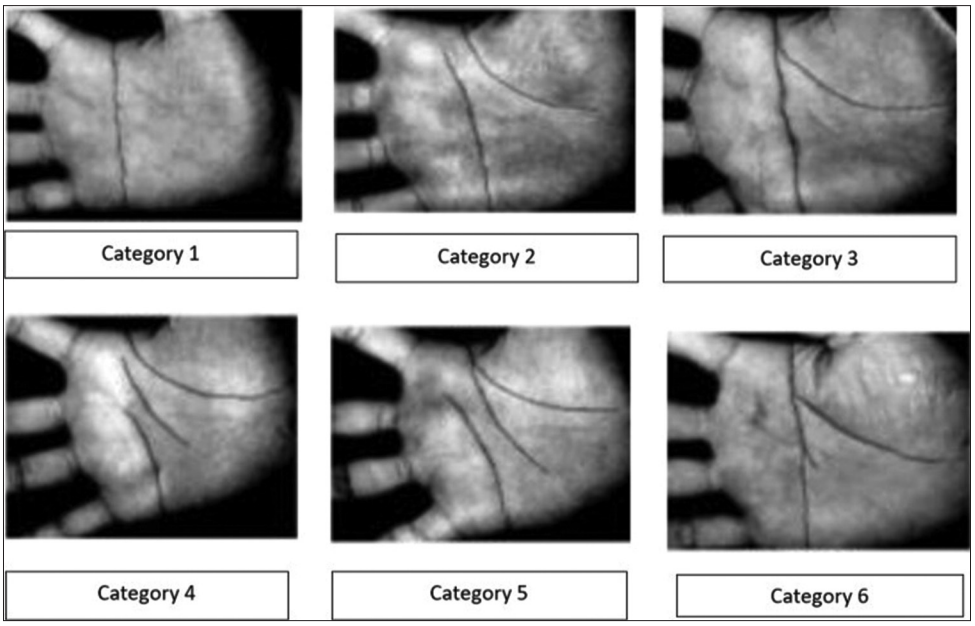

Figure 2: Palm print classification by Wu *et al*

The establishment of dactyloscopy and cheiloscopy can be used as a reference in criminal case studies and civil litigations that may be useful, particularly in forensic science and justice. Only very few studies have been successfully established with lip print inheritance, whereas studies on the inheritance of palmprints are scanty. Our present study was an attempt to find the correlation between inheritance in palm and lip prints and gender dimorphism in different parts of south India. To the best of our knowledge, a study of the correlation between the inheritance of two parameters, palmprints, lip prints, and their gender dimorphism by the digital method, is the first of its kind performed in the southern state of India.

MATERIALS AND METHODS

Study design

This was a cross-sectional study conducted in the southern state of India. The sample size was calculated using G-power 3.1 software, and the calculations were based on an effect size of 0.371 with an alpha level of 0.05 and the desired power of 80%; the estimated total sample size was 272 which was rounded to 280 participants. Family with two children willing to participate and give their lip and palm prints were included. Any participants with developmental/traumatic/corrected/pathological anomalies of lips, palms, and participants worried about giving their lip and palm details were excluded. The study protocol was explained to participants, and written consent in both vernacular and English languages was taken.

Data collection

Lip and palm photos were obtained by using a digital camera (Canon EOS 3000 D DSLR) from all participants. While taking photographs, all participants were instructed to position their feet parallel to the floor and head straight for lip prints, and the palmar portion of the upper arms parallel to the floor for the palm prints.

In the present study, lip print classification by Y Tsuchihashi and T Suzuki was followed. As there is no standard described protocol for segmentation of the lip, a criterion by Dongarwar *et al.* and Vijay Kautilya *et al.* was adopted. Lip print data was divided into six segments (by making two vertical lines on either side lateral to the philtrum of lips) using Adobe Photoshop (V 15.0) for easy analysis by minimising overlapping lip patterns. Inheritance among parents and offspring was studied by comparing the lip prints in all six segments, and it was considered positive if three or more segments show the same patterns among parents and offspring. Gender dimorphism was studied by evaluating the predominant lip patterns [Figure 3].

Obtained palm photo prints were studied according to Wu *et al*.'s classification. Inheritance among parents and siblings was assessed using principal lines (heart line, headline, and lifeline) as mentioned by Wu. *et al.* Gender dimorphism using palm photo print was studied by measuring the ridge density upon marking a 5 × 5 mm square on the palm in four areas (thenar eminence, hypothenar region, proximal triradius of second and fifth digit) followed by counting the number of ridges in each square. A comparison between lip and palm photo prints was made by evaluating the

Downloaded from http://journals.lww.com/jpat by BhDMf5ePHKav1zEoum1tQfN4a+kJLhEZgbsIHo4XMi0hCywCX1AWnYQp/IlQrHD3i3D0OdRyi7TvSFl4Cf3VC1y0abggQZXdgGj2MwlZLeI= on 05/10/2023

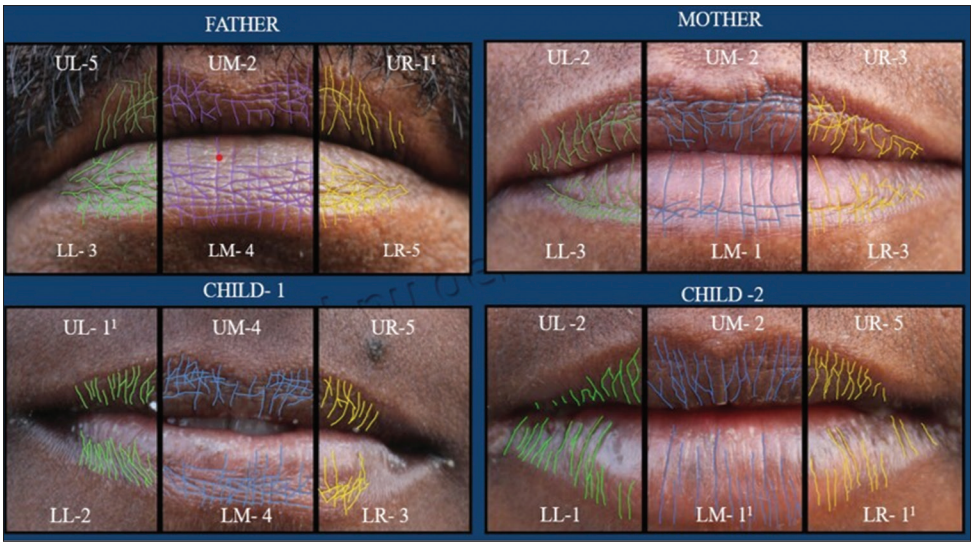

Figure 3: Adobe photoshop images of lip grooves and their patterns. *UL = upper left, UM = upper-middle, UR = upper right, LL = lower left, LM = lower middle, LR = lower right

predominant lip photo prints to the predominant palm photo prints [Figure 4]. (According to Y Tsuchihashi and T Suzukis and Wu. *et al*., classifications)

Statistical analysis

All collected data were subjected to statistical analysis using SPSS software (V.21.0, IBM, NY). Descriptive analysis was performed, and a Chi-square test was used to analyse the data. A *P* value < 0.05 was considered statistically significant.

RESULTS

Lip prints

In the present study, there was 28.3% lip pattern inheritance observed between parents to offspring with father–son (46.15%), mother–daughter (33.30%), mother–son (30.70%), and father–daughter (14.80%) inheritance, which is statistically insignificant. However, there was a 75% variation in inheritance which was noticed among siblings [Graph 1].

In the present study, there was a significant difference in each segment except upper left and lower right with an overall predominant lip print pattern in males and females being 1^1 suggestive of no significant gender dimorphisms (Y Tsuchihashi and T Suzuki). In the upper left segment, both males and females showed type 3 as the predominant pattern. In the upper-middle segment, the males had type 5 and females showed type 4 as the predominant pattern. In the upper right segment, the males showed 1^1 and females had type 3 as the predominant pattern. In the lower-left segment, type 5 in males and type 1^1 are the predominant patterns. In the lower middle segment, type 4 is the most common pattern in males,

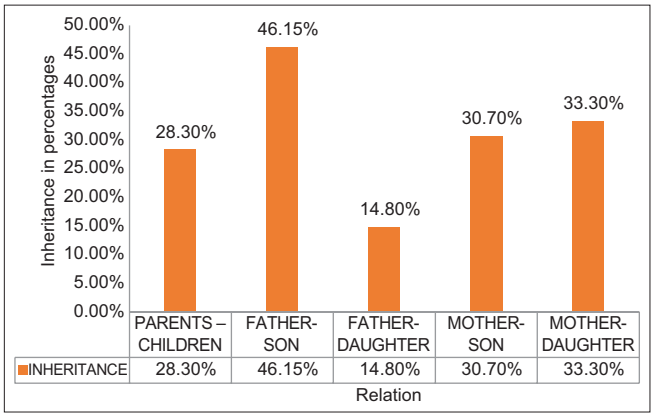

Graph 1: Lip pattern inheritance

whereas 1^1 is the most common pattern in females. In the lower right segment, both males and females exhibited 1^1 as the predominant lip pattern [Table 1].

Palm prints

In the entire study palm inheritance between parents and offspring for the right palm (60.2%) with father-son (66.6%), mother-daughter (48.8%), mother-son (63.6%), father-daughter (64.4%) and for the left palm (55.12%) with father-son (63.6%), mother-daughter (48.8%), mother-son (51.5%), father-daughter (57.7%) which are statistically insignificant [Graph 2]. Among siblings' variation of inheritance in the right palm (40%) and left palm (50%), a correlation was found between 1^1 in lips and category 5 of palms.

However, the mean palm ridge density was significantly higher among females than in males in all designated areas which is statistically insignificant [Table 2].

Downloaded from http://journals.lww.com/jpat by BhDMf5ePHKav1zEoum1tQfN4a+kJLhEZgbsIHo4XMi0hCywCX1AWnYQp/IlQrHD3i3D0OdRyi7TvSFl4Cf3VC1y0abggQZXdgGj2MwlZLeI= on 05/10/2023

Table 1: Gender dimorphism in lip patterns

Segments	UL	UM	UR	LL	LM	LR
Pattern in males	3 (41.6%)	5 (28.6%)	1[1] (26.0%)	5 (29.9%)	4 (37.7%)	1[1] (29.9%)
Pattern in females	3 (32.5%)	4 (28.9%)	3 (27.7%)	1[1] (38.6%)	1[1] (43.4%)	1[1] (39.8%)
Sig. (2-tailed)	0.145	0.108	0.661	0.309	0.020	0.640

*UL=upper left, UM=upper-middle, UR=upper right, LL=lower left, LM=lower middle, LR=lower right

Downloaded from http://journals.lww.com/jpat by BhDMf5ePHKav1zEoum1tQfN4a+kJLhEZgbsIHo4XMi0hCywCX1AWnYQp/IlQrHD3i3D0OdRyi7TvSFl4Cf3VC1y0abggQZXdgGj2MwlZLeI= on 05/10/2023



Figure 4: Principal lines and palm ridge densities markings in four areas. P1 – 5 mm × 5 mm square was placed on the central prominent part of the thenar eminence, the orientation of the square being normal. P2 – 5 mm × 5 mm square was placed medially to the proximal axial triradius on the hypothenar region with the lower vertex of the square placed on the proximal axial triradii. P3 – 5 mm × 5 mm square was placed on the medial mount proximal to the triradius of the second digit, and the uppermost vertex of the square was placed on the triradii of the second digit. P4 – 5 mm × 5 mm square was placed on the lateral mount proximal to the triradius of the fifth digit, and the uppermost vertex of the square was placed on the triradii of the fifth digit

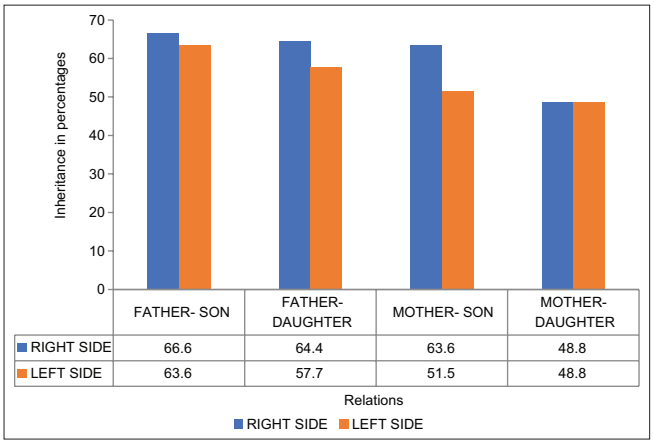

Graph 2: Palm category inheritance

DISCUSSION

Forensic odontology involves dentists in assisting legal and criminal issue investigations.[26] The moral responsibility of a dental surgeon is not only to diagnose and treat dental diseases but also dentist must have knowledge and awareness in forensic dentistry to help in investigating and identification at crime scenes.[14] Various approaches in forensic sciences include cheiloscopy, tooth prints, dermatoglyphics, bite marks, blood grouping, and DNA analysis, among which cheiloscopy and dermatoglyphics are unique in forensic sciences for the identification of individuals.[2,4-7]

Palmprints are more distinctive, reliable, and relatively a new biometric feature that contain more information than fingerprints in distinguishing the physiological characteristics between individuals and can easily be captured by low-resolution devices.[2,17] Lip prints can be potential evidence, especially in cases lacking other evidence like fingerprints.[1,27,28]

Our study depicted similarities of lip print patterns among parents and their offspring and is in accordance with other studies,[1,10] whereas, in one study, there were no similarities observed between parents and offspring in lip print patterns.[29]

Lip print inheritance

In 1932, Edmund Locard, the "French Sherlock Holmes," was the first to advocate the use of lip prints for personal

Table 2: Palm Ridge density

Area	Male		Female		Sig. (2-tailed)
	Mean	Standard deviation	Mean	Standard deviation	
P1	9.2569	2.40264	8.9107	2.21273	0.186
P2	10.2500	2.78984	10.6607	3.05994	0.219
P3	10.8819	2.61383	10.7083	2.59745	0.558
P4	10.2500	2.26713	9.8571	2.01576	0.106

*P1 (thenar eminence), P2 (hypothenar eminence), P3 (triradius of the second digit), and P4 (triradius of the fourth digit)

identification and criminality. Many investigators have studied these lip creases and grooves, confirming their uniqueness in each individual and implying forensic use.[13] McDonell confirmed that even identical twins who were indistinguishable in every other way had varying lip prints in the research carried out in 1972.[30] These wrinkles and grooves seen on lips have been named by Tsuchihashi as "sulci laborium ruborum."[13,14]

In the present study, the inheritance of lip prints between parents and offspring was 28.3%, whereas other studies have shown a resemblance with a range from 37.6% to 83.3%.[15,31] which could be due to no standardised segmentation of lips. In the present study, the author has adopted the model from Dongarwar *et al.* and Kautilya *et al.*[32,33] Even though the highest inheritance was found between father and son (46.15%), inheritance among the offspring (25%) was less when compared with a study by Augustine *et al.*[31] with a positive correlation among offspring in both studies.

Sexual dimorphism in lip prints

Gondivkar SM *et al.* have stated that lip patterns would help in predicting the gender with a high degree of accuracy.[2,34] In the present study, the predominant lip pattern in males and females was type 1^1 and was in accordance with several studies.[9,35,36]

Predominant lip pattern

Although few previous research studies have classified other types of lip patterns as predominant, type 1^1 was the most common in this study.[2,30,37-40]

Palm category inheritance

Palmprints include the following characteristics: The palmprint and fingerprint share the same essential parts. As a result, palmprints are one of a kind and will not alter over time. They can't be faked, and the palmprint is significantly larger than the fingerprint. Apart from their uniqueness and stability, palmprints have other properties (major palmar flexion creases, triradius), and certain geometric characteristics can be derived when palmprints are taken.[2]

Evidence indicates there is a strong genetic pattern in palmprint formation.[39,40] Within the findings of the present study, there is a genetic lineage in the inheritance of palm ridge patterns and the findings are in accordance with studies by Rajbongshi *et al.* and Temaj *et al.*[41,42]

Sexual dimorphism in palms

Even though Kanchan and Rastogi showed more ridge count in males, in our study, females showed more ridge count in all four designated areas than males, which is similar to the studies conducted by Gutiérrez-Redomero, Cummins.[43-46] These differences may be attributed to the larger average body proportions of men than women, as stated by Kanchan *et al.*[44]

Predominant Palm category

The predominant palm category in the study is 5 which is similar to other studies by Wu *et al.* and Fang *et al.*[2,18,47]

There are inheritance patterns among parents and siblings with considerable gender dimorphism in palm and lip segment patterns. To determine gender dimorphism, these lip patterns and palm ridges can be applied in forensic investigation.

Limitations

Further multicentric research with a large sample size, involving different races and ethnic groups, would help in establishing the importance of lip and palm inheritance and gender dimorphism in forensic investigations. A standard protocol for the segmentation of lips would help in getting a universal reliable result.

CONCLUSION

Cheiloscopy and dermatoglyphics have good potential in crime investigation due to their frequent presence at the crime scene. Lip prints and palmprints can be used as an adjuvant tool during investigations, especially when other conventional pieces of evidence are absent.

Acknowledgment

We thank the participants for their cooperation and participation during the entire study.

Ethical approval

The Institutional Ethics Committee approved the study protocol, with IEC No: IECVDC/2021/PG01/OP/IVV/03 on 17/02/2021.

Authors contributions

Rt and SP conceived and designed the study; Rt acquired the data; and SP and RM conducted data analysis and

Downloaded from http://journals.lww.com/jpat by BhDMf5ePHKav1zEoum1tQfN4a+kJLhEZgbsIHo4XMi0hCywCX1AWnYQp/IlQrHD3i3D0OdRyi7TvSFl4Cf3VC1y0abggQZXdgGj2MwlZLeI= on 05/10/2023

Downloaded from http://journals.lww.com/jpat by BhDMf5ePHKav1zEoum1tQfN4a+kJLhEZgbsIHo4XMi0hCywCX1AWnYQp/IlQrHD3i3D0OdRyi7TvSFl4Cf3VC1y0abggQZXdgGj2MwlZLeI= on 05/10/2023

interpreted the results. Rt and SP wrote the initial and final drafts of the manuscript, and RM, SA, SB, and YP provided logistic support. All authors drafted the manuscript and designed the tables with critical revisions. All authors discussed the results and commented on the manuscript. All authors have critically reviewed and approved the final draft and are responsible for the content and similarity index of the manuscript.

Financial support and sponsorship

Nil.

Conflicts of interest

There are no conflicts of interest.

REFERENCES

1. Venkatesh R, David M. Cheiloscopy : An aid for personal identification. J Forensic Dent Sci 2011;3:67.
2. Rekha VR. Heritability and Correlation of Lip Prints and Palmprints in South Kerala Population. Oral Maxillofac Pathol J 2015;6:544-9.
3. Srilekha N, Anuradha A, Vijay Srinivas G, Sabitha Devi D. Ticorrelation among lip print pattern, finger print pattern and abo blood group. J Clin Diagn Res 2014;8:49-51.
4. Harsha L, Jayaraj G. Correlation of lip print, finger print and blood groups in a Tamil Nadu based population. J Pharm Sci Res 2015;7:795-9.
5. Randhawa K, Narang RS, Arora PC. Study of the effect of age changes on lip print pattern and its reliability in sex determination. J Forensic Odontostomatol 2011;29:45-51.
6. Eboh DO. Fingerprint patterns in relation to gender and blood group among students of Delta State University, Abraka, Nigeria. J Exp Clin Anat 2013;12:82.
7. Murugan M, Karikalan T. A study of relative correlation between the pattern of finger prints and lip prints. J Evol Med Dent Sci 2014;3:12768-72.
8. Moshfeghi M, Beglou A, Mortazavi H, Bahrololumi N. Morphological patterns of lip prints in an Iranian population. J Clin Exp Dent 2016;8:e550-5.
9. Loganadan S, Dardjan M, Murniati N, Oscandar F, Malinda Y, Zakiawati D. Preliminary research: Description of lip print patterns in children and their parents among deutero-Malay population in Indonesia. Int J Dent 2019; 2019:7629146. doi: 10.1155/2019/7629146.
10. Dhall J, Kapoor A, Vats Y. Gender variation in morphological patterns of lip prints among some north Indian populations. J Forensic Dent Sci 2012;4:19-23.
11. Gupta S, Gupta K, Gupta OP. A study of morphological patterns of lip prints in relation to gender of North Indian population. J Oral Biol Craniofacial Res 2011;1:12-6.
12. George R, Nora Afandi NSB, Zainal Abidin SNHB, Binti Ishak NI, Soe HHK, Ismail ARH. Inheritance pattern of lip prints among Malay population: A pilot study. J Forensic Leg Med 2016;39:156-60.
13. Prabhu RV, Dinkar A, Prabhu V. A study of lip print pattern in Goan dental students-A digital approach. J Forensic Leg Med 2012;19:390-5.
14. Kumar LB, Jayaraman V, Mathew P, Ramasamy S, Austin RD. Reliability of lip prints in personal identification: An inter-racial pilot study. J Forensic Dent Sci 2016;8:178.
15. Astekar M, Kumar V, Kaur P, Singh N, Sidhu G, Devi A. The study of inheritance analysis and evaluation of lip prints in individuals. J Forensic Dent Sci 2015;7:49-53.
16. Tsuchihashi Y. Studies on personal identification by means of lip prints. Forensic Sci 1974;3:233-48.
17. Negi A, Negi A. The connecting link! Lip prints and fingerprints. J Forensic Dent Sci 2016;8:177.
18. Wu X, Zhang D, Wang K, Huang B. Palmprint classification using principal lines. Pattern Recognit 2004;37:1987-98.
19. Kong A, Zhang D, Kamel M. A survey of palmprint recognition. Pattern Recognit 2009;42:1408-18.
20. Andreenko E, Baltova S. Sexual dimorphism in dermatoglyphic traits and fluctuating asymmetry in Bulgarians from northeast Bulgaria. HOMO 2017;68:316-27.
21. Mittal M, Puri A, Gupta R. Dermatoglyphics and dental caries: A comparative study in sikh and non-sikh population. Indian J 2013;6:81-6.
22. Krishan K, Ghosh A, Kanchan T, Ngangom C, Sen J. Sex differences in fingerprint ridge density-Causes and further observations. J Forensic Leg Med 2010;17:172-3.
23. Jain AK, Feng J. Latent palmprint matching. IEEE Trans Pattern Anal Mach Intell. 2009;31:1032-47.
24. Moore SJ, Munger BL. The early ontogeny of the afferent nerves and papillary ridges in human digital glabrous skin. Dev Brain Res 1989;48:119-41.
25. O'Rahilly R. The timing and sequence of events in human cardiogenesis. Cells Tissues Organs 1971;79:70-5.
26. Barlow P. The influence of inactive chromosomes on human development-Anomalous sex chromosome complements and the phenotype. Hum Genet 1973;17:105-36.
27. Avon SL. Forensic odontology: The roles and responsibilities of the dentist. J Can Dent Assoc 2004;70:453-8.
28. Dineshshankar J, Ganapathi N, Yoithapprabhunath TR, Maheswaran T, Kumar MS, Aravindhan R. Lip prints: Role in forensic odontology. J Pharm Bioallied Sci 2013;5(Suppl 1):3-7.
29. Prabhu RV, Dinkar AD, Prabhu VD. Collection of lip prints as a forensic evidence at the crime scene-an insight. J Oral Health Res 2010;1.
30. Maheswari TNU, Gnanasundaram N. Role of Lip prints in Personal Identification and criminalization Keywords. 2021;12:1-15.
31. Augustine J, Barpande SR, Tupkari J V. Cheiloscopy as an adjunct to forensic indentication: A study of 600 individuals. J Forensic Odontostomatol 2008;26:44-52.
32. Vijay Kautilya D, Bodkha P, Rajamohan N. Efficacy of cheiloscopy in determination of sex among South Indians. J Clin Diagnostic Res 2013;7:2193-6.
33. Dongarwar GR, Bhowate RR, Degwekar SS. Cheiloscopy - Method of Person Identification and Sex Determination. Open Access Sci Reports. 2013;2:1-4.
34. Gondivkar S, Indurkar A, Degwekar S, Bhowate R. Cheiloscopy for sex determination. Journal of forensic dental sciences 2009. P. 56-60.
35. Bindal U, Bindal PG, Athikha N. Labial impressions : A tool for identification. J Forensic Res 2014;5:3.
36. Jeergal PA, Pandit S, Desai D, Surekha R, Jeergal VA. Morphological patterns of lip prints in Mangaloreans based on Suzuki and Tsuchihashi classification. J Oral Maxillofac Pathol 2016;20:320-7.
37. Rastogi P, Parida A. Lip prints–an aid in identification. Australian Journal of Forensic Sciences. 2011. P. 1-8.
38. Verma P, Sachdeva SK, Verma KG, Saharan S, Sachdeva K. Correlation of lip prints with gender, ABO blood groups and intercommissural distance. North American journal of medical sciences 2013;5:427.
39. Makaju S, Chaudhary S, Rai CK. Type I lip pattern in at least one quadrant among first and secondyear medical and dental students of a medical college: A descriptive cross-sectional study. J Nepal Med Assoc 2021;59:342-5.
40. Ahmed SA, Salem HE, Fawzy MM. Forensic dissection of lip print as an investigative tool in a mixed Egyptian population. Alexandria J Med 2018;54:235-9.
41. Rajbongshi A, Vishnupriya S, Rao PH, Pandit SNN. A study on heritability of pattern intensity index and asymmetry of digital dermatoglyphic pattern frequency in muslims of Assam. Indian J Hum Genet 2000;6:41-4.
42. Temaj G, Skarić-Jurić T, Tomas Z, Behluli I, Narančić NS, Sopi R, *et al*.

Qualitative dermatoglyphic traits in monozygotic and dizygotic twins of Albanian population in Kosovo. Homo 2012;63:459-67.
43. Kanchan T, Rastogi P. Sex determination from hand dimensions of north and south Indians. J Forensic Sci 2009;54:546-50.
44. Kanchan T, Krishan K, Aparna KR, Shyamsundar S. Is there a sex difference in palm print ridge density? Med Sci Law 2013;53:33-9.
45. Gutiérrez-Redomero E, Alonso C, Romero E, Galera V. Variability of fingerprint ridge density in a sample of Spanish Caucasians and its application to sex determination. Forensic Sci Int 2008;180:17-22.
46. Cummins H, Waits WJ, McQuitty JT. The breadths of epidermal ridges on the finger tips and palms: a study of variation. American journal of Anatomy. 1941 Jan;68(1):127-50.
47. Fang L, Leung MK, Shikhare T, Chan V, Choon KF. Palmprint classification. In2006 IEEE International Conference on Systems, Man and Cybernetics 2006 Oct 8 (Vol. 4, pp. 2965-2969). IEEE

Downloaded from http://journals.lww.com/jpat by BhDMf5ePHKav1zEoum1tQfN4a+kJLhEZgbsIHo4XMi0hCywCX1AWnYQp/IlQrHD3i3D0OdRyi7TvSFl4Cf3VC1y0abggQZXdgGj2MwlZLeI= on 05/10/2023