Wolters Kluwer Issue 03 • July-September 2022 • Volume 33 Medknow

IADR
International Association for Dental Research, USA

INDIAN SOCIETY FOR DENTAL RESEARCH
IADR- Indian Division

IJDR

Indian Journal of Dental Research

www.ijdr.in

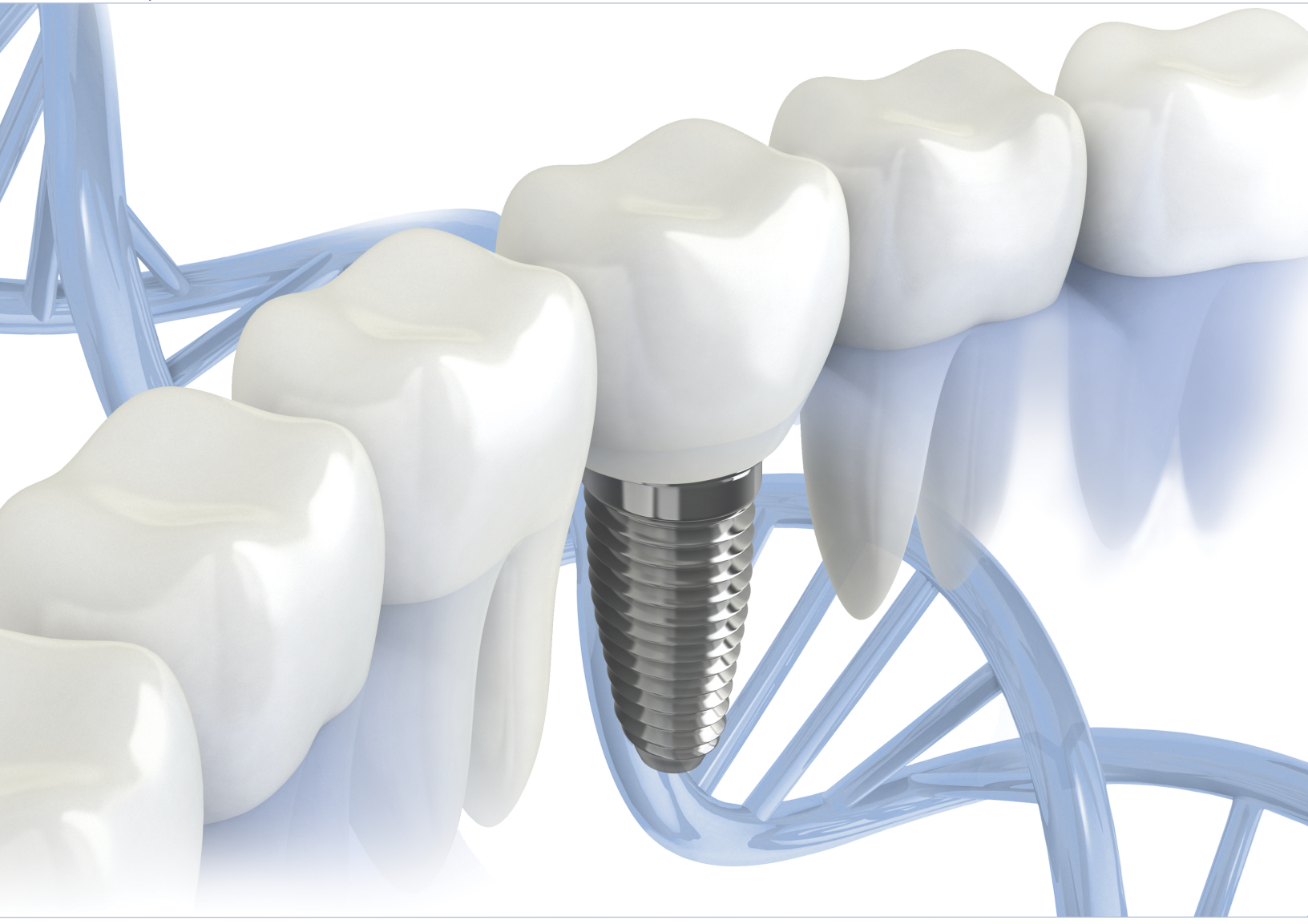

Official Publication of

Indian Society for Dental Research
www.isdrindia.com
International Association for Dental Research - Indian Division
www.iadr.com

Effectiveness of Molecular-Targeted Chemotherapy in Ameloblastomas: A Systematic Review

Abstract

Ameloblastoma is a benign, locally aggressive neoplasm that needs extensive surgical resection. The goal of this article is to obtain an in-depth review of benign ameloblastomas to determine the available level of evidence and the possible benefit of targeted therapeutics for the treatment of ameloblastoma and BRAF V600E mutation in ameloblastoma. An electronic literature search was conducted according to PRISMA guidelines in PubMed/MEDLINE, EBSCO, and Web of Science for eligible studies published between 1975 and 2021. The systematic review is registered with INPLASY (INPLASY202260018). The review included 2 case series and 17 case reports. The histopathological type, anatomic location, expression of BRAF mutation, additional mutations, and molecular-targeted therapies of the 19 reviewed articles were summarized and tabulated. Interestingly, the majority of the primary site of ameloblastoma was located in the mandible (80.9%) compared to the maxilla (17%). The tumour size was reported in nine of the included studies. Most of the included studies in the review exhibited ameloblastoma with BRAF V600E mutations and responded to molecular-targeted therapies. Molecular therapies employing BRAF and/or MEK inhibitors in ameloblastoma with BRAF V600E mutations proved to be an appropriate treatment based on the limited available evidence. It is essential further to deepen our understanding at the clinical and molecular level to enhance the precision of management of ameloblastoma.

Keywords: *BRAF V600E, MAID regimen, metastatic ameloblastoma, molecular-targeted therapy, pulmonary ameloblastoma*

Thuckanaickenpalayam R. Yoithapprabhunath, Kenniyan K. Srichinthu[1], Deepak Gupta[2], Diksha Singh[3], Swetha Pasupuleti[4], Ramdas M. Nirmal[5]

Department of Oral and Maxillofacial Pathology, Vivekanandha Dental College for Women, Tamil Nadu, [1]Department of Oral and Maxillofacial Pathology, KSR Institute of Dental Science and Research, Tamil Nadu, [2]Department of Oral Medicine and Radiology, M.M. College of Dental Sciences and Research, Mullana, Haryana, [3]Department of Oral and Maxillofacial Pathology, King George Medical College, Uttar Pradesh, [4]Department of Oral and Maxillofacial Pathology, Vishnu Dental College, Andhra Pradesh, [5]Department of Oral and Maxillofacial Pathology, Cuddalore Government Dental College and Hospital, Tamil Nadu, India

Address for correspondence:
Dr. Kenniyan K. Srichinthu, Associate Professor, Department of Oral Pathology and Microbiology, KSR Institute of Dental Science and Research, Tamil Nadu, India.
E-mail: drchinthu@ksridsr.edu.in

Received : 03-06-2022
Revised : 21-08-2022
Accepted : 27-08-2022
Published : 17-01-2023

Access this article online

Website: www.ijdr.in

DOI: 10.4103/ijdr.ijdr_456_22

Quick Response Code:

Introduction

Ameloblastoma is a benign odontogenic tumor that grows slowly. It contributes to about 1% of all jaw tumors and 9–14% of all odontogenic tumors emerging from odontogenic epithelial tissue involved during odontogenesis. The clinical presentation of ameloblastoma is non-specific and varies depending on the type and site of the tumor. It can further expand to profound sizes, leading to facial asymmetry, displacement/mobility of teeth, malocclusion, and pathologic fractures. Based on the clinical and histological aspects of ameloblastoma, there is still a lot of disagreement over the optimal treatment option. Till date, wide surgical resection is the only treatment of choice for ameloblastoma tumors, resulting in post-treatment compromised quality of life in the individuals. The treatment modality is the most important element in determining recurrence rates, which can range from 15 to 25% after radical surgery and 55 to 90% following conservative therapy. Ameloblastoma is associated with an impacted/unerupted tooth especially, the mandibular third molars in 15–40% of cases.[1,2]

The World Health Organization (WHO) (1991) defined ameloblastoma as a "benign but locally aggressive tumor with a high tendency to recur, consisting of proliferating odontogenic epithelium lying in a fibrous stroma." The hematogenous, lymphatic, and aspiration routes are the most typical ways of the progression of metastatic ameloblastoma which is benign. Previously metastatic ameloblastoma was termed as metastatic malignant ameloblastoma, where the appearance of well-differentiated or benign histology of ameloblastoma was found, while ameloblastic carcinomas are histologically malignant in both primary

This is an open access journal, and articles are distributed under the terms of the Creative Commons Attribution-NonCommercial-ShareAlike 4.0 License, which allows others to remix, tweak, and build upon the work non-commercially, as long as appropriate credit is given and the new creations are licensed under the identical terms.

For reprints contact: WKHLRPMedknow_reprints@wolterskluwer.com

How to cite this article: Yoithapprabhunath TR, Srichinthu KK, Gupta D, Singh D, Pasupuleti S, Nirmal RM. Effectiveness of Molecular-Targeted Chemotherapy in Ameloblastomas: A Systematic Review. Indian J Dent Res 2022;33:323-31.

and metastatic sites. The variants of benign ameloblastomas have been simplified and repositioned in the updated 2017 WHO classification.[2] Hypercalcemia is an uncommon complication of metastatic ameloblastoma that has been related to the release of a parathyroid-like substance. Chemotherapy and radiation are currently recommended for palliative care, and extensive surgeries, respectively, for ameloblastoma treatment. The aspiration of tumor cells during surgery is postulated to be the cause of pulmonary metastasis. Since there is a lack in the rhythmic correlation among signaling pathways of ameloblastoma pathogenesis, chemotherapy was contraindicated or minimally explored. Albeit chemotherapy is not curative, it has been reported that different regimens of Cisplatin, Adriamycin, Cyclophosphamide, Doxorubicin, Vinblastine, and Bleomycin show tumor regression and alleviate symptoms.[3,4]

The molecular basis of ameloblastoma is unknown and new molecular data are enhancing our knowledge of ameloblastoma pathology which may have relevant implications. The overexpression of the RAS–RAF–MAPK pathway is strongly allied with its pathology, through EGFR-mediated signalling or activating mutations in the BRAF gene. Neoadjuvant targeted therapy should be considered to reduce the necessity of extensive or repeated surgeries.[5]

Enucleation/curettage against surgical resection with wide margins is also a point of contention.[1] The potential importance of neoadjuvant molecular-targeted chemotherapy will be highlighted in this comprehensive study, notably as recurrences typically occur decades after initial therapy. The goal of this article is to obtain an in-depth review of benign ameloblastomas to determine the available level of evidence and the possible benefit of targeted therapeutics for the treatment of ameloblastoma and BRAF V600E mutation in ameloblastoma.

Methodology

Registration and protocol

The systematic review is registered with INPLASY (INPLASY202260018, DOI number—10.37766/inplasy2022.6.0018) and was carried out using PRISMA guidelines (Preferred Reporting Items for Systematic Reviews and Meta-Analyses).[6]

Search strategy and selection criteria

A comprehensive electronic retrieval of PubMed/Medline, EBSCO, and Web of Science databases for relevant published studies between 1975 and 2021 was performed. Benign ameloblastomas (Conventional, unicystic, peripheral, and metastatic ameloblastoma) were the several variants that were included in the review. The Booleans and/or were used along with the following terms: "ameloblastoma," "targeted therapy," "chemotherapy," "malignant," "metastasis," "BRAF V600E mutation," "associated mutations," "pulmonary," "relapse," or "recurrence."

The review also included additional references explored using the reference lists of selected studies, bibliography, and Google Scholar. The PRISMA flowchart for literature screening and selection of studies included in the review is shown in Figure 1. The studies containing relevant information were obtained for full-text review after titles and abstracts were screened. Restricted access papers were retrieved using institutional support.

Eligibility criteria

The authors employed the population–intervention–comparator–outcome–study design paradigm to determine the eligible studies. The parameters were kept as broad as possible to optimize the search. The following were the details of the a priori criteria:

Population: Studies with human subjects, with no limits on age or other demographics.

Intervention and comparator: Studies with data that was clearly linked to targeted therapies for ameloblastoma, BRAF V600E mutations, and related mutations. Vaccines and herbal medications were not included. Studies were included only when the name and dosage of the targeted medication regimen utilized in the therapy were disclosed. There was no need for a comparator group.

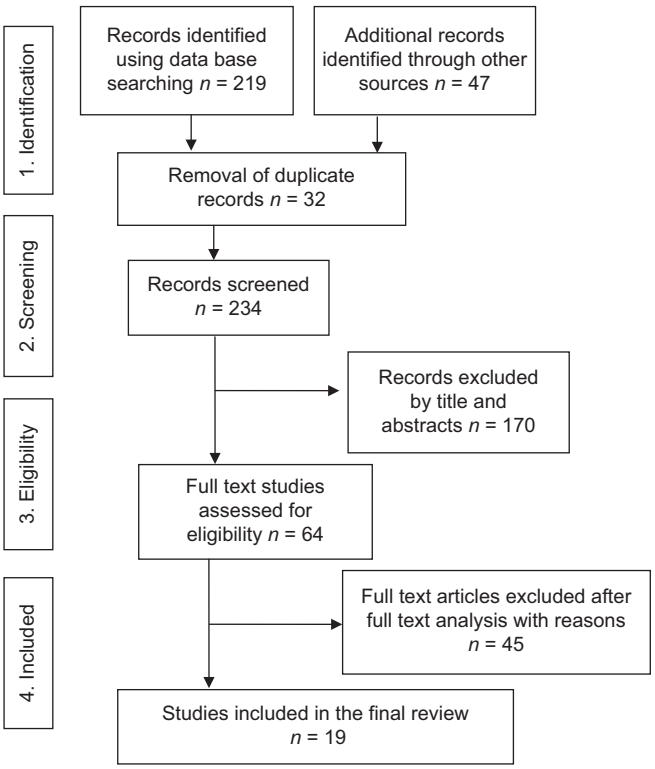

Figure 1: PRISMA flowchart of the included studies (Adapted from Preferred Reporting Items for Systematic Reviews and Meta-analyses 2009 Flow Diagram)

Outcomes: We included only those studies of benign ameloblastomas (intraosseous, extraosseous, unicystic, and metastasizing ameloblastoma) reporting the potential use of neoadjuvant targeted therapies. Studies reporting only the tumor size, prevalence, growth of ameloblastic carcinoma, *in vitro* cell growth, or molecular investigations were excluded.

Study design: The reviewers only looked at works that had been published or translated into English. Case reports and case series available in the full text were included even if they extracted the minimum dataset, including tumor site, histological confirmatory diagnosis, and treatment, due to the paucity of published articles relevant to targeted therapies. Exclusions included systematic reviews, meta-analyses, *in vitro* research, animal experiments, and abstracts from conferences.

Data extraction

Data retrieved were compiled in Microsoft Excel using an extraction template that was evaluated by two users on a sample of five random case reports before being updated as needed. The data was gathered to determine the level of evidence, research quality, and outcome details. Each of the papers included in the review was evaluated critically based on the design and content of the case reports. For data extraction, we used the reported diagnosis and recognized ameloblastoma as a malignant entity that matched our inclusion criteria if there is metastasis or had histologic atypia, even though these markers are inadequate for a confirmed diagnosis of malignancy.

Data synthesis and quality assessment

Each of the retrieved full-text publications was screened and evaluated independently by the two authors. The evidence-based librarianship Critical Appraisal Checklist was used by the two reviewers to ensure the quality of the selected studies.[7] Disagreements between the data were examined and resolved by a blinded reviewer to establish concordance. Table 1 illustrates the characteristics of the cases reported and considered in the review.

A tool for assessing the methodological quality of case reports/series to be included in a systematic review was employed.[27] Histological diagnosis and detailed disclosure of drug dosage were included in this broad explanatory inquiry of the tool, which is analogous to the detailed criteria we employed during the study selection process. Hence, we chose not to undertake a separate risk of bias evaluation because the items in the tool were most relevant to assessing methodological quality, and this context had already been reviewed and accounted for.

Results

The initial literature search yielded 219 papers with a manual search generating an additional 47 studies.

Table 1: Summary of characteristic features of the included studies

Author, Year	Ethnicity	Gender	Age of diagnosis of primary tumour (Years)	Primary tumour site
*Van Dam *et al*., 2010[8]	6 Caucasians, 5 African American, 3 Asian, 13 unknown	M/F - 12/14 (1 unknown)	Mean age 30	Mandible (21 cases), 5 in maxilla and 1 unknown; 9 plexiform, 7 follicular, 4 plexiform and follicular, 1 acanthomatous, 6 unknown
*Hirschhorn *et al*., 2021[9]	Israeli	Males (3 pediatric cases)	Mean age 13	Unicystic (mural) Mandibular AME
Gall et al., 1975[10]	Caucasian	Male	45	Right mandible
Eliasson *et al*., 1989[11]	Caucasian	Female	40	Right maxilla
Tan *et al*., 2016[12]	Caucasian	Male	85	Left mandible - follicular and plexiform
Valkadinov *et al*., 2017[13]	Caucasian	Female	43	Left mandible
Yang *et al*., 2015[14]	Chinese	Male	64	Right mandible
Faden DL, Algazi A. 2017 [15]	California	Female	83	Left mandible
Fernandes *et al*., 2018[16]	Brazilian	Female	29	Left mandible
Brunet *et al*., 2019[17]	Caucasian	Female	26	Right mandible
Lanham *et al*., 1987[18]	Caucasian	Male	36	Left maxilla
Ramadas *et al*., 1990[19]	Dravidian	Female	17	Left mandible
Kaye *et al*., 2015[20]	African-American	Male	40	Left mandible
Ghiam *et al*., 2013[21]	Caucasian	Male	47	Left mandible
Broudic-Guibert *et al*., 2019[22]	Caucasian	Female	33	Left mandible - Plexiform
Grunwald e*et al*., 2001[23]	Caucasian	Female	28	Left maxilla - Desmoplastic
Campbell et al., 2003 (24)	Caucasian	Male	46	Left mandible - follicular AME
Amzerin et al., 2011 (25)	Moroccon	Male	24	Right Mandible
Li et al., 2019 (26)	Chinese	Female	28	Left mandible

*Case series; AME-Ameloblastoma.

Following the removal of duplicates (n = 32), the titles and abstracts of 234 papers were reviewed by two reviewers to confirm that they met the eligibility criteria. The papers were included for full-text review if there was any ambiguity at this point. Around 170 articles were excluded because they were irrelevant, and 64 articles were subjected to a full-text review. Any conflicts about inclusion/exclusion were addressed through consensus discussion and the guidance of a third reviewer, who ultimately made the decision. A good concordance of the kappa coefficient (k = 0.86) was obtained. Full text not accessible (n = 7), no therapeutic information (n = 8), conference abstract only (n = 3), minimal clinical information (n = 6), solely molecular studies (n = 5), prevalence studies (n = 14), and *in vitro* or animal studies (n = 2) were the reasons for the exclusion of 45 studies. Thus, the systematic review comprised a total of 19 papers.

This review included 2 case series[8,9] and 17 case reports.[10-26] The tumor size, pathogenesis, previous treatment, expression of BRAF mutant, the regimen of adjuvant molecular therapy, and the outcome of these 19 reviewed articles were tabulated in Tables 2 and 3. The studies included 47 patients, (comprising 23 males, 23 females and 1 gender was not specified) with an average age of 39.84 years (range 13–85 years). Interestingly, the majority of the primary site of ameloblastoma was located in the mandible (80.9%) compared to the maxilla (17%). Maxillary ameloblastoma was reported in three of the case report[11,18,23] and one case series.[8] The tumor size was presented in nine of the reports.[9,10,12-17,19] In one patient, the gender and location of the original tumor were not disclosed.[8]

Histopathological diagnosis

Only six of the included studies[8,9,12,22-24] revealed the variations with histological features such as unicystic mural type, follicular, plexiform, acanthomatous, and desmoplastic ameloblastoma. The ability to anticipate the likelihood of metastasis relying solely on histological findings is still debatable.[24]

Recurrence and metastatic site

According to the studies included, recurrence or metastasis could occur anywhere from 5 months to 25 years. Nearly all of the studies in this review revealed pulmonary metastasis. Van Dam *et al*. and Ghiam *et al*. reported hypercalcemia in their respective reports.[8,21] Fernandes *et al*.[16] reported cavernous sinus metastasis and orbital extension. Li *et al*.[26] documented cases of metastasizing ameloblastoma, metastases to the lungs and brain. Eliasson *et al*.[11] found metastases in the right mandible, base of the skull, right orbit, preauricle, and lungs. Grunwald *et al*.[23] revealed a local recurrence with the invasion of the ethmoid bone, left orbit, and right medial maxillary cavity, as well as several lung relapses.

Treatment

The included studies in the review established that the patients with recurrent/metastasizing ameloblastoma were treated with emerging molecular treatment strategies. Six studies employed monotherapy,[9,12,15,16,22,24] whereas 13 used combination chemotherapy.[8,10,11,13,14,17-21,23,25,26] After a treatment time ranging from 11 weeks to 5 years, the majority of cases demonstrated considerable regression and improvement in symptoms. Fifteen studies revealed a partial response to therapeutic strategies.[8-11,13,15,16,18,19,21-26] Broudic-Guibert *et al*., Amzerin *et al*., and Li *et al*. used response evaluation criteria in solid tumor (RECIST) criteria to report the treatment response.[22,25,26] Brunet *et al*.[17] reported a complete response using both the RECIST and PET response criteria in solid tumor (PERCIST) criteria. Complete response was also reported by Tan *et al*., Yang *et al*., and Kaye *et al*.[12,14,20] The tumor was found to be resistant to chemotherapy by Gall *et al*. and Lanham *et al*.[10,18]

Tan *et al*. described a case in which molecular-targeted adjuvant chemotherapy resulted in a 90% reduction in tumor growth after 16 weeks.[12] Hirschhorn *et al*.[9] found that pre-surgery treatment with Dabrafenib, a BRAF inhibitor, produced significant tumor reduction, allowing for non-mutilating total surgical resection, bone regeneration, and organ retention. These studies suggested that molecular-targeted neoadjuvant chemotherapy for ameloblastoma could be effective in specific clinical scenarios, such as when surgical approaches are initially limited owing to the extensive tumor size. Thus, based on the evidence from the studies reviewed, targeted therapeutic drugs such as BRAF and/or MEK inhibitors exhibit promising outcomes in the treatment of ameloblastoma with BRAF V600E mutations.

Associated mutations

The expression of the BRAF V600E mutant was identified in 9 out of 19 reports.[8,9,12,13,15-17,20,26] Despite the fact that BRAF mutations were the most common, two of the studies included in this review identified additional mutant variations.[13,26] Using immunohistochemistry, Valkadinov *et al*.[13] confirmed the expression of cytokeratin subtypes (CK5/6/19) without the expression of Thyroid Transcription Factor 1. Li *et al*.[26] used whole exon detection by next-generation sequencing to detect somatic mutations, germline mutations, microsatellite instability, and tumor mutation frequency in metastasizing ameloblastoma. BRAF, MYCN, MLL2, ARIDIA, RUNX1, and ASXL1 were among the somatic mutations reported.

Discussions

The variants of ameloblastoma have been simplified in the updated 2017 WHO classification to conventional, unicystic, extraosseous/peripheral, and metastasizing types. Metastasizing ameloblastoma is distinguished from ameloblastoma by the presence of distant metastasis,

Table 2: Summary of outcome of the targeted therapies employed in various case studies

Author year	Tumour size	Course of the disease	Previous treatment	Mutation detected	Targeted therapy	Outcome
*Van Dam *et al*., 2010[8]	NS	The primary recurrence per patient ranged from 0 to 11 (average 4) with pulmonary metastasis (21 cases). Hypercalcemia noted	14 cases (61%) were treated by enucleation and curettage. 9 (39%) tumors were treated by surgical resection. Unspecified in 4 reports.	---	Gemcitabine and Carboplatin	PR and disease stabilization noticed
*Hirschhorn *et al*., 2021[9]	Mean size of 9 cm3	Treatment with BRAF inhibiting agents, priori surgery resulted in substantial tumor regression, allowing for non-mutilating complete surgical removal, bone regeneration, organ preservation	Radical surgery consisting of complete resection of the mandibular ramus and body, disarticulation of the temporomandibular joint followed by reconstruction	BRAF V600E	Dabrafenib (pediatric dose of 4.5 mg/kg/day bid)	Fever, rash, nausea reported during early days. Mean follow-up period was 31 months, during which all patients were disease-free.
Gall *et al*., 1975[10]	2 x 1.5 x 1 cm	Pulmonary metastasis 4 years after surgery	Segmental resection and mandibular reconstruction	---	2 cycles of Cyclophosphamide (2000-2500 mg/m^2 i.v.), 2 cycles of Methotrexate (100-120 mg/m^2 i.v.), 4 cycles of Adriamycin (90-100 mg/m^2, i.v.)	No measurable tumour regression noted with any of the drugs. Symptomatic improvement was noticed with Adriamycin
Eliasson *et al*., 1989[11]	NS	Local recurrence 19 months after surgery and lung metastasis 8.5 years later	Surgical resection and RT	---	6 one-week course of Vinblastine 4 mg/m^2, Cisplatin 60 mg/m^2, Bleomycin (392 units), Methotrexate 40 mg/m^2	PR noted
Tan *et al*., 2016[12]	5.5 x 3.5 x 3.2 cm	Tumor recurrence and pathological fracture	Surgical resection	BRAF V600E (PCR allele- specific)	Dabrafenib 150 mg PO twice daily	Development of actinic keratosis on face, back, scalp and thickening of voice. Follow up for 16 wk, tumor size decreased notably
Valkadinov *et al*., 2017[13]	31-48 mm (CT scan)	Lung metastasis after 10 years of surgical resection.	Surgical resection with RT	expression of CK5/6 and CK19 with no expression of TTF1 by IHC	6 cycles of Cisplatin 100 mg/m^2 on day 1, 5-Fluorouracil 1000 mg/m^2/day on day 1-4 (3 wk), and pegylated filgrastim	Underwent only two cycles of CT as she developed severe hematological toxicity
Yang 2015[14]	5×5.6cm (mandibular region) 6.2×4.3 cm (lung)	Local recurrence 10-years after surgery.	Surgical resection+ reconstruction	negative staining for CK, P63, TTF-1, CK7, CK8 and Wapsin A by IHC	6 cycles of Cyclophospha- mide 750 mg/m^2 on day 1, Pirarubicin 50 mg/m^2 day 1, and Cisplatin 75 mg/m^2 over 1-hour infusion (days 1 to 3), IV every 21 days.	The tumor tissues in right lung reduced significantly with CR

Contd...

Table 2: Contd...

Author year	Tumor size	Course of the disease	Previous treatment	Mutation detected	Targeted therapy	Outcome
Faden DL, Algazi A. 2017[15]	3.79×5.87 × 5.62 cm	Two recurrences, unsuitable for Surgery	Conservative surgery	BRAF V600E	Dabrafenib 75 mg twice daily	Follow up for 12 weeks; the tumour decreased in size
Fernandes *et al*., 2018[16]	1.3×0.9 cm (residual tumor)	Tumor recurrence by conservative surgery for 16 yr, metastases in cavernous sinus and tumor extension to orbit	Surgical resection and RT	BRAF V600E (PCR allele- specific)	Vemurafenib 960 mg PO twice daily and analgesic	Decrease in tumour size with anorexia, nausea and fatigue. Follow up for 11 week; asymptomatic with treatment tolerance
Brunet *et al*., 2019[17]	NS	Tumor recurrence after 13 years	Surgical resection	BRAF V600E	Dabrafenib (150mg BID) combined with Trametinib (2mg QD)	CR based on RECIST and PERCIST criteria 30 weeks after treatment initiation.

*Case series; AME - Ameloblastoma; PR - Partial response; CR - Complete response; IV - Intravenous; CT - Chemotherapy; RT - Radiotherapy

regardless of the fact that both have benign histology. The rate of metastasis has been estimated to be around 2%. It also tends to recur several years following the conservative approach, apparently owing to the lack of margin control of the tumors with these techniques.[7] In about 80% of cases, the lungs are compromised. Regional lymph nodes, pleura, vertebra, skull, diaphragm, liver, and parotid gland are some of the other common locations. The time between a tumor diagnosis and the manifestation of metastasis is often long, ranging from 10 to 12 years on average. After metastases, the median survival period varies from 3 months to 5 years, with the highest documented survival time being 37 years.[3-5]

In the pathophysiology of ameloblastoma, recent genetic investigations have demonstrated recurrent somatic and activating mutations in the MAPK and Sonic hedgehog signaling pathways. The BRAF, RAS, and fibroblast growth factor receptor 2 (FGFR2) genes are affected by MAPK pathway mutations. BRAF is a serine/threonine-protein kinase that enhances cell proliferation, survival, and neoplastic transformation by stimulating downstream signaling. The BRAF V600E mutation causes a valine to glutamate substitution at codon 600, and the mutation was found in 43–82% of the tumors evaluated in the literature.[5]

Treatment options are influenced by several parameters, including the patient's age, gender, tumor size and location, imaging results, histologic subtypes, maxillo-mandibular morphology, and disease curability, making treatment decisions challenging. Conventional ameloblastomas in the mandible and maxilla are often treated by a segmental excision followed by immediate or delayed bone reconstruction. Recurrent ameloblastomas are difficult to treat, notably if it recurs in an anatomical location with limited access to surgeries or due to delayed diagnosis. Maxillary ameloblastoma is more invasive clinically in terms of disease extent and recurrence than its mandibular analog, as the maxillary bone is weaker and provides only a flimsy wall of resistance against the local spread. If the tumor extends into vital structures such as the skull base, orbit, and paranasal sinuses, resection might be challenging. Metastatic ameloblastoma is relatively uncommon, and there is presently no standard treatment regimen established. It can spread to the lungs and cervical lymph nodes, despite its benign nature.[1,28]

BRAF mutations are the first sign of a high-frequency oncogenic mutation in benign ameloblastomas.[5] The main advantage of molecular-targeted therapy is that it can reduce surgical morbidity in resection, recurrence, and metastasis. Drugs that suppress the actions of mutant BRAF and MEK have the potential to be utilized in molecular-targeted treatments on benign ameloblastomas. The mutated BRAF genes are inhibited by Vemurafenib and Dabrafenib; the mutation MEK gene is inhibited by Trametinib; the mutated FGFR2 genes are inhibited by Ponatinib and Regorafenib. Three molecular targeted therapy for BRAF V600E mutation have been approved by the US Food and Drug Administration: Vemurafenib, and Dabrafenib for BRAF mutations and Trametinib for BRAF, and MEK mutations.[28]

Gall *et al*.[10] studied the effects of Cyclophosphamide, Methotrexate, and 5-Fluorouracil therapy in pulmonary metastases, 9 years after commencing the treatment. He noted a positive functional outcome, despite the absence of an objective improvement. After 13 cycles of combined

Table 3: Summary of outcome of the targeted therapies employed in various case studies

Author year	Tumour size	Course of the disease	Previous treatment	Mutation detected	Targeted therapy	Outcome
Lanham 1987[18]	NS	Recurrent AME with pulmonary metastasis after 24 years of surgery	Radical resection	----	2 cycles of Doxorubicin 60mg/m^2, 4 cycles of Cisplatinum 60 mg/m^2, 2 cycles of Cyclophosphamide 1000 mg/m^2, 4 cycles of Dacarbazine 650-1000 mg/m^2, 7 cycles of 5-Fluorouracil 12-15 mg/m^2	The tumour was resistant to CT
Ramadas *et al*., 1990[19]	10 × 8 cm	Multiple pulmonary metastasis 20 years after surgery	Surgical resection	---	Cisplatin (100 mg/m^2), Adriamycin (50 mg/m^2), and Cyclophosphamide (800 mg/m^2) administered on the same day and were repeated at 3-weeks intervals	Good clinical and radiological response documented
Kaye *et al*., 2015[20]	NS	Three recurrences (13, 9, 7 yr), surgical resection (two recur- rences), RT (last recurrence), neck bilateral and lung metastasis	Surgical resection and RT	BRAF V600E (gene profile and IHC)	Dabrafenib 150mg twice daily + Trametinib 2 mg once daily	The tumour size decreased in the first four days and followed up for 20 weeks; the tumor responded to treatment, without toxicity
Ghiam *et al*., 2013[21]	7.6 × 7.3 cm (right lung), 7.4 × 8.2 cm (left lung)	Tumour recurrence with extensive pulmonary metastases 21 years after the primary surgery. Hypercalcemia noted	Surgical resection with reconstruction	--	6 cycles of Carboplatin, Paclitaxel	Disease stabilisation and long-term PR observed with Grade 2 peripheral neuropathy and mild nausea/vomiting
Broudic-Guibert *et al*., 2019[22]	NS	AME diagnosed 31 years ago with relapse 11 years after surgery. Reported lung metastasis 19-years ago	Surgical resection	BRAF V600E	Initially Vemurafenib 960 mg bid tapered to 480 mg bid later	After 26 months of follow-up revealed a marked improvement in respiratory function with a decreased dyspnea (RECIST criteria)
Grunwald *et al*., 2001[23]	NS	A local relapse with infiltration of the ethmoid bone, left orbit and right medial maxillary cavity occurred 5 months after surgery followed by multiple relapse and lung lesions	Subtotal resection of the left maxilla, partial orbital resection and resection of the ethmoid and sphenoid bones followed by RT	---	1st line: 5- Cisplatin 80 mg/m^2 on day 1, Fluorouracil 1000 mg/m^2 on day 1-5 every 4 weeks 2nd line: Paclitaxel 175 mg/m^2 (IV), Carboplatin AUC5 (IV) four weekly cycles	No objective response after two courses of treatment in the 1st line therapy. A total of nine consecutive cycles of 2nd line therapy, achieved a PR
Campbell *et al*., 2003[24]	NS	Pulmonary AME 25 years after surgery	Surgical resection and reconstruction	---	Cyclophosphamide, 50mg three times/day; reduced to 50mg bid due to neutropenia after 2 years	A noted radiological improvement after a 5-year course

Contd...

Table 3: Contd...

Author year	Tumour size	Course of the disease	Previous treatment	Mutation detected	Targeted therapy	Outcome
Amzerin *et al*., 2011[25]	NS	Local recurrence after 5 years of primary surgery. Multiple lung metastasis after 2 years.	Surgical resection and RT	---	Doxorubicin 50 mg/m^2 and Cisplatin 100 mg/m^2	Based on RECIST criteria, local stabilization and PR of the lung lesions (30%) noted after 6 cycles of CT
Li *et al*., 2019[26]	NS	Local recurrence after 3-years of surgery and brain metastasis was observed. 5 years later MA was detected by IHC in the bilateral pulmonary nodules and mediastinal lymph nodes	Surgical resection with Stereotactic body radiotherapy	BRAF V600E, MLL2, ARIDIA, ASXL1, RUNX1, MYCN	Adriamycin (50mg/m^2), Ifosfamide (7500mg/m^2), and Dacarbazine (1000mg/m^2), administered IV for 72 hours/3 weeks. Mesna (2500 mg/m^2) IV 96 hours/3 weeks	PR after the 6 cycles of MAID and no evidence of progression was observed. The progression-free survival was more than 9 months (RECIST criteria)

*Case series; AME - Ameloblastoma; PR - Partial response; CR - Complete response; IV - Intravenous; CT - Chemotherapy; RT - Radiotherapy; NS - Not Specified

treatment with Cisplatin, and Cyclophosphamide for lung metastases, Ramadas *et al*.[19] achieved a partial response. Chemotherapy, including Doxorubicin, Cyclophosphamide, Bleomycin, 5-Fluorouracil, and Dacarbazine, failed to exhibit antitumoral effect by Lanham[18] In contrast, other treatments, such as Vinblastine, Bleomycin, Paclitaxel, and Carboplatin, have been proved to elicit tumor regression.[8,11,21,23] Chemotherapy may aid non-surgical patients to improve their clinical symptoms. The role of systemic chemotherapy in this unusual entity can only be evaluated with continual reporting of empirical case-based data. Because of the limited incidences, there is barely a little expertise in this context.[29]

While resection minimizes the chances of tumor recurrence, it affects the functional and aesthetic consequences resulting in post-treatment compromised quality of life in the diseased individuals. A donor site for rehabilitation may also be required. As a result, there are debates on the appropriate treatment option.[30] In addition, as our insights into the molecular etiology of ameloblastoma evolve, targeted drugs with fewer systemic adverse effects may prove to be more effective than standard chemotherapeutic protocols.[29] Although some claim that ameloblastoma may not react to these targeted therapies, the causal molecular processes may be extremely susceptible to targeted therapy.[5]

According to Shi *et al*.,[28] dual-agent molecular targeted chemotherapy for metastatic ameloblastoma appears to be preferable. The downside of BRAF inhibitor-based molecular-targeted therapy is that emergence of resistance might evolve quickly. Dual-agent inhibitor chemotherapy, which combines a BRAF and MEK inhibitor, has been observed to defer the acquired resistance. There is certainly no evidence comparing the efficacy of single-agent against dual-agent inhibitor targeted therapy in the treatment of benign ameloblastomas.

Conclusion

A synthesis of current knowledge of innovative molecular targeted therapeutics was presented in this review. Molecular-targeted therapy employing BRAF and/or MEK inhibitors in ameloblastoma with BRAF V600E mutations proved to be an appropriate treatment based on the limited evidence available. It is essential further to deepen our understanding at the clinical and molecular level to enhance the precision of the management of ameloblastoma. Recent advancement in molecular studies will lead us into the era of non-surgical treatment approach for ameloblastoma in the immediate-future.

Abbreviations

IHC: Immunohistochemistry
PCR: Polymerised chain reaction
BRAF: B Raf proto oncogene, serine/threonine kinase
EGFR: Epidermal growth factor receptor
RAS: Rat sarcoma virus
RAF: Rapidly Accelerated Fibrosarcoma
MAPK; Mitogen activated protein kinase
MEK: Mitogen activated protein kinase
SHH: Sonic hedgehog
FGFR2: Fibroblast growth factor receptor 2
MAID: Mesna, doxorubicin, ifosfamide, and dacarbazine
MYCN: Member of the Myc family of oncogenes
ARID1A: AT-rich interactive domain-containing protein 1A
RUNX1: Runt-related transcription factor 1
ASXL1: Additional sex combs like-1

Financial support and sponsorship

Nil.

Conflicts of interest

There are no conflicts of interest.

References

1. Chae MP, Smoll NR, Hunter-smith DJ, Rozen W. Establishing the natural history and growth rate of ameloblastoma with implications for management: Systematic review and meta-analysis. PLoS One 2015;10:e0117241.
2. Yoithapprabhunath TR, Nirmal RM, Ganapathy N, Mohanapriya S, Renugadevi S, Aravindhan R, *et al*. Meta-terminology of ameloblastoma. J Pharm Bioall Sci 2019;11:S140-5.
3. Larrañaga JJ, Sahovaler A, Picco P, Mazzaro E, Figari M. Management issues in the treatment of an ameloblastoma with an atypical presentation. craniomaxillofac Trauma Reconstr 2015;8:257-61.
4. Dissanayake R, Jayasooriya P, Siriwardena D, Tilakaratne W. Review of metastasizing (malignant) ameloblastoma (METAM): Pattern of metastasis and treatment. Oral Surg Oral Med Oral Pathol Oral Radiol Endod 2011;111:734-41.
5. Kurppa KJ, Catón J, Morgan PR, Ristimäki A, Ruhin B, Kellokoski J, *et al*. High frequency of BRAF V600E mutations in ameloblastoma. J Pathol 2014;232:492-8.
6. Page M, McKenzie J, Bossuyt P, Boutron I, Hoffmann T, Mulrow C. The PRISMA 2020 statement: An updated guideline for reporting systematic reviews. BMJ 2021;372:n71.
7. Glynn L. A critical appraisal tool for library and information research. Libr Hi Tech 2006;24:387-99.
8. Van Dam SD, Unni KK, Keller EE. Metastasizing (malignant) ameloblastoma: Review of a unique histopathologic entity and report of Mayo Clinic experience. J Oral Maxillofac Surg 2010;68:2962-74.
9. Hirschhorn A, Campino GA, Vered M, Greenberg G, Yacobi R, Yahalom R, *et al*. Upfront rational therapy in BRAF V600E mutated pediatric ameloblastoma promotes ad integrum mandibular regeneration. J Tissue Eng Regen Med 2021;15:1155-61.
10. Gall JA, Sartiano GP, Shreiner DP. Ameloblastoma of the mandible with pulmonary metastasis. Oncology 1975;32:118-26.
11. Eliasson M, Moser M, Tenholder C. Diagnosis and treatment of metastatic ameloblastoma. South Med J 1989;82:1165-8.
12. Tan S, Pollack JR, Kaplan MJ, Colevas AD, West RB. BRAF inhibitor treatment of primary BRAF-mutant ameloblastoma with pathologic assessment of response. Oral Surg Oral Med Oral Pathol Oral Radiol 2016;122:e5-7.
13. Valkadinov I, Conev N, Dzhenkov D, Donev I. Rare case of ameloblastoma with pulmonary metastases. Intractable Rare Dis Res 2017;6:211-4.
14. Yang RN, Wang XS, Ren J, Xie YF, Zhou D, Ge DF, *et al*. Mandible ameloblastoma with lung metastasis: A rare case report. Int J Clin Exp Pathol 2015;8:6793-9.
15. Faden DL, Algazi A. Durable treatment of ameloblastomawith single agent BRAFi Re: Clinical and radiographic response with combined BRAF-targeted therapy in stage 4 ameloblastoma. J Natl Cancer Inst 2017;109:1-2. doi: 10.1093/jnci/djw190.
16. Fernandes GS, Girardi DM, Bernardes JPG, Fonseca FP, Fregnani ER. Clinical benefit and radiological response with BRAF inhibitor in a patient with recurrent ameloblastoma harboring V600E mutation. BMC Cancer 2018;18:1-5.
17. Brunet M, Khalifa E, Italiano A. Enabling precision medicine for rare head and neck tumors: The example of BRAF/MEK targeting in patients with metastatic ameloblastoma. Front Oncol 2019;9:1-3. doi: 10.3389/fonc. 2019.01204.
18. Lanham R. Chemotherapy of Metastatic Ameloblastoma: A case report and review of the literature. Oncology 1987;44:133-4.
19. Ramadas K, Jose C, Subhashini J, Chandi SM, Viswanathan FR. Pulmonary metastases from ameloblastoma of the mandible treated with cisplatin, adriamycin, and cyclophosphamide. Cancer 1990;66:1475-9.
20. Kaye FJ, Ivey AM, Drane WE, Mendenhall WM, Allan RW. Clinical and radiographic response with combined BRAF-targeted therapy in stage 4 ameloblastoma. J Natl Cancer Inst 2014;107:378.
21. Ghiam AF, Al Zahrani A, Feld R. A case of recurrent metastatic ameloblastoma and hypercalcaemia successfully treated with carboplatin and paclitaxel: Long survival and prolonged stable disease. Ecancermedicalscience 2013;7:1-5. doi: 10.3332/ecancer. 2013.323.
22. Broudic-Guibert M, Blay JY, Vazquez L, Evrard A, Karanian M, Taïeb S, *et al*. Persistent response to vemurafenib in metastatic ameloblastoma with BRAF mutation: A case report. J Med Case Rep 2019;13:1-4. doi: 10.1186/s13256-019-2140-6.
23. Grunwald V, Le Blanc S, Karstens J, Weihkopf T, Kuske M, Ganser A, *et al*. Metastatic malignant ameloblastoma responding to chemotherapy with paclitaxel and carboplatin. Ann Oncol 2001;12:1489-91.
24. Campbell D, Jeffrey RR, Wallis F, Hulks G, Kerr KM. Metastatic pulmonary ameloblastoma: An unusual case. Br J Oral Maxillofac Surg 2003;41:194-6.
25. Amzerin M, Fadoukhair Z, Belbaraka R, Iraqui M, Boutayeb S, M'Rabti H, *et al*. Metastatic ameloblastoma responding to combination chemotherapy: Case report and review of the literature. J Med Case Rep 2011;5:1-5. doi: 10.1186/1752-1947-5-491.
26. Li D, Xu S, Sun M, Qiao L, Wang L, Liu Y. MAID chemotherapy regimen as a treatment strategy for metastatic malignant ameloblastoma A case report. Medicine (Baltimore) 2019;98:1-5. doi: 10.1097/MD.0000000000015873.
27. Murad MH, Sultan S, Haffar S, Bazerbachi F. Methodological quality and synthesis of case series and case reports. Evid Based Med 2018;23:60-3.
28. Shi HA, Benjamin Ng C, Kwa CT, Sim QX. Ameloblastoma: A succinct review of the classification, genetic understanding and novel molecular targeted therapies. Surgeon 2021;19:238-43.
29. Bedi N, Grewal P. Different treatment modalities for the management of ameloblastoma. J Adv Med Dent Sci Res 2016;4:96-101.
30. Au SW, Li KY, Choi WS, Risk YX. Risk factors for recurrence of ameloblastoma: A long-term follow-up retrospective study. Int J Oral Maxillofac Surg 2019;48:1300-6.