Original Article

Evaluation of VEGF, BDNF, TRKB expression in oral epithelial dysplasia, oral verrucous carcinoma and oral squamous cell carcinoma and their role as prognostic indicator

Kumaresan Indra Priyadharshini, Sekar Balakrishnan, Ravi Saranyan[1], Madhavan Nirmal[2], Ambika Murugesan, Thuckanaicken palayam Ragunathan Yoithappra bhunath[3]

Departments of Oral Pathology and Oral Microbiology and [1]Periodontics, Vinayaka Mission's Sankarachariyar Dental College and Hospitals, VMRF (DU) Salem, Tamil Nadu, [2]Department of Oral Pathology and Microbiology, Rajamuthiah Dental College, Annamalai University, Annamalinagar, Chidambaram-2, Tamil Nadu, [3]Department of Oral Pathology, Vivekanandha Dental College for Women, Tamil Nadu, India

For correspondence: Dr. Kumaresan Indra Priyadharshini, Associate Professor, Department of Oral Pathology and Oral Microbiology, Vinayaka Mission's Sankarachariyar Dental College and Hospital, VMRF (DU), Sankari Main Road, Ariyanoor, Salem - 636 308, Tamil Nadu, India. E-mail: drindrapriyadharshini@vmsdc.edu.in

ABSTRACT

Background: Oral squamous cell carcinoma (OSCC) is a serious health disease that can lead to a reduced quality of life or even death. It ranks sixth in terms of cancer expansion. It is one of India's primary causes of natural death. In OSCC such potentially malignant Disorders (PMDs) are precancerous lesions with such a high risk of progression. Tumor angiogenesis is a one of the basic biomarkers that may influence the proliferation of a precancerous lesion into the cancerous lesion. Tropomyosin receptor kinase B (TrkB), vascular endothelial growth factor (VEGF), and brain-derived neurotrophic factor (BDNF) also play important roles in carcinogenesis by promoting angiogenesis. The construction of new vessels of blood from existing vasculature is referred as angiogenesis.

Aim of the Study: To get deep insights of immunohistochemistry expression of VEGF, BDNF, and TRKB in oral epithelial dysplasia (OED), verrucous carcinoma (VC), and OSCC.

Material and Methods: The study included 100 formalin-fixed paraffin-embedded tissue blocks from 20 cases of OED, 20 cases of VC, and 60 cases of OSCC [20 cases of well-differentiated oral squamous cell carcinoma (WD-OSCC), 20 cases of moderately differentiated oral squamous cell carcinoma (MD-OSCC), and 20 cases of poorly differentiated oral squamous cell carcinoma (PD-OSCC). The staining intensity and distribution of VEGF, BNDF, and TrkB were examined and statistically analyzed using analysis of variance (ANOVA), post hoc Bonferroni test, independent t-test, Pearson's Chi-square test, and Pearson's correlation coefficient test.

Results: The immunoexpression of VEGF, BDNF, and TrkB was found to be elevated in the order of OEDs, VC, and OSCC. The percentage of positive was highest in PD-OSCC, followed by MD-OSCC and WD-OSCC.

Conclusion: Based on our findings, angiogenesis plays a significant role in tumor growth and metastasis. A substantial relationship was discovered between VEGF, BDNF, TrkB expression, and increases in vascularity throughout the transition from OEDs to VCs and OSCCs.

KEY WORDS: Angiogenesis, dysplasia, growth factor, oral cancer, oral dysplasia, verrucous carcinoma

INTRODUCTION

The term dysplasia originated from the ancient Greek word where in "dys" means abnormal; "plasia" means growth. The terminology was first introduced in pathology by Reagon, in the year 1958, to describe exfoliated cells from cervix. Presence of OED has believed to be first change related to advancement into malignant transformation.[1] Oral potentially malignant

Access this article online	
Website: https://journals.lww.com/cancerjournal	Quick Response Code:
DOI: 10.4103/jcrt.jcrt_2406_22	

This is an open access journal, and articles are distributed under the terms of the Creative Commons Attribution-NonCommercial-ShareAlike 4.0 License, which allows others to remix, tweak, and build upon the work non-commercially, as long as appropriate credit is given and the new creations are licensed under the identical terms.

For reprints contact: WKHLRPMedknow_reprints@wolterskluwer.com

Cite this article as: Priyadharshini KI, Balakrishnan S, Saranyan R, Nirmal M, Murugesan A, Yoithapprabhunath TR. Evaluation of VEGF, BDNF, TRKB expression in oral epithelial dysplasia, oral verrucous carcinoma and oral squamous cell carcinoma and their role as prognostic indicator. J Can Res Ther 2024;20:1376-83.

Submitted: 15-Nov-2022
Revised: 05-Jan-2023
Accepted: 12-Jan-2023
Published: 07-Oct-2023

Downloaded from http://journals.lww.com/cancerjournal by BhDMf5ePHKav1zEoum1tQfN4a+kJLhEZgbsIHo4XMi0hCywCX1AWnYQp/IlQrHD3i3D0OdRyi7TvSFl4Cf3VC1y0abggQZXdtwnfKZBYtws= on 09/20/2024

© 2023 Journal of Cancer Research and Therapeutics | Published by Wolters Kluwer - Medknow

Downloaded from http://journals.lww.com/cancerjournal by BhDMf5ePHKav1zEoum1tQfN4a+kJLhEZgbsIHo4XMi0hCywCX1AWnYQp/IlQrHD3i3D0OdRyi7TvSFl4Cf3VC1y0abggQZXdtwnfKZBYtws= on 09/20/2024

disorder (OPMD) is a clinical terminology used for precursor lesions, for which the histological diagnosis may be epithelial dysplasia. OPMDs are the precursor lesions which include leukoplakia, erythroplakia, actinic keratosis, reverse smoker's palate, oral submucous fibrosis, erosive lichen planus, and lupus erythematosus. It has a global prevalence rate ranges from 1% to 5% and 36% of dysplastic lesions advance into malignancy. An early epidemiological study from India reported that 80% of oral cancers were preceded by OPMDs.[2]

In India, non-communicable diseases (NCDs) were estimated to account for 63% of all deaths, and cancer was one of the leading causes (9%). According to the India fact sheet of that GLOBALCAN 2020, cancer of the lip and oral cavity showed a huge increase of 114.2% with 56,000 cases in 2012, increased to 1,19,992 in 2018 then to 1,35,929 in 2020.[3,4] The prevalence of OPMDs was 13.7% with the most common disorder being oral submucous fibrosis (8.06%), leukoplakia (4.02%), lichen planus (1.38%), and erythroplakia, the least prevalent (0.24%).[5,6] 2–12% of oral malignancies are verrucous carcinomas, which are considered to be the low-grade variant of OSCC.[7]

VEGF is a key contributor to angiogenesis that belongs to superfamily of platelet-derived growth factor (PDGF). VEGF along with its associate receptor was contemplated as a powerful angiogenic activator.[8,9] It activates motility and maturation of endothelial cells (ECs) which allow the movement of blood and oxygen toward the hypoxic environment. Tumor-associated ECs exhibit rapid proliferation when compared to ECs of normal tissue. VEGF expression is a sensitive angiogenesis marker used to evaluate tumor angiogenesis cells which has been identified to be useful in tumor promotion, tumor progression, and even predicting metastasis.[10,11] Hypoxia inducible factor 1α (HIF 1α) and PDGF-B upregulate VEGF, and overexpression of these factors exemplifies the processes that mediate tumor angiogenesis. Endogenous inhibitors of angiogenesis such as angiostatin, endostatin, and thrombospondin 1 further regulate this complex process.[12,13]

BDNF is a nerve growth factor which belongs to neurotrophic family. These growth factors engage in the proliferation, differentiation, migration as well as survival of neural cells. In a nutshell, it coordinates neurogenesis in the central and peripheral nervous systems. BDNF is a ligand which has high affinity toward tropomyosin-related kinase B (TrkB).[14,15] The significant role of BNDF/TrkB in cancers occurs by enhancing high cell proliferation, angiogenesis, invasion and metastasis, apoptosis resistance, and poor prognosis.[16-18] Especially the ligand induces angiogenesis through VEGF by regulating (HIF 1α) and PDGF-B.

Several reports indicate that tumor expressing high level of TrkB induces more angiogenesis when compared to other TrkA, TrkC. The expression of VEGF, BDNF/TRKB and their role in OED, VC, and OSCC are not explored.

MATERIALS AND METHODS

A study was carried out on 100 formalin-fixed paraffin-embedded tissue blocks of normal oral mucosa, VC, and OSCC between July 2016 and December 2020. To carry out this study, approval was obtained from the ethics committee (VMSDC/IEC/Approval No 81), and the study was onducted in Central Research Laboratory. The tissue samples were distributed accordingly: 20 cases of OED, 20 cases of VC, and 60 cases of OSCC, 20 cases of normal oral epithelium. Placental tissue and nerve tumor were used as positive control for the study.

Histologic grading for presence of epithelial dysplasia was classified according to WHO classification 2005. Furthermore, the tissue hindered OSCC (60 cases were obtained based on degree of difference 20 – poorly differentiated squamous cell carcinoma) which was retrieved from the Department of Oral Pathology and Microbiology.

The grouping below briefly depicts various tissue samples and its distribution.

Group 1: OED (20 cases).

Group 2: VC (20 cases).

Group 3: OSCC (60).

Group 3A: WD-OSCC (20).

Group 3B: MD-OSCC (20).

Group 3C: PD-OSCC (20).

Procedure

Two set of 3 micrometer thickness serial sections were obtained by using standard semiautomatic microtome (Wiswas SMT-1090A) from the archival blocks. Each section was used for both IHC and H and E procedures.

Antibodies used

1. **Primary antibody:**
   VEGF (Biogenex, RTU), AR483-2R.
   BDNF polyclonal antibody at dilution of 1: 100 (Abbkine) E-AB-18244.
   Trk B polyclonal antibody at dilution of 1: 100 (Elabscience), ABP52643.
2. **Secondary antibody**: Poly Excel-HRP Micropolymer IHC Detection system, CAT NO- OSH001 (PathnSitu).

Procedure for immunohistochemical staining

Deparaffinization

Depending upon the HRP/DAB finding method, the IHC was done, and the slides were deparaffinized by doing two interchanges in xylene solution for twenty minutes.

Downloaded from http://journals.lww.com/cancerjournal by BhDMf5ePHKav1zEoum1tQfN4a+kJLhEZgbsIHo4XMi0hCywCX1AWnYQp/IlQrHD3i3D0OdRyi7TvSFl4Cf3VC1y0abggQZXdtwnfKZBYtws= on 09/20/2024

Dehydration

Slides were continued by two interchanges in low grades of alcohol for twenty minutes. Antigen retrieval method of heat-induced epitope retrieval using pressure cooker was followed. Tris EDTA buffer was used. Peroxidase block: 3% hydrogen peroxide applied on the sections and incubated for ten minutes. Clean with immuno buffer for three minutes each in two changes. Primary antibody: VEGF, TRKB, and BDNF antibodies applied on the sections and incubated for one hour. Clean with phosphate buffer for three minutes each in two changes.

Secondary antibody

Target binder applied on the sections and incubated with immuno buffer for three minutes each in two changes.

Secondary antibody

HRP polymer applied on the sections and incubated with immuno buffer for three minutes each in two changes. Substrate chromogen solution – Newly prepared DAB solution applied on the sections for five minutes incubation period at room temperature in moist chamber. Clean the slides with distilled water for five minutes. Counter stain: Harris hematoxylin applied on the sections for three to five minutes. Cleaned by tap water for five minutes. Dehydrate: Sections were treated with high grades of alcohol for ten minutes. Mounting: Dry the sections, and DPX mounting was done.

Interpretation of VEGF, Trk B, BDNF staining

The immunostained slides were observed under 10x/40x magnifications in order to check for positivity. A high-quality photomicrograph was used to record the positivity. A brown precipitate in the cytoplasm tumor cells indicates a positive reaction. Every section and field were examined and analyzed. The profound area which showed intensity was taken into account.

Evaluation of immunoreactivity

VEGF immunostaining was evaluated by a semiquantitative scoring system as.

A. Percentage of VEGF, Trk B, BDNF immunoreactivity
B. Staining intensity
C. VEGF, Trk B, BDNF final score - Two participants observed the ratio of VEGF positivity in each field. The region of staining was scored based on Klein *et al.*,[19] scoring criteria classification for IHC labeled cells [Table 1].

Statistical analysis

Immunohistochemical expression data of VEGF, TrkB, BDNF for all the samples were collected and analyzed with help of SPSS version 20, through mean, standard deviation, analysis of variance (ANOVA) was used in post hoc Bonferroni test. In comparison between OED, VC, OSCC and all four markers, dependent *t*-test, Chi-square test and Spearman's correlation coefficient test was used. *P* values that are below 0.05 were taken as statistically significant.

RESULTS

All the 100 cases including OEDs 20, VC 20, OSCC 60 (WD-OSCC -20, MD-OSCC – 20, and PD-OSCC – 20) cases tested for vascularization were immunopositive.

VEGF immunohistochemical stain expression

The immunohistochemical (IHC) expression of VEGF in comparative study of OED, VC, and OSCC is shown in Table 2 and Figure 1. Among the different types of groups, OED (Group I) showed mild VEGF expression in 60% of the cases followed by the moderate VEGF (10%), and severe VEGF expression was not recorded in this study. Further, 30% cases were resulted in negative in VEGF expression. In VC (Group II), a similar trend was seen in the VEGF expression as noted in the Group I. However, a higher no of cases (35%) were seen in the moderate VEGF expression when compared to Group I (10%), and only 15% of the Group II cases were shown negative to VEGF stain expression.

In Group III-A, an opposite trend was noted in the mild (30%) and moderate (55%) VEGF expression cases when compared to Group II, and similar trend was seen in severe and negative VEGF marker stain expression as seen in Group II.

In Group III-B, a positive response was seen in severe VEGF expression cases (25%) followed by moderate VEGF cases (40%)

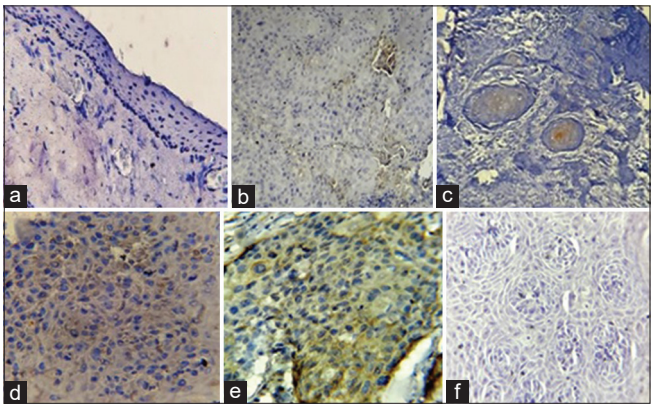

Figure 1: Photography showing VEGF expression. (a) Mild VEGF immunoreactivity in basal and parabasal layers in OED (40X). (b) Moderate VEGF immunoreactivity in VC (40X). (c) Moderate VEGF immunoreactivity in WD-OSCC (40X). (d) Moderate VEGF immunoreactivity in MD-OSCC (40X). (e) Severe VEGF immunoreactivity in PD-OSCC (40X) (f) Negative control (40x)

Table 1: Klein *et al.*[19] Classification for IHC-labeled cells

A % IHC Labelled Cells	B Intensity of IHC Reaction	Final Score	Overall Expression
0 = 0 %	0 = No Reaction		0 – 1 = Negative
1 = < 30 %	1 = Weak	A + B = Range From 0-6	1 -2 Mild Expression >2
2 = 30 -60 &	2 = Mild		>2-4 = Moderate Expression
3 = > 60 %	3 = Strong		> 4-6 = Severe Expression

Downloaded from http://journals.lww.com/cancerjournal by BhDMf5ePHKav1zEoum1tQfN4a+kJLhEZgbsIHo4XMi0hCywCX1AWnYQp/IlQrHD3i3D0OdRyi7TvSFl4Cf3VC1y0abggQZXdtwnfKZBYtws= on 09/20/2024

and mild VEGF cases (20%). On the other hand, a similar result was noted in the VEGF negative expression (15%) as seen in Group-II.

In Group III-C, a higher frequency was seen in severe VEGF expression (50%), and a similar expression was recorded in moderate (15%) and negative VEGF expression cases. On the other hand, no expression was seen in mild score groups (0%).

Overall compassion of VEGF IHC stain expression in all types of cancer revealed that highest score was seen in moderate VEGF expression (35%) followed by mild VEGF expression (32%), severe VEGF expression (15%), and 18% of cases were shown negative expression.

Statistical analysis by Chi-square test revealed that VEGF expression was highly significant ($P < 0.001$) among different cancer study group.

TRKB immunohistochemical stain expression

Table 3 and Figure 2 depicts the comparative study of TRKB immunohistochemical stain expression score in OED, VC, and OSCC. In the present study, OED (Group I) TRKB stain expression score was 65% in mild expression group, 10% in moderate expression group, and none of the case was recorded in severe score group, and in this study, 25% of the case resulted in negative to TRKB IHC stain expression

Expression of TRKB stain in VC (Group II) resulted in very good expression in both mild (50%) and moderate (35%) score groups, and a similar trend was noted in severe expression groups as seen in oral epithelial dysplasia. However, negative to TRKB stain was low (15%) when compared to Group I.

In Group III-A, an opposite trend was seen in mild (30%) and moderate (55%) TRKB stain expression, when compared to Group II. On the other hand, similar trend was seen in negative (15%) and severe TRKB stain expression evaluation score groups (0%).

In Group III-B, the TRKB stain expression showed a positive response in all three cases, and the expression was 10% in mild, 50% in moderate cases, and 25% in severe stain expression cases. Further 15% was found to negative to TRKB stain expression.

Assessment of TRKB IHC stain expression in Group III-c resulted 85% in good expression in both moderate and severe stain score groups, and 15% of the cases were negative to TRKB stain expression; the positive to TRKB stain expression was more or less equal in moderate (40%) and severe (45%) expression cases, but TRKB stain expression was not seen in mild score expression group.

Overall study with TRKB IHC stain expression of 100 cases in three types of cancer revealed that 83% of the cases were

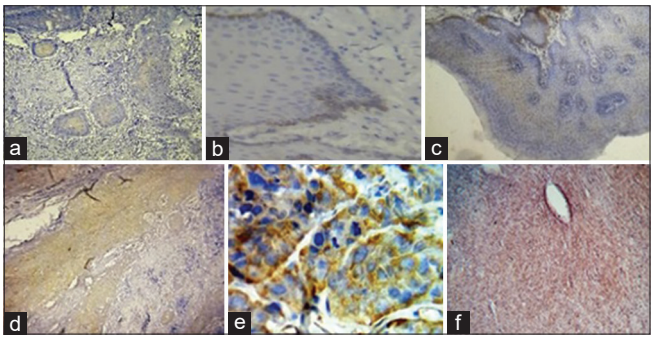

Figure 2: Photography showing TrkB expression. (a) Negative-to-mild TrkB immunoreactivity in basal and parabasal layers in OED (40X). (b) Mild TrkB immunoreactivity in VC (10X). (c) Mild TrkB immunoreactivity in WD-OSCC (40X). (d) Moderate TrkB immunoreactivity in MD-OSCC (10X). (e) Severe TrkB immunoreactivity in PD-OSCC (40X). (f) Severe TrkB immunoreactivity in PD-OSCC (10x)

Table 2: Comparison between various groups based on VEGF value using Chi-square test

Group	VEGF				Total	Chi-square value	*P*
	Negative	Mild	Moderate	Severe			
Oral epithelial dysplsia (I)	6	12	2	0	20	48.91	0.001
Verrucous carcinoma (II)	3	10	7	0	20		
Well OSCC (IIIA)	3	6	11	0	20		
Moderately OSCC (IIIB)	3	4	8	5	20		
Poorly OSCC (IIIC)	3	0	7	10	20		
Total	18	32	35	15	100		

Table 3: Comparison between various groups based on trkb value in using Chi-square test

Group	TRKB				Total	Chi-square value	*P*
	Negative	Mild	Moderate	Severe			
Oral epithelial dysplsia (I)	5	13	2	0	20	71.93	0.001
Verrucous carcinoma (II)	3	10	7	0	20		
Well OSCC (IIIA)	3	6	11	0	20		
Moderately OSCC (IIIB)	3	2	10	5	20		
Poorly OSCC (IIIC)	3	0	8	9	20		
Total	17	31	38	14	100		

Downloaded from http://journals.lww.com/cancerjournal by BhDMf5ePHKav1zEoum1tQfN4a+kJLhEZgbsIHo4XMi0hCywCX1AWnYQp/IlQrHD3i3D0OdRyi7TvSFl4Cf3VC1y0abggQZXdtwnfKZBYtws= on 09/20/2024

expressed TRKB IHC stain, and 17% of the cases were negative expression to TRKB IHC stain, which was well documented in the statistical Chi-square analysis, and TRKB stain expression was highly significant ($P < 0.001$) in all three cancer tissues.

BDNF immunohistochemical stain expression

Comparative study of BNDF immunohistochemical stain expression score in OED, VC, and OSCC was given in Table 4 and Figure 3. In Group I, BNDF stain expression was seen dominantly seen in mild and moderate cases as 60% and 10%, respectively, and no expression was seen in severe stain score category groups. And 30% of patient's samples were negative to BNDF stain.

In VC study (Group II) on BNDF stain expression, 50% of the patients have shown mild expression score and moderate expression score was noted in 35% of patients; on the other hand, severe expression of BNDF stain was not seen (0%), and only 15% of the patients shown negative expression to BNDF stain.

In OSCC, BNDF stain was well expressed in all the three types of OSCC groups (Group III A, Group III B, and Group C). However, the intensity of stain expression varies in mild, moderate, and severe score groups.

In Group III – A, 55% of the cases were shown in moderate score group followed by mild expression score group (35%);

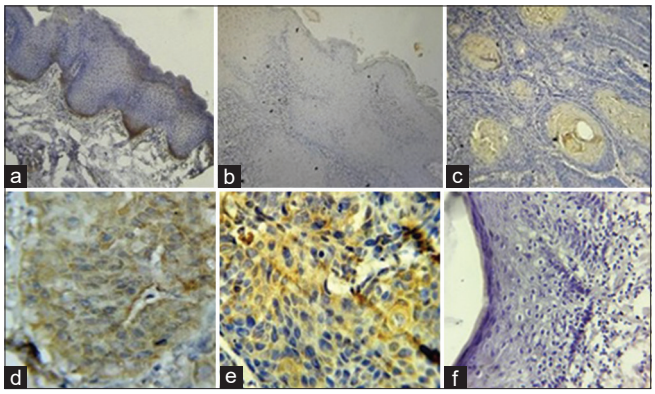

Figure 3: Photography showing BDNF expression. (a) Negative-to-mild BDNF immunoreactivity in basal and parabasal layers in OED (10X). (b) Mild BDNF immunoreactivity in VC (10X). (c) Mild BDNF immunoreactivity in WD-OSCC (40X). (d) Moderate BDNF immunoreactivity in MD-OSCC (40X). (e) Severe BDNF immunoreactivity in PD-OSCC (40X). (f) negative control (40x)

BNDF expression was not seen in severe score group (0%), and 10% of the cases were shown negative to BNDF expression.

In Group III –B, a notable BNDF stain was expressed in severe score group (25%) and 65% of cases seen in moderate score expression group; on the other hand, only 5% of cases shown BNDF stain expression in mild score groups and 5% of cases have shown negative to BNDF stain.

In Group III –C, as expected, a good BNDF stain expression was noted. In severe score group, 65% cases were registered with good stain expression; on the other hand, 35% of the cases were seen in moderate score BNDF expression groups. In this group, 100% of the cases positive to BNDF stain, and none of the cases shown negative (0%) to BNDF stain.

In the present study, 88% of the study samples were expressed response to the BNDF stains expression, and only 12% of the study samples were not expressed in BNDF stain in all the three types of cancer patients. These results were statistically analyzed by Chi-square test and found statistically highly significant ($P < 0.001$).

DISCUSSION

In various studies, demonstration of the prognostic role of angiogenesis in different neoplasm was studied relatively less information was available in literature record the relationship between angiogenesis and premalignant and malignant tumors.

Carcinogenesis is a deregulated cell cycle event due to mutated oncogenes, tumor suppressor genes, and altered microenvironment, and 80% of oral cancers were preceded by OPMDs showing epithelial dysplasia.[20] Oral carcinogenesis is development of cancer from precursor lesions, and the two-step process is well established through literatures. WHO defined precursor lesion as "altered epithelium with an increased likelihood for progression to squamous cell carcinoma."[21] Epithelial alteration is caused by dysplasia which is cytological and architectural changes happening within the epithelium.[22]

Development and enhancement of blood vessels from the prevailing vasculature are defined as angiogenesis. New

Table 4: Comparison between various groups based on BDNF value in using Chi-square test

Group	BDNF				Total	Chi-square value	*P*
	Negative	Mild	Moderate	Severe			
Oral epithelial dysplsia (I)	6	12	2	0	20	78.72	0.001
Verrucous carcinoma (II)	3	10	7	0	20		
Well OSCC (IIIA)	2	7	11	0	20		
Moderately OSCC (IIIB)	1	1	13	5	20		
Poorly OSCC (IIIC)	0	0	7	13	20		
Total	12	30	40	18	100		

Downloaded from http://journals.lww.com/cancerjournal by BhDMf5ePHKav1zEoum1tQfN4a+kJLhEZgbsIHo4XMi0hCywCX1AWnYQp/IlQrHD3i3D0OdRyi7TvSFl4Cf3VC1y0abggQZXdtwnfKZBYtws= on 09/20/2024

vasculature is formed by endothelial cells in multiple steps which is mediated through protein molecule mediators. Presence of capillaries that are closely put adjacent to (juxtaposed) to dysplastic epithelium in histological sections of bronchial epithelium was identified as angiogenic squamous dysplasia (ASD). Presence of such ASD-like complex in OPMDs may represent as an inevitable biomarker of foregoing oral carcinogenesis process. Angiogenesis plays major role in advancement of oral dysplasia to carcinoma.[8] This entire process depends on the development of blood vessels by prevailing vasculature which plays a vital part in progression of the tumor.

Cell proliferation, rather than cell death or apoptosis, is always required for tumor formation. Tumor angiogenesis aids tumor growth after it has reached a particular millimeter size. It has been demonstrated that while improved vascular response reduces tumor cell death, tumor cell enhancement remains same, resulting in net tumor growth.[23]

Angiogenesis considered to involve pathogenesis and development of blood cancer, influencing the tumor's ability to grow, invade, and eventually metastasis, according to many studies. Vascularity enhances from regular mucosa to moderate dysplasia to malignancy, however, according to studies in patients suffering OSCC.[24]

In literature, several angiogenic markers have been used to evaluate blood vessels. Angiogenesis is controlled by a balance of angiogenic stimulators such as TGF-, VEGF, and FGF and inhibitors such as TSP-1, angiostatin, and PF4.[24,25] The exhausted tumor cells stimulate angiogenesis through hypoxic environment. VEGF is one such strong angiogenic cytokine involved with tumor angiogenesis.[26,27] VEGF secretion mediated by hypoxia inducible factor increases its production and also stimulates angiogenesis.[28,29]

In our study, mild VEGF immunoexpression was seen basal and suprabasal layers of epithelium in group 1 samples, and group 2- VC samples showed mild-to-moderate immunoexpression in peripheral area. In Group 3, well-differentiated squamous cell carcinoma (Group 3A) showed mild-to-moderate immunoexpression mostly seen within the keratin pearl area, MD-OSCC (Group 3B) total epithelial thickness showed moderate immunoexpression, and PD-OSCC (Group 3C) showed moderate-to-severe immunoexpression in diffuse area. Overall, VEGF immunoreactivity reaction was found to be increased from OED to VC and to different grades of OSCC.

Sonia Gupta *et al*.[8] Michailidou *et al*.[30] reported that there was a profound increase in immunoexpression of VEGF and CD34 during the alteration from oral mucosa to severe oral epithelial dysplasia. Johnstone S *et al*. stated that upregulated VEGF immunoexpression during the transition from normal oral mucosa, through OED to OSCC.[31] Astekar M *et al*. found that there is an increased VEGF expression and microvascular density (MVD) from normal oral mucosa, through dysplasia to OSCC. These results substantiate that VEGF expression is upregulated during carcinogenesis.[32] In literature, the intensity of VEGF expression was considered to be aggressive by correlating with lymph node metastasis.[33] Increased immunoexpression of VEGF was appreciated from dysplasia to OSCC through different grades. VEGF shows the expression of epithelial VEGF that can be used as tool to evaluate density of lesion.

BDNF first was identified as neurotrophic factor that is important for the life of neurons, as well as their development, regeneration after injury to the peripheral and CNS. BDNF expression has been observed in a variety of non-union systems, including blood arteries, bone marrow, and the heart.[34,35]

BDNF and its receptors have been linked to gastric and lungs cancer, HC, OC, prostate cancer, oral cancer, and other solid tumors in a few studies.[36,37] Only few studies done investigated the role of BDNF in oral cancer.

TrkB and its secreted ligand BDNF are expressed in human head and neck squamous cell carcinoma, according to Kupferman *et al*.,[38] and they also describe a new role for TrkB and its stimulatory ligand BDNF in the progression of HNSCC.

NGF, BDNF, and Neurotrophin 3 are all receptors for Trks, which have a strong affinity for neurotrophins. TrkA, TrkB, and TrkC are receptors for NGF, BDNF, and Neurotropin 3. (NT3). Trks' role in cancer is still a subject of debate. Angiogenesis and lymphogenesis are linked to the growth of tumor and nodal metastatic spread in several studies.

Few studies in OSCC discovered that VEGF (VEGF C or VEGF D) activation promotes and accelerates blood vessel formation or lymphogenesis, and they also found expression of Trks was greater than normal oral mucosa. Several reports indicate that tumor expressing high level of Trkb induces more angiogenesis when compared to other TrkA, TrkB; particularly altered TrkB expression, signaling, and mutation have been found to be increased in various types of human cancer including carcinoma of pancreas, lung, colon, prostate, neuroblastoma, multiple myeloma, and oral cancer.[39]

There is evidence of TrkB expression in OSCC that it promoted growth of cells, apoptosis inhibition, expression of activated VEGF which were all significantly associated with angiogenesis and poor prognosis.

Mechanistic insights into the tumor promoting potential of TrkB are based on several observations suggested by various studies: i) TrkB expression enhances the migratory capability and invasiveness of neurogenic tumor cell lines;[40,41] ii) cancer cell survival is enhanced by TrkB expression and activation;[42,43] iii) chemotherapy-induced

Downloaded from http://journals.lww.com/cancerjournal by BhDMf5ePHKav1zEoum1tQfN4a+kJLhEZgbsIHo4XMi0hCywCX1AWnYQp/IlQrHD3i3D0OdRyi7TvSFl4Cf3VC1y0abggQZXdtwnfKZBYtws= on 09/20/2024

apoptosis by TrkB;[44,45] iv) TrkB positively regulates vascular endothelial growth factor expression and tumor-associated angiogenesis.[46,47]

TrkB was identified as a master regulator of resistance to detachment-induced cell death. Douma *et al.*[48] observed TrkB expression in head and neck squamous cell carcinoma (HNSCC), and TrkB acts as essential factor for metastatic spread; it was shown that the observed effect could be enhanced after cotransfection of BNDF, when attached with the natural ligand of TrkB. Li Zhu *et al*. study reported that TrkB is significantly overexpressed in HNSCC.[49]

In cancer VEGF and BDNF, TrkB has been shown to play a vital role in tumor angiogenesis, proliferation, invasion, and metastasis in OSCC from premalignant stage to malignant stage.

CONCLUSION

Tumor angiogenesis was vital for solid tumor growth help and is a much promise for designing efficacious treatment for OSCC, with the hope of arresting tumor growth and progression therefore maintain a patient health in a stable. Targeting the angiogenic molecule by chemotherapy (or) antiangiogenic therapy will give better results than cytotoxic chemotherapy against the tumor cells. To the aim to contribute, this may be the first study to research at immunoexpression and the possible role of neurotropic factors in angiogenesis in oral epithelial dysplasia, verrucous carcinoma, and malignant OSCC. The positive expression of BDNF along with TrkB deregulates VEGF. Expression of BNDF/TrkB could be one of the possible reasons behind the biological behavior of tumor progression and tumor angiogenesis. Future research and evidence are needed for through knowledge about the relationship of neutrophins and their role in tumor angiogenesis. Obtaining clear knowledge on the altered molecule signaling pathway will help in elucidating the tumor biology which may help lead us to non-surgical treatment approach in near future.

Financial support and sponsorship

Nil.

Conflicts of interest

There are no conflicts of interest.

REFERENCES

1. Rastogi V, Puri N, Mishra S, Arora S, Kaur G, Yadav L. An insight to oral epithelial dysplasia. Int J Head Neck Surg 2013;4:74-82.
2. Ranganathan K, Kavitha L. Oral epithelial dysplasia: Classifications and clinical relevance in risk assessment of oral potentially malignant disorders. J Oral Maxillofac Pathol 2019;23:19–27.
3. Siegel RL, Miller KD, Fuchs HE, Jemal A. Cancer statistics, 2022. CA Cancer J Clin 2022;72:7-33.
4. Mathur P, Sathishkumar K, Chaturvedi M, Das P, Sudarshan KL, Santhappan S, *et al*. Cancer Statistics, 2020: Report from National Cancer Registry Programme, India. JCO Glob Oncol 2020;6:1063-75.
5. Kumar S, Debnath N, Ismail MB, Kumar A, Kumar A, Badiyani BK, *et al*. Prevalence and risk factors for oral potentially malignant disorders in Indian population. Adv Prev Med 2015;2015:1-7.
6. Gopinath D, Thannikunnath BV, Neermunda SF. Prevalence of carcinomatous foci in oral leukoplakia: A clinicopathologic study of 546 Indian samples. J Clin Diagn Res 2016;10:78-83.
7. Peng Q, Wang Y, Quan H, Li Y, Tang Z. Oral verrucous carcinoma: From multifactorial etiology to diverse treatment regimens. Int J Oncol 2016;49:59-73.
8. Gupta S, Gupta V, Tyagi N, Vij R, Vij H, Sharma E. Analysis of role of angiogenesis in epithelial dysplasia: An immunohistochemical study. J Clin Diagn Res 2017;1:11.
9. Krause DS, Fackler MJ, Civin CL, May WS. CD34: Structure, biology and clinical utility. Blood 1996;87:01-13.
10. Roskoski R. Vascular endothelial growth factor (VEGF) signalling in tumour progression. Crit Rev Oncol Hematol 2007;62:179-213.
11. Zachary I. Molecules in focus vascular endothelial growth factor. Int J Bio Chem Cell B 1998;30:1169-74.
12. Batchelor TT, Sorensen AG, di Tomaso E, Zhang WT, Duda DG, Cohen KS, *et al*. AZD2171, a pan-VEGF receptor tyrosine kinase inhibitor, normalizes tumor vasculature and alleviates edema in glioblastoma patients. Cancer Cell 2007;11:83-95.
13. Augustin HG, Young Koh G, Thurston G, Alitalo K. Control of vascular morphogenesis and homeostasis through the angiopoietin–Tie system. Nat Rev Mol Cell Biol 2009;10:165-77.
14. Carmeliet P, Jain RK. Angiogenesis in cancer and other diseases. Nature 2000;407:249-57.
15. Machein MR, Knedla A, Knoth R, Wagner S, Neuschl E, Plate KH. Angiopoietin-1 promotes tumor angiogenesis in a rat glioma model. Am J Pathol 2004;165:1557-70.
16. Yancopoulos GD, Davis S, Gale NW, Rudge JS, Wiegand SJ, Holash J. Vascular-specific growth factors and blood vessel formation. Nature 2000;407:242-8.
17. Folkman J. Endogenous angiogenesis inhibitors. Apmis 2004;112:496-507.
18. Fredriksson L, Li H, Eriksson U. The PDGF family: Four gene products form five dimeric isoforms. Cytokine Growth Factor Rev 2004;15:197-204.
19. Klein M, Picard E, Vignaud JM, Marie B, Bresler L, Toussaint B, *et al*. Vascular endothelial growth factor gene and protein: Strong expression in thyroiditis and thyroid carcinoma. J Endocrinol 1999;161:41-9.
20. Barnes L, Eveson JW, Reichert P, Sidransky D, editors. World Health Organization Classification of Tumours, Pathology & Genetics of Head and Neck Tumours. 1. Lyon: IARC Press; 2005.
21. Reibel J. Prognosis of oral pre-malignant lesions: Significance of clinical, histopathological and molecular biological characteristics. Crit Rev Oral Biol Med 2003;14:47-62.
22. Graziano L, Preziosi L. Mechanics in tumor growth. In Modeling of Biological Materials. Birkhäuser Boston; 2007. p. 263-321.
23. Michailidou EZ, Markopoulos AK, Antoniades DZ. Mast cells and angiogenesis in oral malignant and premalignant lesions. Open Dent J 2008;2:126-32.
24. Mohammad DN, Garib BT. CD34 and Wnt3 expression in potentially malignant oral disorders. J Bagh Coll Dent 2017;29:59-67.
25. Tahir A, Nagi AH, Ullah E, Janjua OS. The role of mast cells and angiogenesis in well-differentiated oral squamous cell carcinoma. J Cancer Res Ther 2013;9:387.
26. Tae K, El-Naggar AK, Yoo E, Feng L, Lee JJ, Hong WK, *et al*. Expression of VEGF and MVD in head and neck tumorigenesis. Clin Cancer Res 2000;6:2821-8.
27. Klein M, Picard E, Vignaud JM, Marie B, Bresler L, Toussaint B, *et al*. Vascular endothelial growth factor gene and protein: Strong expression in thyroiditis and thyroid carcinoma. J Endocrinol 1999;161:41-9.

28. Kim KJ, Li B, Winer J, Winer J, Armanini M, Gillett N, *et al*. Inhibition of vascular endothelial growth factor induced angiogenesis suppresses tumor growth in vivo. Nature 1993;362:841-4.
29. Michailidou EZ, Markopoulos AK, Antoniades DZ. Mast cells and angiogenesis in oral malignant and premalignant lesions. Open Dent J 2008;2:126-32.
30. Johnstone S, Logan RM. Expression of vascular endothelial growth factor (VEGF) in normal oral mucosa, oral dysplasia and oral squamous cell carcinoma. Int J Oral Maxillofac Surg 2007;36:263-6.
31. Astekar M, Joshi A, Ramesh G, Metgud R. Expression of vascular endothelial growth factor and microvessel density in oral tumorigenesis. J Oral Maxillofac Pathol 2012;16:22-6.
32. Moriyama M, Kumagai S, Kawashiri S. Immunohistochemical study of tumor angiogenesis in OSCC. Oral Oncol 1997:33:369-74.
33. Kelly-Spratt KS, Klesse LJ, Parada LF. BDNF activated TrkB/IRR receptor chimera promotes survival of sympathetic neurons through Ras and PI-3 kinase signaling. J Neurosci Res 2002;69:151-9.
34. Wong J. Neurotrophin signaling and Alzheimer's disease Neurodegeneration-Focus on BDNF/TrkB signaling, trends in cell signaling pathways in neuronal fate decision. In: Wislet-Gendebien S, editor. InTech; 2013.
35. Eberhardt KA, Irintchev A, Al-Majed AA, Simova O, Brushart TM, Gordon T, *et al*. BDNF/TrkB signaling regulates HNK-1 carbohydrate expression in regenerating motor nerves and promotes functional recovery after peripheral nerve repair. Exp Neurol 2002;198:00-10.
36. Berner A, Reichert JC, Müller MB, Zellner J, Pfeifer C, Dienstknecht T, *et al*. Treatment of long bone defects and non-unions: From research to clinical practice. Cell Tissue Res 2012;347:501-9.
37. Chen J, Li Y, Chopp M. Intracerebral transplantation of bone marrow with BDNF after MCAo in rat. Neuropharmacology 2000;39:711-6.
38. Kupferman M, Jiffar T, El-Naggar A, Yilmaz T, Zhou G, Xie T, *et al*. TrkB induces EMT and has a key role in invasion of head and neck squamous cell carcinoma. Oncogene 2010;29:2047-59.
39. Nakagawara A. Trk receptor tyrosine kinases: A bridge between cancer and neural development. Cancer Lett 2001;169:107-14.
40. Matsumoto K, Wada RK, Yamashiro JM, Kaplan DR, Thiele CJ. Expression of brain-derived neurotrophic factor and p145TrkB affects survival, differentiation, and invasiveness of human neuroblastoma cells. Cancer Res 1995;15:1798-806.
41. Martens LK, Kirschner KM, Warnecke C, Scholz H. Hypoxia-inducible factor-1 (HIF-1) is a transcriptional activator of the TrkB neurotrophin receptor gene. J Biol Chem 2007;282:14379-88.
42. Ho R, Eggert A, Hishiki T, Minturn JE, Ikegaki N, Foster P, *et al*. Resistance to chemotherapy mediated by TrkB in neuroblastomas. Cancer Res 2002;62:6462-6.
43. Pearse RN, Swendeman SL, Li Y, Rafii D, Hempstead BL. A neurotrophin axis in myeloma: TrkB and BDNF promote tumor-cell survival. Blood 2005;105:4429-36.
44. Jaboin J, Kim CJ, Kaplan DR, Thiele CJ. Brain-derived neurotrophic factor activation of TrkB protects neuroblastoma cells from chemotherapy-induced apoptosis via phosphatidylinositol 3′-kinase pathway. Cancer Res 2002;62:6756-63.
45. Pearse RN, Swendeman SL, Li Y, Rafii D, Hempstead BL. A neurotrophin axis in myeloma: TrkB and BDNF promote tumor-cell survival. Blood 2005;105:4429-36.
46. Eggert A, Grotzer MA, Ikegaki N, Liu XG, Evans AE, Brodeur GM. Expression of the neurotrophin receptor TrkA down-regulates expression and function of angiogenic stimulators in SH-SY5Y neuroblastoma cells. Cancer Res 2002;62:1802-8.
47. Nakamura K, Martin KC, Jackson JK, Beppu K, Woo CW, Thiele CJ. Brain-derived neurotrophic factor activation of TrkB induces vascular endothelial growth factor expression via hypoxia-inducible factor-1alpha in neuroblastoma cells. Cancer Res 2006;66:4249-55.
48. Douma S, Van Laar T, Zevenhoven J, Meuwissen R, Van Garderen E, Peeper DS. Suppression of anoikis and induction of metastasis by the neurotrophic receptor TrkB. Nature 2004;430:1034-9.
49. Li Z, Zhang J, Liu Z, Woo CW, Thiele CJ. Downregulation of Bim by brain-derived neurotrophic factor activation of TrkB protects neuroblastoma cells from paclitaxel but not etoposide or cisplatin-induced cell death. Cell Death Differ 2007;14:318-26.

Downloaded from http://journals.lww.com/cancerjournal by BhDMf5ePHKav1zEoum1tQfN4a+kJLhEZgbsIHo4XMi0hCywCX1AWnYQp/IlQrHD3i3D0OdRyi7TvSFl4Cf3VC1y0abggQZXdtwnfKZBYtws= on 09/20/2024