ScientificScholar®
Knowledge is power
Publisher of Scientific Journals

https://djigims.com

Dental Journal of Indira Gandhi Institute of Medical Sciences



Case Report

Amlodipine-Induced Gingival Enlargement – A Case Report

Gayathri Priyadharshini Elangovan[1], Indra Kumar Periasamy[2], Saravana Kumar R[3], Ahila Ezhumalai[4]

Departments of [1]Periodontology, [2]Oral and Maxillofacial Surgery, Vivekanandha Dental College for Women, Ellayampalayam, Tiruchengode, Tamil Nadu, [3]Department of Periodontology, Indira Gandhi Institute of Dental Sciences, Pillayarkuppam, Pondicherry, [4]Department of Periodontology, Sri Venkateshwara Dental College, Ariyur, Pondicherry, India.



***Corresponding author:**
Indra Kumar Periasamy, Department of Oral and Maxillofacial Surgery, Vivekanandha Dental College For Women, Ellayampalayam, Tiruchengode, Tamil Nadu, India.

kumarjeeth27@gmail.com

Received: 26 December 2023

Accepted: 27 February 2024

EPub Ahead of Print: 23 March 2024

Published: 06 April 2024

DOI
10.25259/DJIGIMS_22_2023

Quick Response Code

ABSTRACT

One of the etiological factors for Gingival Enlargement is administration of certain drugs like calcium channel blockers, anticonvulsants, and immunosuppressant. The drug that is been commonly used for the management of portal hypertension is calcium channel blockers. Among the various drugs in calcium channel blockers, the occurrence of drug-induced gingival enlargement is high with the use of nifedipine drug whereas the occurrence of gingival enlargement due to the usage of amlodipine drug is a very rare phenomenon. Amlodipine is a third-generation drug belonging to dihydropyridine calcium channel blocker that has been used for its longer duration of action. Treatment for drug-induced gingival enlargement includes referral of patients to their physician for possible drug substitution or alteration in dosage of drug, periodontal therapy that includes oral prophylaxis followed by gingivectomy or gingivoplasty, and maintenance care. In this study, we report a case of gingival enlargement in a 44-year-old female patient taking amlodipine drug for a period of six months and nonsurgical and surgical management of amlodipine-induced gingival enlargement in the patient.

Keywords: Gingival Enlargement, Drug induced Enlargement, Calcium Channel Blocker, Gingivectomy, Amlodipine drug adverse effects

INTRODUCTION

Gingival enlargement is defined as the increase in the size of the gingiva which depends on cellular and intercellular components along with vascular supply and it is one of the features of gingival diseases. There are different types of gingival enlargement based on the use of drugs and it can be categorized into three different groups, such as anticonvulsant drugs, calcium channel blockers drugs and immunosuppressant drugs.[1,2] The pharmacological effect produced by these three drugs varies but all these drugs act similarly on the gingival tissue, which results in similar clinical and histopathological changes in the gingival tissues. The calcium channel blockers drugs are widely been used for the treatment of cardiovascular disorders.[3] Of the above groups of drugs, dihydropyridines are the drugs that are most frequently implicated.[4] Many case reports have discussed patients taking nifedipine drugs that caused drug-induced gingival enlargement in patients. However, during the last few years, there has been an increase in the usage of amlodipine, which reported to induce gingival enlargement.[5] Amlodipine belongs to third-generation dihydropyridine pharmacological agents that are frequently been used for the treatment of hypertension. The prevalence rate of gingival enlargement caused by amlodipine was reported to be 3.3%,[6] which is significantly lower than that of drugs such as nifedipine, which is 47.8%.[7] Case reports for amlodipine-induced enlargements were first reported by Ellis *et al.*,[8] Seymor *et al.*[5]

This is an open-access article distributed under the terms of the Creative Commons Attribution-Non Commercial-Share Alike 4.0 License, which allows others to remix, tweak, and build upon the work non-commercially, as long as the author is credited and the new creations are licensed under the identical terms.
©2024 Published by Scientific Scholar on behalf of Dental Journal of Indira Gandhi Institute of Medical Sciences

and Lafzi *et al.*[9] They reported gingival enlargement in patients who were taking 10 mg of amlodipine within two months of continuous usage. In our study, we reported a case of amlodipine-induced gingival enlargement in a female patient aged 44 years, taking amlodipine of dosage 5 mg for a period of six months and its management.

CASE REPORT

A 44-year-old female patient was referred to the Department of Periodontics of Indira Gandhi Institute of Dental Sciences, Puducherry with complaints of gingival swelling along with bleeding from gums and pus discharge from gums for the past three months. The patient had a complaint of mild pain in both the upper and the lower front tooth region for the past two months. Poor oral hygiene with spacing in mandibular anterior teeth and between 11 and 12 was also observed. [Figure 1] The patient had no history of adverse habits. The patient was moderately built and with no signs of condition such as anemia. Her vital signs were in the normal range. The patient was under treatment for portal hypertension for the past six months. Furthermore, the patient was also under amlodipine drug of dosage 5 mg for the past six months. OPG revealed the presence of a generalized horizontal type of bone loss. Reports of blood tests were within the normal limit. Correlating the case history, clinical examination and investigations of the above patient, we have arrived at the final diagnosis of drug-induced gingival enlargement (amlodipine-induced) with secondary involvement of plaque-induced gingival inflammation.

TREATMENT

Various oral hygiene instructions and motivation were given to the patient at the first visit. Thorough full mouth treatment that included scaling and root planing were performed, along with a change of drug after consulting with the patient's physician. Hence amlodipine was substituted with losartan 50 mg (OD). Recall after one month revealed some reduction in the size of the gingival enlargement particularly in the mandibular arch. After two months of non-surgical treatment, the remaining enlarged gingival tissue was corrected by surgical intervention. A gingivectomy procedure was planned for gingival tissue in the maxillary arch. [Figures 2–5] There were no signs of any postoperative complications and the healing was found to be satisfactory. The patient was followed up every month for a period of one year and no recurrence was seen in the patient.



Figure 1: Pre-operative.



Figure 2: External bevel gingivectomy incision.



Figure 3: Crevicular incision.

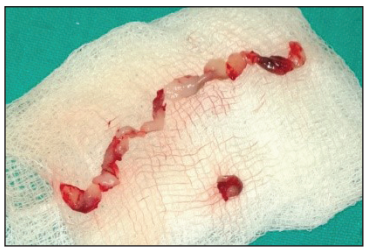

Figure 4: Excision of excess gingival tissue.



Figure 5: Immediate post-operative.

DISCUSSION

Ellis in 1993 reported the very first case of amlodipine-associated gingival enlargement.[8] Jorgensen *et al.* in 1997 reported the prevalence of amlodipine-induced gingival enlargement that was found to be 3.3%.[6] Several studies

reported the presence of gingival enlargement in patients receiving the dosage of 10 mg per day of amlodipine drug within the duration of two months of drug intake.[9] The reported case is of a slowly progressive chronic periodontitis case, which was superimposed by drug-induced gingival enlargement and with chronic inflammatory gingival enlargement due to the accumulation of dental plaque. Moreover, the hormonal changes that occurred due to the menopause condition of the patient also contributed to the enlargement in the maxillary and mandibular gingival tissues. Among the various old and new pharmacologic agents reported to be involved in gingival enlargement, phenytoin has the highest prevalence rate which is approximately 50%, while calcium channel blockers and cyclosporine-associated enlargements of the gingival tissues were found to be about 25%.

Marvogiannis *et al.*[10] in 2006 reported that there will be a recurrence of enlargement in the gingival tissue if the same medication is continued by the patient. Hence amlodipine was substituted with losartan 50 mg and no recurrence was noted in the patient after one year of follow-up.[10] Proper oral hygiene maintenance care by the patient also contributed to the reduction in the size of gingival enlargement. Despite the presence of similar types of dental plaque accumulation and the use of similar dosages of amlodipine drug, only a few of them become affected with gingival enlargement while others do not get affected by drug-induced gingival enlargement. The reason for such biological differences among these patients includes the presence of different types of subgroups in the patient's gingival fibroblasts. The conclusion from our study is the incidence of gingival overgrowth related to amlodipine drug is reported and the presence of dental plaque associated with gingival inflammation is an important factor, which results in the aggravation of drug-induced enlargement.

CONCLUSION

Possible alternative drugs substitution, stringent maintenance of oral hygiene, and gingivectomy surgical therapy will be the main treatment modalities for drug-associated gingival enlargement. The investigation of the factors such as the types of different subgroups of gingival fibroblast, the hormonal changes and compliance of the patient can be a guide to prevent the drug-induced gingival enlargement.

Ethical approval

The Institutional Review Board approval is not required.

Declaration of patient consent

The authors certify that they have obtained all appropriate patient consent.

Financial support and sponsorship

Nil.

Conflicts of interest

There are no conflicts of interest.

Use of artificial intelligence (AI)-assisted technology for manuscript preparation

The authors confirm that there was no use of artificial intelligence (AI)-assisted technology for assisting in the writing or editing of the manuscript and no images were manipulated using AI.

REFERENCES

1. Michael GN, Takei HH, Klokkevold PR, Carranza FA. Carranza's clinical periodontology. 11th ed. St. Louis MO: Saunders Elsevier; 2012.
2. Dongari-Bagtzoglou A, Research, Science and Therapy Committee, American Academy of Periodontology. Drug associated gingival enlargement. J Periodontol 2004;75:1424–31.
3. Srivastava AK, Kundu D, Bandyopadhyay P, Pal, AK. Management of amlodipine-induced gingival enlargement: Series of three cases. J Indian Soc Periodontol 2010;14:279–81.
4. Nyska A, Shemesh M, Tal H, Dayan D. Gingival hyperplasia induced by calcium channel blockers: Mode of action. Medical Hypotheses 1994;43:115–18.
5. Seymour RA, Ellis JS, Thomason JM, Monkman S, Idle JR. Amlodipine-induced gingival overgrowth. J Clin Periodontol 1994;21:281–3.
6. Jorgensen MG. Prevalence of amlodipine related gingival hyperplasia. J Periodontol 1997;68:676–8.
7. Nery EB, Edson RG, Lee KK, Pruthi VK, Watson J. Prevalence of nifedipine-induced gingival hyperplasia. J Periodontol 1995;66:572–8.
8. Ellis JS, Seymour RA, Thomason JM, Monkman SC, Idle JR. Gingival sequestration of amlodipine and amlodipine-induced gingival overgrowth. Lancet 1993;341:1102–3.
9. Lafzi A, Farahani RM, Shoja MA. Amlodipine-induced gingival hyperplasia. Med Oral Patol Oral Cir Bucal 2006;11:E480–2.
10. Mavrogiannis M, Ellis JS, Thomason JM, Seymour RA. The management of drug-induced gingival overgrowth. J Clin Periodontol 2006;33:434–9.

How to cite this article: Elangovan GP, Periasamy IK, Saravana KR, Ezhumalai A. Amlodipine-Induced Gingival Enlargement – A Case Report. Dent J Indira Gandhi Int Med Sci. 2024;3:65–7. doi: 10.25259/DJIGIMS_22_2023