Review Article

# First Molars in Permanent Dentition and their Malformations in Various Pathologies: A Review

*Andamuthu Yamunadevi[1], Ramani Pratibha[2], Muthusamy Rajmohan[3], Sengottaiyan Mahendraperumal[4], Nalliappan Ganapathy[1], Rajamani Srivandhana[5]*

[1]Department of Oral and Maxillofacial Pathology, Vivekanandha Dental College for Women, Namakkal, Tamil Nadu, India, [3]Departments of Oral and Maxillofacial Pathology, [4]Oral and Maxillofacial Surgery, KSR Institute of Dental Science and Research, Namakkal, Tamil Nadu, India, [2]Department of Oral and Maxillofacial Pathology, Saveetha Dental College, Chennai, Tamil Nadu, India, [5]Clinical Practitioner, Reface Dental Clinic, Erode, Tamil Nadu, India

**Submitted:** 19-Nov-2020
**Revised:** 20-Nov-2020
**Accepted:** 21-Nov-2020
**Published:** 05-Jun-2021.

**Abstract**

Permanent maxillary and mandibular first molars are the first permanent teeth to erupt into the oral cavity along with the mandibular incisors. It serves as an excellent record of maternal and fetal health, reflecting the prenatal, perinatal, and postnatal health and diseases. This review focuses on the molar morphogenesis, molar malformations, their etiopathogenesis, and pathologies causing specific pattern of molar malformations.

**Keywords:** *Enamel defects, malformations, mandibular first molar, maxillary first molar, moon's molar, permanent first molar, syphilis*

## Introduction

"Oral cavity is defined as the space from the lips to the end of the hard palate."[1] It encompasses both hard and soft tissues, of which teeth are the specialized hard tissue structures unique to the oral cavity. Like every other organs of the body, dental organ also suffers from various systemic and local diseases, during odontogenesis or in later life. Many of these pathologies impregnate their identity over the teeth permanently, since these hard tissues are relatively stable in morphology once after formation, unlike the bone which undergoes remodelling.[2] Thus, teeth are the potential reflectors of the systemic conditions and their easy accessibility through oral cavity is an added advantage.

Access this article online

Quick Response Code:

Website: www.jpbsonline.org

DOI: 10.4103/jpbs.JPBS_744_20

Human dentition includes primary and permanent dentition. The primary dentition is initiated for odontogenesis during the fourth to 6th week of intrauterine life,[2] and it bears the scars of the pathologies suffered during prenatal and initial postnatal periods. However, sooner, when the child reaches 6 years of age, the deciduous dentition starts getting replaced by the permanent dentition, which lasts for the rest of the human life. Among the permanent teeth, cusps of first

***Address for correspondence:*** Dr. Andamuthu Yamunadevi, Department of Oral and Maxillofacial Pathology, Vivekanandha Dental College for Women, Elayampalayam, Namakkal - 637 205, Tamil Nadu, India.
E-mail: yamunaoralpath@gmail.com

This is an open access article distributed under the terms of the Creative Commons Attribution-NonCommercial-ShareAlike 4.0 License, which allows others to remix, tweak, and build upon the work non-commercially, as long as the author is credited and the new creations are licensed under the identical terms.

**For reprints contact:** WKHLRPMedknow_reprints@wolterskluwer.com

**How to cite this article:** Yamunadevi A, Pratibha R, Rajmohan M, Mahendraperumal S, Ganapathy N, Srivandhana R. First molars in permanent dentition and their malformations in various pathologies: A review. J Pharm Bioall Sci 2021;13:S23-30.

molars are the one that show the signs of calcification at birth. Thus, permanent first molars and all primary teeth provide information on intrauterine development and on the first 1000 days postnatally, providing a direct window on maternal and fetal health.[3] Thereby, even though deciduous teeth are lost, the first molars in permanent dentition are retained for a longer span of life and their evaluation aids the dentist enormously for clinical data.

Considering the significance of first molars as an important diagnostic aid, this review is focused on the pathologies associated with the morphological alterations in permanent first molars.

## Morphology and Morphogenesis of Maxillary and Mandibular First Molars

Permanent maxillary first molars are rhomboidal or diagonal in shape with four major cusps and one supplementary cusp, namely cusp of Carabelli, located palatally 2 mm below the mesiopalatal cusp. Their roots are three in number, including the single largest palatal root and two buccal roots. Mandibular molars are usually rectangular shaped teeth with five cusps, including three buccal cusps and two lingual cusps. Two roots are present mesiodistally. At times, four cusped mandibular molars are seen, with the absence of the distal most cusp.[3]

The formation of the maxillary and mandibular molars begins with the interaction of the oral epithelium with the underlying ectomesenchyme derived from first pharyngeal arch. The proximity of the ectomesenchyme to the oral epithelium is the key inductive signal for the further molecular events. The location and pattern of future teeth are molecularly predetermined even before any morphological signs of tooth formation are evident.[2]

Odontogenesis is unique from morphogenesis of other parts of the body, since teeth have different shapes according to their position in the jaws, whereas most other organs of our body undergo only a single program of morphogenesis genetically.[4] The variation in their morphogenesis is regulated by the autonomous regional specificity (as encoded in homeobox genes) and nonautonomous morphoregulators (e.g., activity of secreted signaling molecules).[5]

Molecular insight into odontogenesis reveals the active involvement of major signaling families, namely, fibroblast growth factor (FGF), transforming growth factor- β (TGF-β), Wingless-related integration site (Wnt), Sonic Hedgehog (Shh) that secretes the signaling molecules for the expression of various transcription factors like the members of Msx, Pax, and Runx families. FGF8 from the lateral oral epithelium and bone morphogenetic protein-4 (BMP4) from the medial oral epithelium differentially regulates the expression of *Dlx1, Dlx 2,* and *Barx 1* laterally and *Msx 1* and *Msx 2* medially, and this represents the "Odontogenic homeobox code" for tooth identity.[2,5]

Till E11.5, the instructive information for odontogenesis resides in the epithelium and this is common to all the tooth types. The differentiation in morphogenesis of unicuspid and multicusped teeth begins after this. After the bud stage, the underlying ectomesenchyme takes up the instructing role and expresses the transcription factors Msx1, Pax9, and Runx2, promoting the expression of growth factors Bmp4, Fgf3, and Wnt5a. These growth factors in turn act upon the inner enamel epithelium to form morphologically distinct, densely packed, nonproliferating epithelial cells called enamel knot. Further epithelial morphogenesis and growth of the underlying ectomesenchyme during the cap and bell stage are controlled and coordinated by this enamel knot.[2,5]

The primary enamel knot is formed at the center of the tooth germ during early bell stage[6] and gets eliminated by subsequent apoptosis.[7,8] The secondary enamel knots are formed at the cuspal tips and send signals to control the later aspects of cusp morphogenesis[9] [Figure 1a].

After crown formation, in the advanced bell stage, the enamel organ cervically exhibits bilayered Hertwig's epithelial root sheath that grows apically to determine the root shape.[2]

Abnormalities in the size and shape of the tooth arise from the disturbances in the above morphodifferentiation (cap-bell) stage of tooth development.[2]

## Critical Genetic Pathways IN Molar Morphogenesis

To initiate enamel knot formation and further morphogenesis in bud stage, all the tooth buds have an absolute requirement for mesenchymal to inner enamel epithelial BMP signal.[4] Different levels of BMP are required for the regulation of cusp patterns in different tooth types. BMP protein is secreted by the expression of transcriptional factor Msx 1 in ectomesenchyme [Figure 1a]. Lack of BMP signal or mutation in BMP epithelial receptor or mutation in Msx1 transcription factor in mesenchyme arrest tooth development at this bud stage itself.[2,4]

Pax9 and Barx1 proteins interact with Msx1 to regulate Bmp4 protein secretion. Pax9-Msx1 interaction is seen in all tooth types (both unicusped and multicusped teeth), but Barx1-Msx1 interaction is unique to multicusped

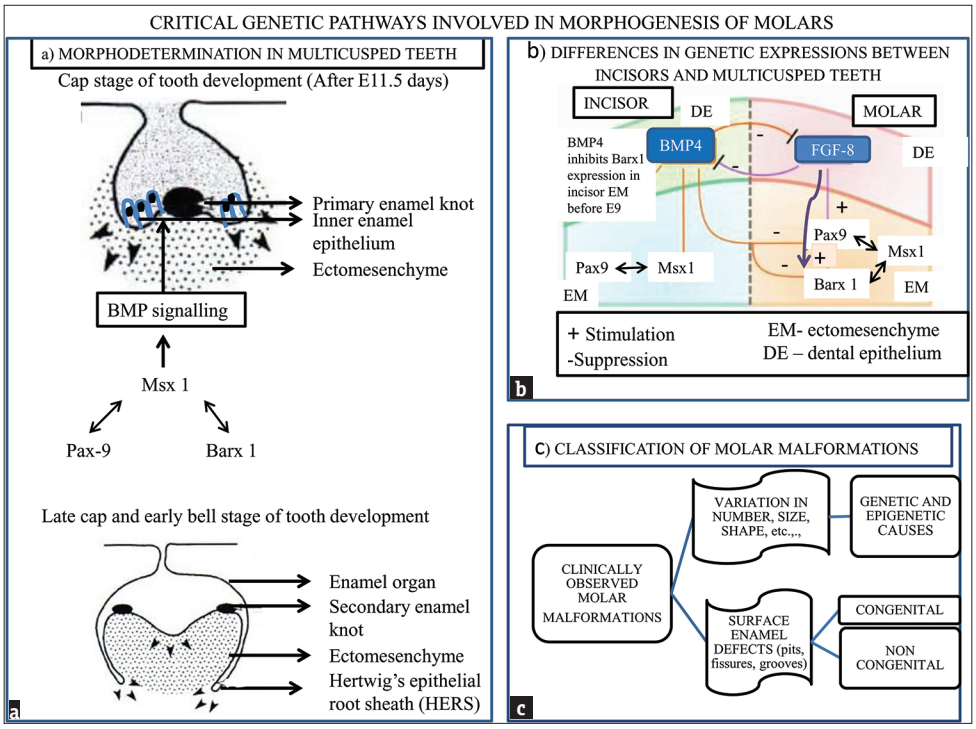


**Figure 1:** Critical genetic pathways involved in morphogenesis of molars (a) morphodetermination in multicusped teeth (b) differences in genetic expressions between incisors and multicusped teeth (c) classification of molar malformations

teeth [Figure 1b]. Thus, Barx1 is exclusively expressed only in the ectomesenchyme of molars and premolars and when Barx1 activity is lost, (e.g., Due to any infection or mutation), the resulting suboptimal levels of BMP (due to Msx1-Pax9 interaction and other factors) is not sufficient to induce appropriate levels of primary enamel knot signaling and can lead to complete arrest of tooth formation at bud stage itself.[2,4]

Before E9, Bmp4 inhibits Barx1 expression in the presumptive incisor mesenchyme. In contrast, Barx1 expression is stimulated by Fgf8 in the presumptive molar mesenchyme. If Bmp activity is experimentally downregulated before E9 in incisor ectomesenchyme, incisors transform into molars.[10]

## Molar Malformations

Clinically, permanent mandibular and maxillary molars can have various malformations such as change in number (absence of teeth and supernumerary teeth), size (increase or decrease in size), or shape (absence or presence of extra cusp(s), root(s), pit(s), groove(s), mineralisation defects, taurodontism, concrescence, fusion of roots, etc.,).[11]

These defects can be localized, generalized, or associated with craniofacial abnormalities and/or syndromes. Furthermore, they can be prenatal or postnatal in origin. For better visualization of the pathogenesis, we classify these malformations as (1) phenotypic changes caused by genetic and epigenetic variations and (2) malformations caused by defective enamel structures [Figure 1c].

## Etiopathogenesis of Molar Malformations

### Phenotypic changes caused by genetic and epigenetic variations

Genetically, various signaling pathways (Wnt, Shh, etc.,), growth factors (Fgf8, epidermal growth factor, Tgfβ1, Bmp2, Bmp4, etc.,), and transcription factors (Lef1, Pax9, Msx1, Msx2, etc.,) play key roles during the various phases of odontogenesis, and the diversification of dentition is brought by the modulation of their activities, timings of these signaling pathways, and differences in requirements by various tooth primordia.[12] Various genetic deregulations play a major role in hypodontia, hyperdontia and abnormal size, patterning and location of tooth.

For example, Pax9 is the earliest marker to mark the site for future tooth development. It results from the antagonistic expression of FGF and BMP signaling. Fgf8 induces Pax9 expression and in contrast, Bmp2 and Bmp4 inhibit the expression [Figure 1b]. Thus, Pax 9 is expressed in areas where Fgf 8 is present, but Bmp2 and Bmp4 are absent. Loss of Pax9 expression causes human hypodontia. Pertaining to it, overexpression of Fgf ligands or downregulation of Bmp signaling results in supernumerary teeth.[5]

These major signaling pathways (Shh, Bmp, Fgf, Notch, Wnt pathways, etc.) are shared commonly

during the organogenesis of other ectodermal appendages, including hair, nails, sweat glands, mammary glands, etc. Modulation in these signaling pathways can affect multiple ectodermal organs, depending on timing and internal control of organogenesis.[12] e.g.,: Trichodento osseous syndrome, ectodermal dysplasia.

Furthermore, epigenetic changes can alter the phenotype of the tooth organ without genetic alteration.[13]

Teeth show organ-autonomous regulation of morphogenesis. Thus, though odontogenesis is a complex process, any minor delay or defect in secretion of signaling molecules is well balanced and ensures coordination of further odontogenesis without any defects.[4] Therefore, genetically altered malformations are less common in occurrence than that of enamel structural defects.

## Pathogenesis behind enamel defects observed in molar malformations

Minor structural defects such as pits, fissures, ridges, grooves, furrows, mineralization defects, etc., are common in molars and are formed mainly due to external factors such as infection, malnutrition, etc., more than by genetic alterations.

Eames in 1884,[14] gave an elaborate view on origin of these minor enamel defects [Figure 2]. He classifies these enamel defects under two categories depending on their origin as, (1) Congenital (defects arising during the formative period of tooth) and (2) Non-congenital or accidental (defects arising after the complete tooth formation). He explains that pits are due to the death of the ameloblasts and fissures are due to the separation of ameloblastic layer. The highly differentiated cells like ameloblasts are very sensitive to systemic and local factors, and they easily undergo these changes.[14]

Pits are described microstructurally as "an opening surrounded by enamel rods and the bottom clothed with enamel" by Wedl.[14] Here the number of missing enamel rods corresponds to the number of missing ameloblasts. If the ameloblasts die when amelogenesis (amelification as said by Eames) begins, then these circular pits extend from the surface of the enamel to the underlying dentin surface [Figure 2b]. When the ameloblasts die in the midway between amelogenesis, then the depth of the pits correspond to the length of unfinished rods [Figure 2a]. Later after eruption, these pits are externally acted by acids, bacteria, etc., and get filled with pigment, food debris, etc., When the wall of these pits breaks, the pit forms a pouch or cul-de-sac.[14]

Fissures or grooves in coronal surfaces of molars and premolars are very common and are initially described as due to failure of the part of enamel plate to meet and coalesce, during development from the cusp towards the centre. Dr. Black clarifies, it is not due to failure to coalesce but due to rupture of the enamel organ at a point, causing separation of ameloblastic layer, thereby separating rods and forming fissures.[14]

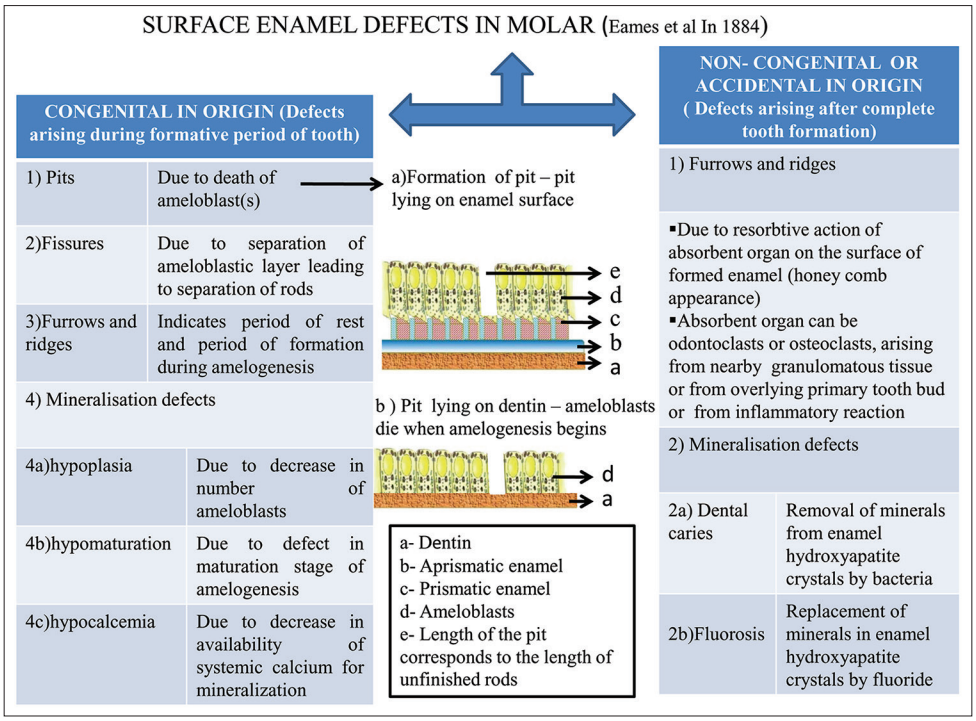


**Figure 2:** Classification of enamel structure defects – Eames *et al.* 1884

In noncongenital deformities (second category, where deformity is formed after completion of tooth formation), the defects are due to the resorptive action of the absorbent organ (odontoclasts or osteoclasts) on formed enamel, forming honey–combed and furrowed teeth (incisors and first molars more commonly). The contrary theory is also discussed that these furrows and ridges can be congenital in origin, where furrows indicate period of arrest and ridges indicate period of development.[14] In few systemic conditions, these ridges and furrows are relatively similar in permanent incisor and first molar, because both of these tooth germs faces common disturbance in the same time of development.[14]

Mineralisation defects seen on the enamel surface can be congenitally due to either decrease in number of ameloblasts (hypoplasia), or defect in the maturation stage of amelogenesis (hypomaturation) or due to decrease in the availability of systemic calcium for mineralization (hypocalcemia).[11] After tooth eruption, it can be due to dental caries or fluorosis or other factors.[11] It is claimed that caries is very common in deciduous dentition of patients with few congenital diseases (e.g.,: syphilis) than normal population because the quality of enamel rods are very poor and are hypomineralised, making the teeth vulnerable for dental caries.

## Molar Malformations in Various Systemic Diseases

The etiologies behind the molar malformations that cause genetic and epigenetic variations, and enamel structural defects are varying and commonly enlisted are (1) Infections (2) Syndromes (3) Endocrine dysfunctions (4) Malnutrition (5) Systemic diseases (6) Craniofacial anomalies (7) Local factors like trauma.[11] The pathologies causing unique pattern of molar malformations are discussed below.

### Congenital syphilis

Syphilis is an infectious disease caused by the spirochete, Treponema Pallidum, affecting the human being from any time between 4$^{th}$ month of intrauterine life to till death.[15] It is transmitted by sexual activity, abraded mucous membrane through saliva or abraded skin.[15,16] Congenitally, it can be transmitted to the foetus only from mother, and foetus can never inherit the disease from father, without mother being infected.[16]

The dental stigmata of congenital syphilis includes Hutchinson's incisors (6%–23%) and Moon's molar (3%–37%).[17] Also known as Fournier molar, Mulberry molar, bud molar, this syphilitic molar was first described by Moon (1876–1877)[18] as "small, dome shaped, devoid of definite cusps, the coronal surface consisting of an irregular honeycomb pattern." Fournier emphasized this cuspal hypoplasia in first molars are pathognomonic of hereditary syphilis and hence also known as Fournier's molar. On the occlusal table, the enamel shows unduly prominent upward bulging like a shoulder, surrounding the crown of the tooth. Inside this shoulder like margin, four defective and dwarfed cusps are seen.[18] These hypoplastic cusps undergo decay very rapidly, resulting in cross-ribbing, causing mulberry appearance as described by Moon. The degree of deformity varies and if treated at the earlier stage, during first 2 years immediately after birth, these dental stigmata can be prevented. Mercury was employed for treating syphilis in earlier days and mercury itself in turn caused hypoplasia and pitting in first molars, resembling syphilitic molars very closely. In mercury hypoplasia, the enamel is deficient, but not so in Moon's molars. Syphilitic first molars also should be clinically distinguished from stomatitic tooth by the fact that stomatitic tooth have harder, rugged, well defined margins unlike soft, worn and rounded syphilitic molars. Cusp of Carabelli in maxillary first molars was initially related to congenital syphilis, but later it was disproved.[18]

### Pathogenesis of syphilitic molars

Once spirochetes enter the body through the skin, it enters the lymphatic system and reaches the blood stream, through which it spreads throughout the body.[17] When the mother is infected, the organism can enter the fetus only after 4 months through the placenta because placental formation completes only during 12$^{th}$ week of pregnancy and till then the fetus is nourished by the yolk sac itself, where the organism cannot be transmitted [Figure 3].[17]

Theoretically, syphilis can alter morphology of tooth germs only before the calcification begins.[17] Since the deciduous teeth have initiated calcification by 4 months,[3] they didn't undergo remarkable morphological variations like permanent teeth, but are prone to dental caries attack due to mineralization defects in enamel rods caused by spirochete and resulting softer enamel.[17,18]

The spirochete once after reaching the permanent tooth germ, causes the characteristic 'syphilitic molar' by initially inducing inflammatory reaction and vasculitis. Because of this, exudate surrounds the tooth buds causing edematous connective tissue. Within the tooth bud, hydropic degenerative changes are evident in the enamel epithelium, stellate reticulum, and ameloblasts.[19] The granular cytoplasm of the ameloblasts swells and ruptures due to the hydropic degeneration causing partial or complete destruction

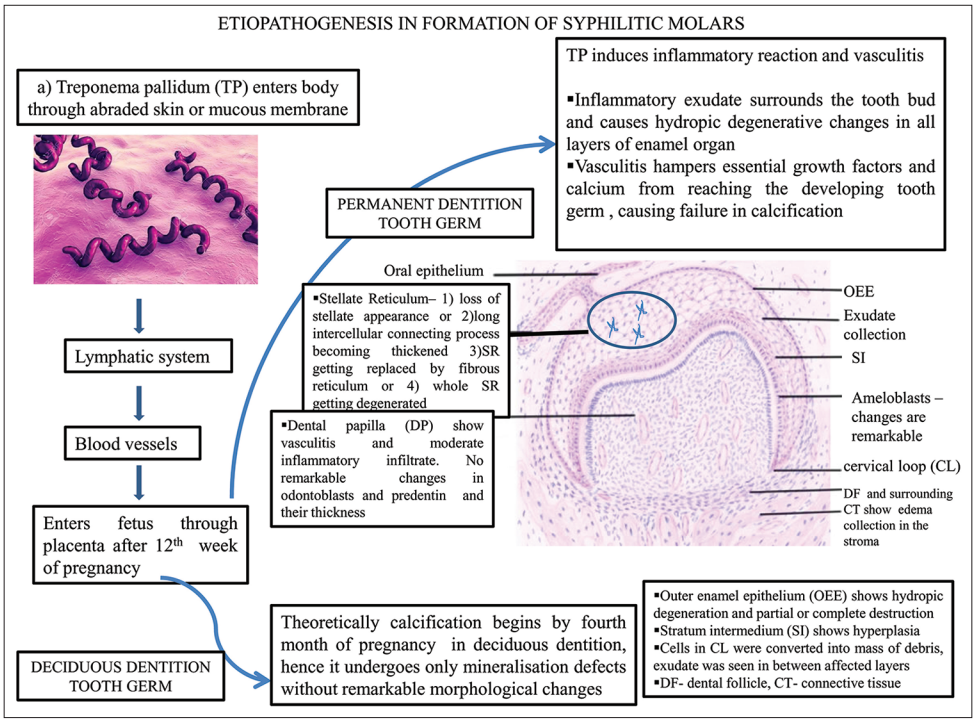


**Figure 3:** Etiopathogenesis in the formation of syphilitic molars

of ameloblasts and occasionally exudate collects between the formed enamel and ameloblasts, causing detachment. The partially damaged ameloblasts secrete globular deposition of abortive enamel, whereas completely destroyed ameloblasts cause stunted enamel production thereafter [Figure 4].[19] Because of vascular obstruction, calcium and other essential growth factors are hampered from reaching the developing tooth bud, causing failure in calcification. Because of these changes, mulberry molars result and the middle part of the crown suffers more distortion (both in Moon's molars and Hutchinson's incisors) because the center part of the tooth germ receives comparatively lesser blood supply than the surrounding part.[17,18]

## Molar incisor hypomineralisation

Molar incisor hypomineralisation (MIH) is defined as "a specific dental enamel defect of systemic origin affecting atleast one permanent molar and often also permanent incisor." Here the defective enamel has significantly increased protein content since the ameloblasts in the later mineralization phase gets disturbed due to the synergetic action of systemic and genetic factors.[20] In permanent first molars, calcification begins around 9th month in utero and during birth, their cuspal tips get calcified. Similarly incisors get calcified after birth. Hence, any prenatal, perinatal and postnatal complications (occurring between the end of second trimester and 4 years of age), related to their mineralisation can cause MIH (occurrence rate–3.6%–25%). In prenatal period–maternal illness and psychological stress during pregnancy (because of malnutrition and sleep deprivation during stress) are proved to cause MIH. During the perinatal period, cesarean section and other delivery complications can induce MIH because of resulting hypoxia in child. Postnatal factors include respiratory illnesses (e.g.,: asthma and pneumonia), fever, and childhood illnesses.[20]

## Molar incisor malformation/molar root incisor malformation

Molar incisor malformation (MIM) is identified radiographically by the presence of underdeveloped, short, narrow, spiky roots in permanent first molars, and less often in permanent central incisors also. Lee *et al.* named it as MIM. It has many similarities with MIH in etiology, tooth, and age of occurrence. It can lead to tooth devitalization, abscess formation, and subsequent bone loss, henceforth early diagnosis with radiographs is recommended.[21]

## Hypophosphatasia

Loss of function mutation in tissue nonspecific alkaline phosphatase gene in hypophosphatasia causes the accumulation of inorganic pyrophosphate extracellularly and inhibits dentin and bone mineralization, causing rickets and osteomalacia. Molars exhibit short roots with thin dentin and aplastic/hypoplastic acellular cementum. Early tooth loss due to defective tooth attachment with alveolar bone is common.[22]

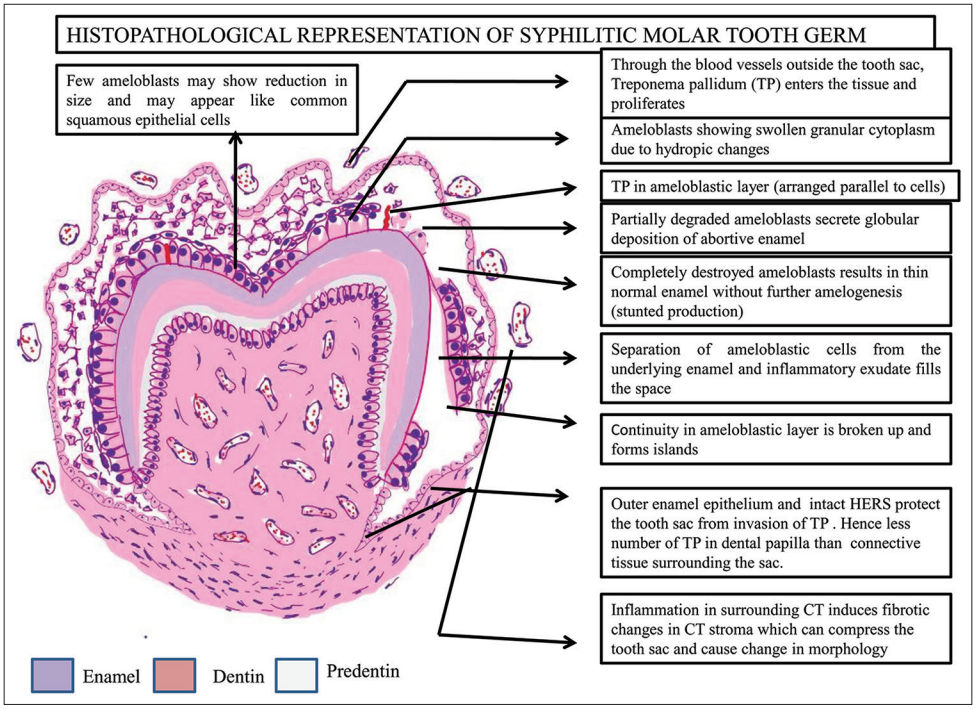


**Figure 4:** Histopathological representation of syphilitic molar tooth germ

**Table 1: Syndromes associated with molar malformations**

| Syndrome | Molar malformations |
|---|---|
| Otodental syndrome/otodental dysplasia[24] | Globodontia – enlarged bulous malformed molars with almost no discernable cusps or grooves |
| Autoimmune lymphoproliferative sydrome[25] | Permanent first molar root –incisor malformation |
| Schimke Immuno-osseous Dysplasia[26] | Permanent first molar root hypoplasia |
| Klinefelter's sydrome[11] | Taurodontism |

### Diabetes mellitus

In Type 1 diabetes mellitus, the presence of six cusps and four cusps in mandibular first molars, prominent cusp of Carabelli in maxillary molars are observed.[23] Animal studies have shown that hyperglycemic environment affects the phenotype of resulting teeth by epigenetic alterations.[13]

### Syndromes

The syndromes affecting first molars are enlisted in Table 1.[11,24-26]

Along with these, molar also undergoes generalized malformations similar to all other permanent teeth during developmental disturbances (amelogenesis imperfecta, dentin dysplasia), endocrine dysfuctions (hypo/hyper thyroidism and hypo/hyper parathyroidism), infections (measles), and local changes (e.g.,: Turner's hypoplasia). Thorough clinical examination and medical history can reveal the underlying pathology. It might be no wonder, if we come across coronamolars because of this prevailing covid era, for which we have to wait for 6 more years.

## Conclusions

Permanent first molars are potential and longstanding reflectors of prenatal, perinatal, and postnatal health. Furthermore, maternal health during pregnancy can be studied. Careful clinical examination of these efficient, cost-effective diagnostic tool helps in prevention, early diagnosis, and effective treatment for various pathologies. Various molecular level studies on these molars will be fruitful in future prospective.

### Financial support and sponsorship

Nil.

### Conflicts of interest

There are no conflicts of interest.

## References

1. Oral Cavity – An overview. Bernard A Cohen. Pediatric dermatology. 4th ed. China:Saunders, Elsevier; 2013.
2. Kumar GS. Orban's Oral Histology and Embryology. In: Kumar GS, Bhaskar SN, editors. 14th ed. New Delhi, India: Elsevier Publications; 2015.
3. Ash M. Wheeler's Dental Anatomy, Physiology and Occlusion.

7th ed. Philadelphia: WB Saunder's Company; 1993.
4. Miletich I, Yu W, Zhang R, Yang K, Andrade S, Perena S, *et al*. Developmetal stalling and organ autonomous regulation of morphogenesis. PNAS 2011;108:19270-5.
5. Klein OD, Oberoi S, Huysseune A, Hovorakova M, Peterka M, Peterkova R. Developmental disorders of the dentition: An update. Am J Med Genet C Semin Med Genet 2013;163C: 318-32.
6. Jernvall J, Kettunen P, Karavanova I, Martin LB, Thesleff I. Evidence for the role of the enamel knot as a control center in mammalian tooth cusp formation: Non-dividing cells express growth stimulating Fgf-4 gene. Int J Dev Biol 1994;38:463-9.
7. Lesot H, Vonesch JL, Peterka M, Turecková J, Peterková R, Ruch JV. Mouse molar morphogenesis revisited by three-dimensional reconstruction. II. Spatial distribution of mitoses and apoptosis in cap to bell staged first and second upper molar teeth. Int J Dev Biol 1996;40:1017-31.
8. Vaahtokari A, Aberg T, Thesleff I. Apoptosis in the developing tooth: Association with an embryonic signaling center and suppression by EGF and FGF-4. Development 1996;122:121-9.
9. Jernvall J, Aberg T, Kettunen P, Keranen S, Thesleff I. The life history of an embryonic signaling center: BMP-4 induces p21 and is associated with apoptosis in the mouse tooth enamel knot. Development 1998;125:161-9.
10. Tucker AS, Matthews KL, Sharpe PT. Transformation of tooth type induced by inhibition of BMP signaling. Science 1998;282:1136-8.
11. Neville BW, Damm DD, Allen C, Bouquot JE. Oral and Maxillofacial Pathology. 2nd ed. Philadelphia; WB Saunders Company; 2002.
12. Plikus MV, Zeichner-David M, Mayer JA, Reyna J, Bringas P, Thewissen JG, *et al*. Morphoregulation of teeth: Modulating the number, size, shape and differentiation by tuning Bmp activity. Evol Dev 2005;7:440-57.
13. Yamunadevi A, Pratibha R, Rajmohan M, Ganapathy N, Porkodisudha J, Pavithrah D, *et al*. Molecular insight into odontogenesis in hyperglycemic environment: A systematic review. J Pharm Bioallied Sci 2020;12:S49-56.
14. Eames H. The origin of defective enamel. Am J Dent Sci 1884;18:194-204.
15. Fitzgerald F. The great imitator, syphilis-Medical Staff Conference, University of California, San Francisco. West J Med 1981;134:424-32.
16. Harlan AW. Characteristics of saliva in syphilis. Am J Dent Sci 1981;2:8-17.
17. Bernfeld WK. Hutchinson's teeth and early treatment of congenital syphilis. Brit J Vener Dis 1971;47:54-6.
18. Cruickshank G. The dental stigmata of congenital syphilis. Proceedings of the royal society of medicine; section of odontology. Proc R Soc Med 1939;32:343-8.
19. Bauer H. Tooth buds and jaws in patients with congenital syphilis. Correlation between distribution of *Treponema pallidum* and tissue reaction. Am J Pathol 1944;20:297-317.
20. Fatturi A, Wambier L, Chibinski A, Assuncao L, Brancher J, Reis A, *et al*. A systematic review and meta-analysis of systemic exposure associated with molar incisor hypomineralization. Community Dent Oral Epidemiol 2019;47:407-15.
21. Kim JE, Hong JK, Yi WJ, Heo MS, Lee SS, Choi SC, *et al*. Clinico-radiologic features of molar-incisor malformation in a case series of 38 patients: A retrospective observational study. Medicine (Baltimore) 2019;98:e17356.
22. McKee MD, Nakano Y, Masica DL, Gray JJ, Lemire I, Heft R, *et al*. Enzyme replacement therapy prevents dental defects in a model of hypophosphatasia. J Dent Res 2011;90:470-6.
23. Yamunadevi A, Basandi PS, Madhushankari GS, Donoghue M, Manjunath A, Selvamani M, *et al*. Morphological alterations in the dentition of type I diabetes mellitus patients. J Pharm Bioallied Sci 2014;6:S122-6.
24. Bloch-Zupan A, Goodman JR. Otodental syndrome. Orphanet J Rare Dis 2006;1:5.
25. Pavlic A, Vrecl M, Jan J, Bizjak M, Nemec A. Case report of a molar-root incisor malformation in a patient with an autoimmune lymphoproliferative syndrome. BMC Oral Health 2019;19:49.
26. Morimoto M, Kerouredan O, Gendronneau M, Shuen C, Baradaran-Heravi A, Asakura Y,et al. Dental abnormalities in Schimke immuno-osseous dysplasia. J Dent Res 2012;91:29S-37S.