[Downloaded free from http://www.jpbsonline.org on Friday, June 21, 2019, IP: 103.58.116.141]

A simple method of enhancing retention in interim hollow bulb obturator in a case of an acquired palatal defect

S. Karthikeyan, K. Balu, V. Devaki, R. Ajay

Department of Prosthodontics, Vivekanandha Dental College for Women, Tiruchengode, Tamil Nadu, India

Address for correspondence:
Dr. S. Karthikeyan,
E-mail: drkarthikprostho@gmail.com

Received : 28-04-15
Review completed : 28-04-15
Accepted : 22-05-15

ABSTRACT

Maxillary defects occur either as a result of surgical resection of malignant tumors of the nasal cavity and paranasal sinuses or of the congenital causes. Rehabilitation of the patients with maxillectomy defects presents a challenge in restoring the lost form, function and speech. Maxillary interim obturators in prosthetic reconstruction of the defects are often complicated with lack of adequate retention, stability, and support. This case report presents the simplified approach, to rehabilitate a case of sub-total maxillectomy due to squamous cell carcinoma of maxillary sinus, using a closed hollow bulb obturator prosthesis fabricated with a "U" loop and a modified buccal flange for enhanced retention of the prosthesis.

KEY WORDS: Acrylic resin mask, enhanced retention, hollow bulb obturator, modified buccal flange, partial maxillectomy, stability, support, "U" loop

Maxillary defects may be acquired or congenital. Patients who either have had undergone surgical resection of neoplasms or as a result of severe trauma has acquired maxillofacial defects. Maxillary defects cause communication between the oral cavity, nasopharynx, nasal cavity, maxillary sinus. As result, these structures turn as one confluent chamber predisposing to hypernasal speech and difficulty in mastication and deglutition. The patient is also predisposed to psychological depression from cosmetic deformities that affect life quality depending upon severity.[1] The prosthetic rehabilitation of total and partial maxillectomy patients with a maxillary obturator is aimed at separation of oral and nasal cavities to restore normalcy in deglutition, speech, orofacial appearance, and occlusion.

A definitive obturator is not indicated until the surgical site is healed and stable dimensionally. An interim closed hollow bulb obturator prosthesis extending into the defect area is normally placed seven to 10 days postsurgery. It is crucial to reline the obturator periodically with tissue conditioners to aid in healing and stability of the surgical site. The weight *per se* acts as a dislodging factor for maxillary dentures with obturator and the gravitational force adds to it.[2] In turn, obtaining acceptable oroantral seal is difficult and predisposes to traumatic occlusion under function. The success of the rehabilitation becomes more predictable when natural teeth remain.[2-5]

This case report describes a simple method of enhancing the retention and to minimize the rotation of interim closed hollow bulb prosthesis by modified buccal flange with "U" loop in a partially dentate patient.

Case Report

A 35-year-old woman reported to the Department of Prosthodontics, to restore the palatal defect after maxillectomy. She had been resected her anterior maxilla on the left side leaving alone the posterior alveolus with dentition, due to squamous cell carcinoma of antrum of high more. Her chief

Access this article online

Quick Response Code:

Website: www.jpbsonline.org

DOI: 10.4103/0975-7406.163561

This is an open access article distributed under the terms of the Creative Commons Attribution-NonCommercial-ShareAlike 3.0 License, which allows others to remix, tweak, and build upon the work non-commercially, as long as the author is credited and the new creations are licensed under the identical terms.

For reprints contact: reprints@medknow.com

How to cite this article: Karthikeyan S, Balu K, Devaki V, Ajay R. A simple method of enhancing retention in interim hollow bulb obturator in a case of an acquired palatal defect. J Pharm Bioall Sci 2015;7:S782-5.

© 2015 Journal of Pharmacy And Bioallied Sciences | Published by Wolters Kluwer - Medknow

[Downloaded free from http://www.jpbsonline.org on Friday, June 21, 2019, IP: 103.58.116.141]

complaint was difficult to proper deglutition and clear speech, thereby requiring prosthesis to restore her lost teeth and function.

Dental history revealed that she had undergone resection of left maxilla crossing midline until first molar region as a surgical treatment of squamous cell carcinoma of the maxillary antrum. The patient had disfigured face due to unsupported left labial and stretched philtrum regions [Figure 1]. Intraorally, the postsurgical defect had oronasal continuity and extent of the defect was from the buccal sulcus to the mid-palatine region medially and anteriorly from the labial sulcus to the first molar region posteriorly, leaving the posterior alveolus intact with second and third molars with proper intercuspation [Figure 2]. The treatment plan was to fabricate an obturator prosthesis that would be light and easy to wear, adequately retentive for her to resume oral functions.

Technique

A two-stage impression compound – alginate wash impression was made using perforated stock tray. Initially, the compound impression was limited to record the area of the defect, followed by secondary alginate impression to record fine details of defect area along with remaining dento-alveolar structures.

The impression was boxed and poured with dental stone, and unfavorable undercuts on the master cast were blocked [Figure 3]. Bite registration was done with wax occlusal rims over a temporary denture base and transferred to the articulator for completion of teeth arrangement. The trial denture was checked for the esthetics and functional occlusion [Figures 4 and 5].

Fabrication of labial bow with "U" loop and modified buccal flange

A labial bow was fabricated, wrapping from mesial of right lateral incisors and a "U" loop provision in the canine region placed in vestibule. Distal to "U" loop, a zigzag wire bending for 1.5 inch length was given in the bow that ends on the distal side of the second molar. The wax-up was done after securing the labial bow to the cast with trial denture in place. The wax-up for the buccal flange was done encasing the zigzag portion of the bow extending up to cervical portion of the posteriors, will act as acrylic resin mask with collars encircling the posterior teeth [Figure 6].



Figure 1: Unilateral facial disfigurement due to partial maxillectomy



Figure 2: Postsurgical intra oral defect

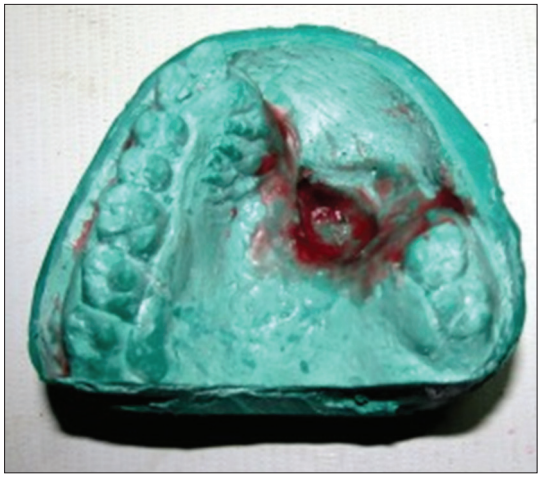

Figure 3: Master cast showing defect boundaries



Figure 4: Trial denture displaying anterior teeth

[Downloaded free from http://www.jpbsonline.org on Friday, June 21, 2019, IP: 103.58.116.141]

Processing

The trial denture [Figure 6] was invested, dewaxed and mold space was packed with heat-cure acrylic resin where the defect area was packed using salt sandwich method. The flask curing was done subjected to regular curing cycle. Following deflasking procedure, the bulb was placed two holes to flush the salt packed to create the hollow bulb. The prosthesis was trimmed, finished and polished [Figure 7]. The holes in the bulb were closed with autopolymerizing resin before denture insertion.

The insertion of prosthesis was done. Clinically, adequate retention, stability, and support were present. The patient reported the esthetics, deglutition was satisfactory, and hypernasal speech was eliminated [Figure 8 and 9]. At every 2 weeks follow-up interval, comfortable functioning of the interim obturator was ensured. The U-shaped bend in the labial bow can be activated during subsequent recalls to maximize retention if necessary. Definitive obturator was planned to perform later date; when healed, stable defective site is present.



Figure 5: Trial denture evaluated for centric occlusion



Figure 7: Processed interim obturator

Discussion

Rehabilitation of acquired maxillary defects often possesses a great challenge, and the goals are usually achieved by means of various micro-vascularised flaps or by prosthetic intervention. Reconstructive surgeries are done when extensions of the defects are small. Prosthetic rehabilitation seems to be a better alternative for larger defect and the prosthesis that is, fabricated to repair the defect is called as a maxillary obturator.

The obturator is that component of a prosthesis which fits into and closes a defect within the oral cavity or other body defects.[6] Depending upon the period elapsed from surgical resection of maxilla, the obturator can be of three types: Surgical, interim or definitive obturator. A definitive obturator is not indicated until the surgical site is healed and dimensionally stable and the patient is prepared physically and emotionally for the restorative care that may be necessary.[7]

Interim obturator prosthesis is normally placed 7–10 days after surgery. Dimensional changes will continue to occur for at least 6 months secondary to scar contracture and further organization of the wound.[8] The prosthesis may be relined to compensate for continued alteration in tissues. Alterations in tissues that support a maxillofacial prosthesis may be more rapid than in tissues supporting a more conventional denture.



Figure 6: Labial bow "U" loop and modified buccal flange in wax-up stage

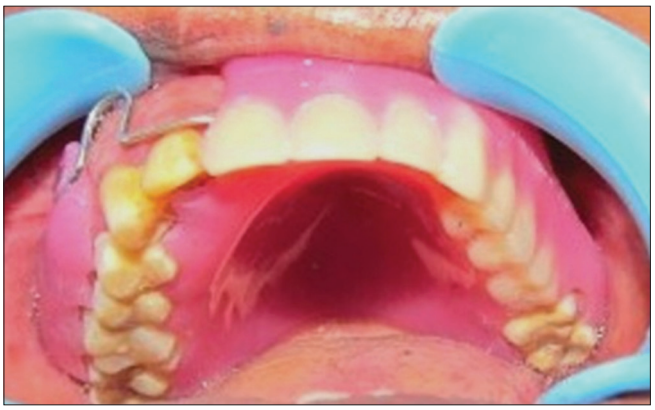

Figure 8: Intraoral view after insertion

[Downloaded free from http://www.jpbsonline.org on Friday, June 21, 2019, IP: 103.58.116.141]



Figure 9: Posttreatment improvement in facial appearance

Hence, reevaluation of the occlusion and base adaptation must be periodical and corrections if any, done by selective grinding of the occlusion or refitting the base of the prosthesis.[9] Different materials such as Silicone rubber and visible light-polymerized resin have been used for the fabrication of the hollow obturator prosthesis. However, the durability of heat-processed acrylic resin has been proven as a compatible material for tissues to date for the fabrication of this prosthesis.[10]

The postsurgical tissue changes in the resected area posed problem in maintaining the retention and stability of the interim obturator prostheses. Contraction of the scar necessitates periodic additions of reliners/tissue conditioners to the interim obturator. This adds weight to the prosthesis and acts as dislodging forces apart from forces of gravitation. Dislodging forces can overcome by placing labial bow with "U" loop and modified buccal flange on contralateral side of the defect, providing retention and cross arch stabilization to the prosthesis.

Advantage of "U" loop and modified buccal flange

The advantage of the "U" loop is that the vertical arms of "U" can be compressed periodically like a simple Hawley's retainer to enhance retention of the prosthesis counteracting dislodging factors.

The buccal flange acts as acrylic resin mask and functions to prevent rotation of the prosthesis and provides cross arch stability. The resected part of tissue is replaced by obturator prosthesis; *per se* obturator's weight is balanced bilaterally by acrylic resin mask on the contralateral side of the defect and by the resin collars encircling the posterior teeth remaining on the defect side. The incorporated design feature would be a great adjunct in retaining the interim obturator and to avoid prosthesis remake due to retention failures in the healing period.

Conclusion

The most challenging part in rehabilitating the patient with hemimaxillectomy is achieving adequate retention and stability of the prosthesis. The purpose of this simple design was to solve these challenges and to avoid remake of interim obturator during progression of tissue healing. A hollow bulb design for the obturator was chosen in order to reduce the bulk of the prosthesis that in turn made it lightweight and more comfortable for the patient. The primary objective of restoring aesthetics, speech, mastication, and deglutition was achieved.

Financial support and sponsorship

Nil.

Conflicts of interest

There are no conflicts of interest.

References

1. Chalian VA, Drane JB, Standish SM. Maxillofacial Prosthetics. Multidisciplinary Practice. Baltimore: The Williams and Wilkins Co.; 1971. p. 133-48.
2. Frame RT, King GE. A surgical interim prosthesis. J Prosthet Dent 1981;45:108-10.
3. Curtis TA, Beumer J 3rd. Restoration of acquired hard palate defects: Etiology, disability, and rehabilitation. In: Beumer J, Curtis TA, Marunick MT, editors. Maxillofacial Rehabilitation: Prosthodontic and Surgical Considerations. St. Louis: Ishiyaku Euro America; 1996. p. 225-84.
4. Kouyoumdjian JH, Chalian VA. An interim obturator prosthesis with duplicated teeth and palate. J Prosthet Dent 1984;52:560-2.
5. Wolfaardt JF. Modifying a surgical obturator prosthesis into an interim obturator prosthesis. A clinical report. J Prosthet Dent 1989;62:619-21.
6. Glossary of Prosthodontic Terms (GPT). GPT-8. The academy of prosthodontics. J Prosthet Dent 2005;94:56.
7. Beumer J, Curtis TA, Firtell DN. Maxillofacial Rehabilitation. Prosthodontic and Surgical Considerations. St. Louis, Toronto, London: The C.V. Mosby Co.; 1979. p. 188-243.
8. Keyf F. Obturator prostheses for hemimaxillectomy patients. J Oral Rehabil 2001;28:821-9.
9. Taylor TD. Clinical Maxillofacial Prosthetics. Chicago: Quintessence Publishing Co., Inc.;2000. p. 85-102.
10. Brown KE. Clinical considerations improving obturator treatment. J Prosthet Dent 1970;24:461-6.