[Downloaded free from http://www.jpbsonline.org on Saturday, August 29, 2020, IP: 103.58.116.141]

Original Article

Histocompatibility of Novel Cycloaliphatic Comonomer in Heat-cured Denture Base Acrylic Resin: Histomorphometric Analysis in Rats

Ranganathan Ajay[1], Karthigeyan Suma[2], Sengottaiyan Arulkumar[3], Ravichandran Mahadevan[4], Elumalai Ambedkar[5], Katturkaran Antonisamy Biju[6]

[1]Department of Prosthodontics, Crown, Bridge, Vivekanandha Dental College for Women, Namakkal, Tamil Nadu, India, [2]Department of Prosthodontics and Crown & Bridge, Rajah Muthiah Dental College & Hospital, Annamalai University, Annamalainagar, Tamil Nadu, India, [3]Department of Prosthodontics and Implant Dentistry, Sri Venkateswara Dental College and Hospital, Chennai, Tamil Nadu, India, [4]Department of Prosthodontics and Crown & Bridge, Ragas Dental College & Hospital, Uthandi, Tamil Nadu, India, [5]Department of Prosthodontics and Crown and Bridge, Sri Venkateswara Dental College and Hospital, Chennai, Tamil Nadu, India, [6]Department of Prosthodontics and Crown and Bridge, K.S.R. Institute of Dental Science & Research, Thiruchengode, Tamil Nadu, India

Received : 06-02-2020.
Revised : 08-02-2020.
Accepted : 09-03-2020.
Published : 28-08-2020.

ABSTRACT

Background: Prosthodontics is impossible without denture base resins. Allergic reactions to these resins are not uncommon, albeit favorable properties. Monomeric modifications are being done to improve the properties of the material. Tricyclodecane dimethanol diacrylate (TCDDMDA) monomer has been recently identified and experimented as a comonomer with methyl methacrylate (MMA). **Aim:** This study aimed to investigate the histocompatibility of TCDDMDA comonomer in polymerized resin at 10% and 20% (vol/vol) concentrations in rats by histomorphometric analysis. **Materials and Methods:** Twenty-four male Wistar rats were randomly divided into the following four groups: NP group (control; $n = 6$), with no palatal appliance, Groups P0, P10, and P20 were fixed with palatal appliances fabricated of 100% MMA, 10% TCDDMDA + 90% MMA, and 20% TCDDMDA + 80% MMA, respectively. Weights of the animals were recorded just before the appliance placement and after 14 days. The animals were sacrificed, and the palatal tissues were processed for histopathological analysis. Histomorphometric parameters assessed were total epithelial (ET), connective tissue (CT), and keratin layer (KT) thicknesses. **Results:** No significant difference was observed regarding body weight. Group P0 showed increased ET, CT, and KT when compared to other groups. Bonferroni multiple comparison tests showed a statistically significant difference between all the groups except between P10 and P20 for all the three morphometric parameters. **Conclusion:** Palatal appliances with TCDDMDA comonomer showed good histocompatibility in rats up to 20% (vol/vol) concentration.

KEYWORDS: *Comonomer, cycloaliphatic, denture base resins, histomorphometry, palatal appliance*

Address for correspondence: Dr. Ajay Ranganathan, Department of Prosthodontics and Crown & Bridge, Vivekanandha Dental College for Women, Elayampalayam, Tiruchengode, Namakkal 637205, Tamil Nadu, India.
E-mail: jrangclassiq@gmail.com

This is an open access journal, and articles are distributed under the terms of the Creative Commons Attribution-NonCommercial-ShareAlike 4.0 License, which allows others to remix, tweak, and build upon the work non-commercially, as long as appropriate credit is given and the new creations are licensed under the identical terms.

For reprints contact: reprints@medknow.com

How to cite this article: Ajay R, Suma K, Arulkumar S, Mahadevan R, Ambedkar E, Biju KA. Histocompatibility of novel cycloaliphatic comonomer in heat-cured denture base acrylic resin: Histomorphometric analysis in rats. J Pharm Bioall Sci 2020;12:S453-61.

Access this article online

Quick Response Code:

Website: www.jpbsonline.org

DOI: 10.4103/jpbs.JPBS_139_20

[Downloaded free from http://www.jpbsonline.org on Saturday, August 29, 2020, IP: 103.58.116.141]

Introduction

Biocompatibility (or histocompatibility) elucidates a biomaterial to perform with a suitable host response when intraorally used for prosthetic or restorative purposes.[1] A dental biomaterial used in a dynamic, complex, and inconsistent oral environment might confront futile disturbances. Sagacious scrutiny is mandatory before the commercial influx of any material. A material's toxicity, when introduced into oral cavity, activates the immune system to respond appropriately. Hence, one of the basic responsibilities bestowed on the prosthodontist is to protect patients from any unanticipated reaction.[2]

Denture base resins are an integral part of prosthodontics, which are usually mixtures of methacrylates and diacrylates, with inhibitors (benzoyl peroxide), activators (tertiary amines), cross-linking agents (ethylene glycol dimethacrylate), and reaction inhibitors (hydroquinone).[3] Every single ingredient in the composition is a known contact sensitizer and is suspected as respiratory sensitizers and/or irritants.[4,5] Occupationally induced contact dermatitis and respiratory hypersensitivity were due to volatilization in clinicians and other dental personnel.[6] Such reactions perhaps manifested among undergraduate and postgraduate students, who were exposed to methyl methacrylate (MMA) monomers and its metabolites during their academic tenure. Formaldehyde is an oxidative metabolite of residual MMA and released from denture bases.[7,8] Both residual MMA and formaldehyde inflict confined allergic reactions in the oral mucosa owing to denture contact.[9]

Polymerization is climacteric for the optimization of physico-mechanical and biological properties of denture base resins because it enables monomer to polymer conversion and determines the residual monomer content.[10] Toxic metabolites of residual MMA, such as methacrylic acid, benzoic acid, dibutyl phthalate, phenyl benzoate, and phenyl salicylate, are formed on the denture base with incomplete polymerization.[11-14] Albeit the polymerization cycles are performed according to the manufacturer's instructions, these toxic metabolites get released into the aqueous oral environment and compromise biocompatibility.[14-16] Though several methods of polymeric modifications were executed to decrease the residual monomer content, a modern trend has been set to sail about the monomer modifications by the addition of novel monomers into proprietary monomer MMA in the past two decades.[17] Only countable studies with modified monomers evaluating the cytotoxicity are available in the dental literature.[18,19] The hierarchy in evaluating biocompatibility usually commences with initial *in vitro* cytotoxicity assays. Evaluation of mitochondrial function and DNA synthesis are the two most common assays executed for cytotoxicity.[9,20] Next level of evaluating biocompatibility is by executing *in vivo* animal usage tests (rats, mice, rabbits, dogs, or even human primates).[2] Animal model experiments have not been performed yet with denture base resins with modified MMA monomers.

Tricyclodecane dimethanol diacrylate (TCDDMDA) is a novel difunctional, dual-reactive, and cross-linking acrylic monomer, capable of further reaction to incorporate new functionality and graft new polymeric chains. This monomer has easily polymerizable carbon–carbon (C = C) double bonds. This is owing to the reactive moieties of acrylates that are highly reactive when compared to the methacrylates.[21] TCDDMDA is copolymerized with polymethyl methacrylate (PMMA), and it is non-cytotoxic to the L929 mouse fibroblasts.[22,23] However, the *in vivo* histocompatibility of TCDDMDA has not been encountered so far in the dental literature. Hence, the purpose of the study was to investigate the *in vivo* histocompatibility of heat-cured denture base processed with TCDDMDA comonomer substituted with MMA at 10% and 20% (vol/vol) concentrations in rats by histomorphometric analysis. The research null hypothesis (μ_0) was that the PMMA denture base processed with TCDDMDA would not affect the histocompatibility.

Materials and Methods

Cycloaliphatic monomer, TCDDMDA, (Sigma–Aldrich, Steinheim, Germany; CAS Number 42594-17-2) and heat-polymerizing denture base acrylic resin (DPI Heat Cure, Dental Products of India, Mumbai, India) were used. Institutional animal ethics committee (IAEC; Reg. No. 889/PO/Re/S/05/CPCSEA; January 30, 2018) approved the protocol of the study (Approval No. SVCP/IAEC/PhD/1/01/2019). Experimental monomers were prepared by substituting TCDDMDA in MMA at 10% and 20% (vol/vol) concentration and stored in separate identical dark glass bottles. MMA without substitution was also stored in same kind of glass bottle.

Rats and impression procedures

Twenty-four adult male rats (*Rattus norvegicus*, Albinus, Wistar) were used in this research. All the rats were weighed periodically before the commencement of the experiment (330–400 g) to be certain about the cessation of the chief growth phase and then weekly during the course of experiment. They were accommodated in individual polypropylene cages (numbered from 1

[Downloaded free from http://www.jpbsonline.org on Saturday, August 29, 2020, IP: 103.58.116.141]

to 24) at 23 ± 2°C with 55% ± 10% relative humidity and for 12 h of bright–dark alternative cycles for acclimatization. All the rats were fed with *ad libitum* water and absolute nutritional rodent pellet diet (Krishi Cattle and Lab Animal Feeds, Bangalore, India). Cage bedding was changed at least thrice a week.

For making master impressions of the palate and to affix the palatal appliances, it was obligatory to anesthetize each rat twice.[24,25] This was attained by the administration of ketamine hydrochloride (80 mg/kg—Ketajet50; Sterkem Pharma, Mumbai, India) and xylazine (10 mg/kg—Xylaxin; Indian Immunological, Telangana, India) intraperitoneally. The working time acquired by this anesthesia was approximately 30 min. After anesthetizing the rats, preliminary impressions were made with putty consistency of polyvinyl siloxane (Photosil Soft putty; DPI) impression material carried in wooden stick depressors. Consequently, master impressions were recorded with light-body consistency (Photosil Light-body; DPI). For this, the rats were placed on a bracing platform, with the mouth open by a distinct spring apparatus. After impression procedures, the rats were accommodated carefully in their respective cages to recuperate from the anesthesia.

Fabrication of palatal appliance specimens

During this step, the rats were assigned randomly to one of the four groups ($n = 6$). Group NP: Rats without palatal appliance (negative control); Group P0: Rats with palatal appliance fabricated of 100% MMA; Group P10: Rats with palatal appliance fabricated of 10% TCDDMDA (vol/vol) in MMA; and Group P20: Rats with palatal appliance fabricated of 20% TCDDMDA (vol/vol) in MMA. Models were poured in type IV gypsum product (Kalrock; Kalabhai Karson, Mumbai, India). Modeling wax (Hindustan Dental Products, Hyderabad, India) was adapted, covering the palate from the distal most molar to the first fold of palate extending onto the occlusal and buccal surfaces of molars.

The waxed-up casts were flasked and dewaxed to obtain mold space. The polymer and the monomer were mixed in the ratio 3:1 and packed in the mold space and cured in water bath for 90 min at 74°C and then in 100°C for 30 min. Consequently, the flasks were bench cooled, and then the specimens were retrieved carefully from the flasks. The appliances were assessed for even and regular surface. Specimens with voids or porosities were rejected and refabricated. The borders of the appliances were carefully adjusted and smoothened to eliminate rough irregularities. The appliances were placed in distilled water for 48 h at 37°C for any residual monomer to leach out.

Palatal appliance insertion

A longitudinal anteroposterior groove in the molar coverage site was cut using a No. 6 round bur. This feature promoted mechanical retention of the appliance on the molars. Flowable composite resin (Filtek Supreme Ultra Flowable; 3M, Bangalore, India) was used to fill the groove in the appliance and then passively placed over the palate without exerting undue pressure. The adaptation was ensured by observing no gap between the appliance and the palate. This was followed by photopolymerization (SS White Dental, Thane, India) while the device was secured in position. Minimal quantity of composite resin was used, so that it does not encroach and affect the appliance–palate contact.

After the procedure, the rats were accommodated to rest and resurrect from the anesthesia. They were now changed to paste diet to prevent the accumulation of food debris under the palatal appliances.[24,25] The animals used the appliances for 14 days. The weights of the animals were noted just before the appliance insertion (D0) and during euthanasia after 14 days (D14) for each group. After 14 days of appliance usage, the animals of all the groups were euthanized by administration of overdose of thiopentone intraperitoneally (120 mg/kg).

Histomorphometric analysis

Each rat was decapitated, and the mandible was separated. The palatal appliance was meticulously detached without damaging the underlying palatal tissue. All other excess tissues or organs were removed carefully and fixed in 10% buffered formalin for 48 h. After fixation, the palatal tissue was carefully dissected from the underlying palatine bone without tearing. This was followed by tissue dehydration through a graded series of ethanol. The tissues were then embedded in paraffin for sections.

The tissues later were implanted in paraffin wax block. Five ribbon sections (in sections of 5 μm) per slide were made of each animal using a microtome (Leica RM2245; Nussloch, Germany) and then stained with hematoxylin and eosin (HE). Light microscope (Olympus CH20i; Olympus Opto, New Delhi, India) was used to examine the slides. For histomorphometric evaluation, in a section, images of two assessment sites were captured by digital microimaging device at ×200 magnification (Leica DMD108). The assessment sites were standardized at the central cut region; one near the nasopalatine plexus and the other at mid-palatine

[Downloaded free from http://www.jpbsonline.org on Saturday, August 29, 2020, IP: 103.58.116.141]

raphe. From each stained slide, two random sections were analyzed, and the measured values were averaged.[24] The parameters measured were total epithelial thickness (ET), the thickness of connective tissue (CT), and keratin layer thickness (KT) in micrometer (μm). For the measurements, Image-Pro Premier (Version 9.0 [9.1.5262.28]; Media Cybernetics, Rockville, Maryland) software was used. For a parameter, 10 measurements were made in each of the assessment sites and then the arithmetic mean values were calculated. This ensued two mean values obtained from two sections of each animal. The mean values of the two sections of each parameter were calculated to perform statistical analysis.

Statistical analysis

Statistical analysis was performed using Statistical Package for the Social Sciences (SPSS) software, version 20.0 (SPSS Inc., Chicago, Illinois). Preliminary results of the Kolmogorov–Smirnov test indicated the data were normally distributed ($P > 0.05$). Descriptive statistics, including mean, standard deviation (SD), standard error, maximum, and minimum were calculated. Concerning inferential statistics, for comparing the weights of the animals of all groups at D0 and D14 (NPD0 and D14; P0D0 and D14; P10D0 and D14; and P20D0 and D14), paired sample *t* test was performed. For comparing the histomorphometric parameters, one-way analysis of variance (ANOVA) followed by Bonferroni test (*post hoc*; $\alpha = 0.05$) were performed. $P < 0.05$ was considered for statistical significance.

Results

Concerning the animal weight, no statistically significant differences were observed between all the compared pairs ($P > 0.05$) [Table 1]. Table 2 describes the one-way ANOVA for histomorphometry. Group P0 showed increased ET, CT, and KT when compared to other groups. Bonferroni multiple comparison tests [Table 3] showed a statistically significant difference between all the groups except between P10 and P20 for all the three morphometric parameters. Table 4 describes the histological observations of the groups.

Discussion

The animal usage research is crucial in better understanding the disease dynamics and testing novel biomaterials before human trials. An important benefit of animal research resides in ethical concerns that restrict the execution of certain trials on humans in more aggressive contexts and when the *in vivo* effectiveness and toxicity of new biomaterials have not been previously studied. To analyze the *in vivo* disease processes, non-primate and primate animal models are available that constitute a crucial step in the assessment of a dental biomaterial's behavior.[25]

Animal feeding and weight loss owing to nutritional deficiencies that influence and interfere with the results of animal model experiments are the two paramount concerns with palatal appliance. In this study, the influence of the palatal appliance on animal nutrition was assessed by recording the weight just before (D0) fixing the appliance and compared with the weight after 14 days (D14) of appliance use. Neither the continued usage (palatally fixed) of the appliance by a rat altered its eating habits nor the appliance's design impeded its conventional maneuvers.[26,27] In this research, no significant weight loss was observed. This can be attributed to the palatal appliance design and mode of retention. Fabrication the palatal appliances with greater stability fabricated of master impressions yielded a better fit on the palatal tissues of rats when compared to the study conducted by Barclay *et al.*[28] The palatal appliances fabricated were small and thin as used in the previous studies so that the rats used them with comfort.[24,25,29]

In this study, group P0 showed greater KT, ET, and CT than all other groups. This increase in the histomorphometric parameters can be attributed to residual monomer release from the palatal appliances. This residual monomer is the potential tissue irritant causing hyperkeratosis, acanthosis, and elongated

Table 1: Paired Student's *t* test for comparing the weight of the animals

Pair comparison	Groups	Mean ± SD	*t* value	*P* value
Pair 1	NPD0	356.33 ± 16.39	0.660	0.539
	NPD14	355.75 ± 17.58		
Pair 2	P0D0	362.00 ± 24.32	1.655	0.159
	P0D14	361.54 ± 23.88		
Pair 3	P10D0	359.70 ± 24.01	2.445	0.078
	P10D14	359.41 ± 23.91		
Pair 4	P20D0	359.91 ± 21.95	1.581	0.175
	P20D14	359.58 ± 21.96		

[Downloaded free from http://www.jpbsonline.org on Saturday, August 29, 2020, IP: 103.58.116.141]

Table 2: One-way analysis of variance for histomorphometry

Group	Mean ± SD	*F* value	*P* value
I. Total epithelial thickness (μm) (ET)			
NP	419.14 ± 3.29	1494.074	0.000
P0	539.39 ± 4.37		
P10	392.64 ± 4.75		
P20	391.86 ± 5.15		
II. Connective tissue thickness (μm) (CT)			
NP	316.15 ± 1.48	5640.068	0.000
P0	399.10 ± 1.79		
P10	310.52 ± 0.97		
P20	310.39 ± 1.28		
III. Keratin layer thickness (μm) (KT)			
NP	100.56 ± 1.06	2147.256	0.000
P0	136.12 ± 1.45		
P10	94.00 ± 0.94		
P20	95.29 ± 0.54		

Table 3: *Post hoc* Bonferroni test

Group	Compared group	Mean difference	Sig.
I. Total epithelial thickness (μm) (ET)			
NP	P0	-120.24167*	0.000
	P10	26.50333*	0.000
	P20	27.28333*	0.000
P0	P10	146.74500*	0.000
	P20	147.52500*	0.000
P10	P20	0.78000	1.000
II. Connective tissue thickness (μm) (CT)			
NP	P0	-82.95000*	0.000
	P10	5.63833*	0.000
	P20	5.76667*	0.000
P0	P10	88.58833*	0.000
	P20	88.71667*	0.000
P10	P20	0.12833	1.000
III. Keratin layer thickness (μm) (KT)			
NP	P0	-35.56667*	0.000
	P10	6.55667*	0.000
	P20	5.26833*	0.000
P0	P10	42.12333*	0.000
	P20	40.83500*	0.000
P10	P20	-1.28833	0.283

*The mean difference is significant at the 0.05 level

Table 4: Histological descriptions of the groups (hematoxylin and eosin, ×200)

NP	P0	P10 and P20
Stratified squamous epithelium with orthokeratin layer is seen. Stratum granulosum was legibly distinguished with mild epithelial rete pegs. Well-collagenized connective tissue can be seen along with normal periosteal layer [Figure 1].	There was an increase in the ET along with hyperkeratosis and acanthosis. The presence of elongated epithelial rete ridges (arrow up) can be seen. Presence of papillary projections (arrow down) in the central palatal region indicates change in tissue morphology. Nucleus showed vesicular changes. The inflammatory cell infiltration in the connective tissue was absent [Figure 2].	Orthokeratinized stratified squamous epithelium is seen. Discrete epithelial rete pegs with well-collagenized connective tissue and normal periosteal layer were also observed. However, the ET, CT, and KT are thinner than the NP group. Inflammatory cells infiltration was not evident in the connective tissue (P10: Figure 3; P20: Figure 4).

[Downloaded free from http://www.jpbsonline.org on Saturday, August 29, 2020, IP: 103.58.116.141]

epithelial rete ridges with vesicular nuclear changes in the cellular compartment. The presence of papillary projections apparently indicated tissue morphological alterations. Interestingly, the connective tissue had normal fibroblasts with no inflammatory cell infiltrations. The plausible reason might be due to the presence of keratin and epithelial layers as barriers, which delayed the residual monomer from contacting

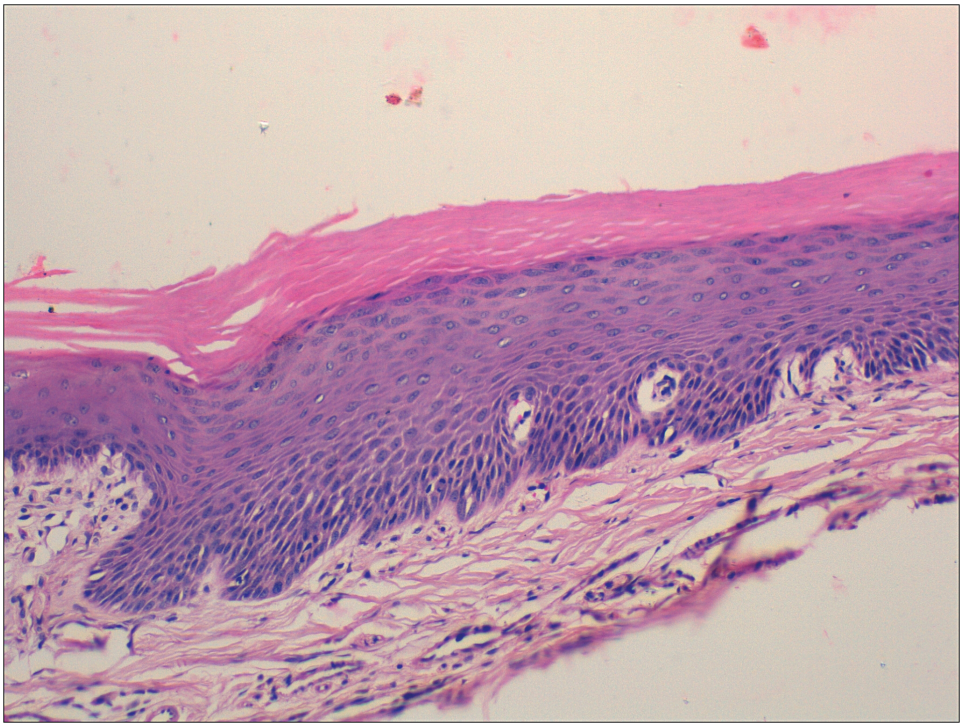

Figure 1: Representative section of group NP (hematoxylin and eosin, ×200 magnification)

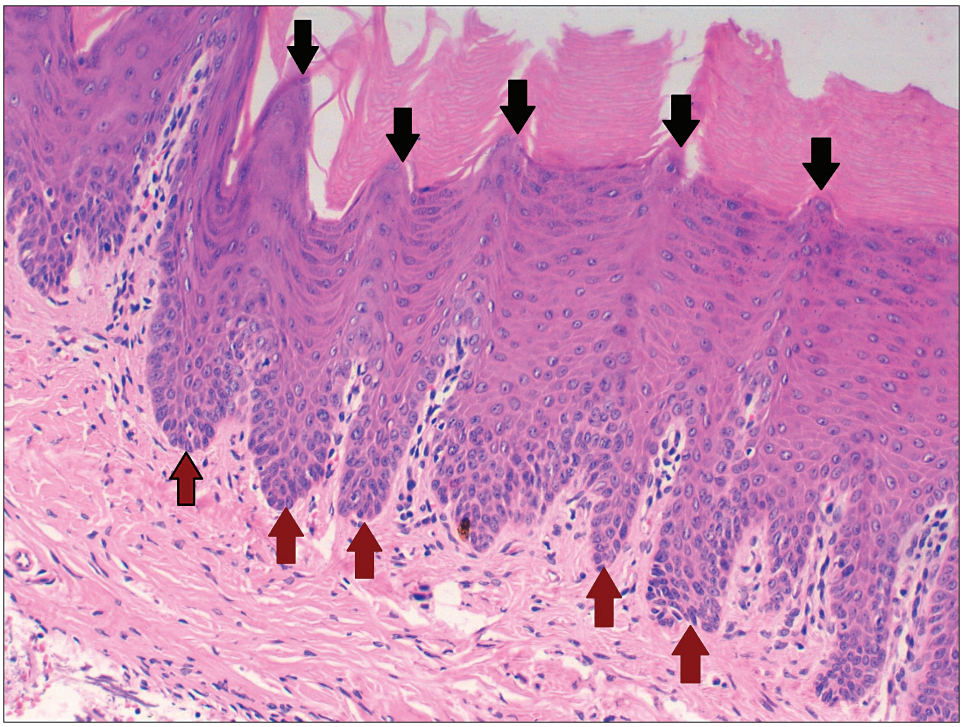

Figure 2: Representative section of group P0 (hematoxylin and eosin, ×200 magnification). Elongated epithelial rete ridges (arrow up) and papillary projections (arrow down) can be seen

[Downloaded free from http://www.jpbsonline.org on Saturday, August 29, 2020, IP: 103.58.116.141]

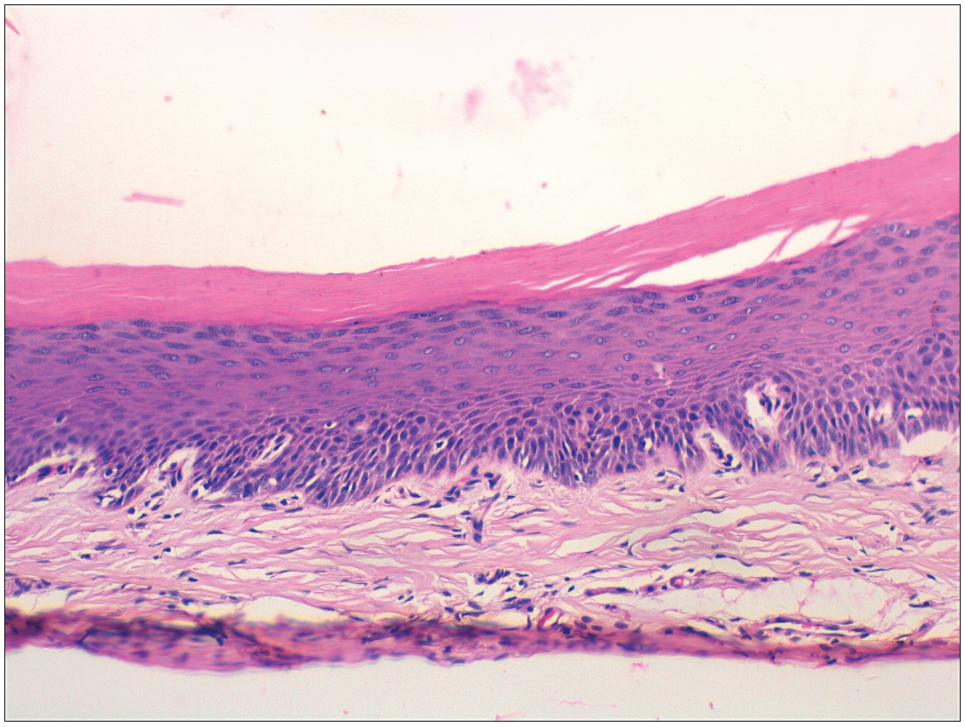

Figure 3: Representative section of group P10 (hematoxylin and eosin, ×200 magnification)

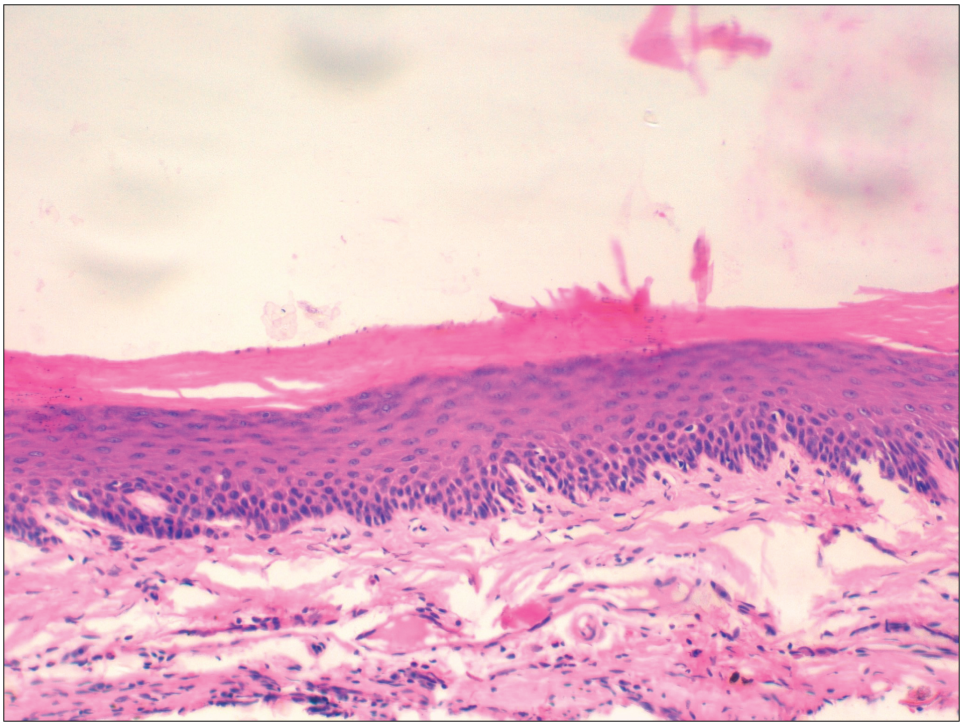

Figure 4: Representative section of group P20. (hematoxylin and eosin, ×200 magnification)

the connective tissue within 14 days. The results of this study are congruent with Kapur and Shklar[30] who evaluated the effect of complete dentures on alveolar mucosa and observed keratinization along with slight increase in CT, proposing that these tissue alterations might be sequelae of chemical insult.

However, the results for the groups P10 and P20 might be attributed to the sustained pressure deployed by the appliances on the palatal mucosa owing to masticatory

[Downloaded free from http://www.jpbsonline.org on Saturday, August 29, 2020, IP: 103.58.116.141]

forces. The histomorphometric parameters of P10 and P20 groups showed statistically significant differences when compared to NP group. The ET, CT, and KT were thinner in both P10 and P20 groups than NP group. Orthokeratinized stratified squamous epithelium with discrete epithelial rete pegs, well-collagenized connective tissue, and normal periosteal layer were observed. Maruo *et al.*[31] cemented acrylic appliances on the palatal mucosa of rats to assess tissue reactions based on exerted pressure, and it was found that there was a reduction in the ET. As the palatal appliances of groups P10 and P20 were fabricated with 10% and 20% TCDDMDA comonomer, respectively, ET and KT did not increase as shown in P0 group. This inference can be supported by an *in vitro* cytotoxicity test conducted by Ranganathan *et al.*[23] They showed increased mouse fibroblast viability with the specimens processed with TCDDMDA. This was due to the reduction of residual monomer release into the culture medium. Hence, in this study, palatal appliances processed with 10% and 20% TCDDMDA (Groups P10 and P20) showed tissue compatibility without adversely affecting the tissue morphology. Therefore, the null hypothesis was accepted.

Subcutaneous implantation of the biomaterials in animals has been executed commonly. However, the exact oral perspectives and reactions to the biomaterials were not reflected. Denture base acrylic resin is one such biomaterial, which has an intimate contact with the oral tissues. In the previous studies, assessment of biological behavior of denture base material was directly executed on rats with the aid of palatal devices.[26,28,29,31] Mucous membrane irritation tests using removable or fixed prosthetic appliances in tiny non-primates were apparently strenuous, exorbitant, and tedious.[32] This is because the intraoral appliances described in the previous research were unsophisticated and insufficient.[26] Hence, in this study, the palatal appliances were designed in accordance with the method elucidated by Meister *et al.*[25] in 2015. In this study, the appliances were retained on molars with flowable composite without acid-etching. Meister *et al.*,[25] in their pilot study, concluded that composite resin without acid-etching provided the most efficacious and adequate retention for the intraoral appliance. Jorge *et al.*[33] retained the palatal appliances by autopolymerizing acrylic resin. The exothermic polymerization reaction and unreacted monomeric residues of the material could lead to histological aberrations, thus affecting the results directly. Barclay *et al.*[34] encountered poor retention and lost the number of appliances retained with autopolymerizing acrylic resin cement, which was later replaced and retained with zinc oxide–eugenol cement. Both of these cements could lead to histological alterations, influencing and affecting the results.

Conclusion

Thus, in accordance with the results of this study, it can be concluded that processing heat-cured acrylic palatal appliance with TCDDMDA comonomer (up to 20% vol/vol) showed good histocompatibility in rats.

Acknowledgement

We would like to thank Dr. T.R. Yoithap Prabhunath, MDS, Associate Professor, Department of Oral and Maxillofacial Pathology, Vivekanandha Dental College for Women, Thiruchengode, Tamil Nadu, India, for the immense help and assistance in the histological section in this study.

Financial support and sponsorship

Nil.

Conflicts of interest

There are no conflicts of interest.

References

1. Anusavice KJ. Phillips' science of dental materials. 11th ed. St. Louis, MO: Saunders; 2004.
2. Swetha B, Mathew S, Murthy BV, Shruthi N, Bhandi SH. Determination of biocompatibility: a review. Int Dent Med J Adv Res 2015;1:1-6.
3. Borak J, Fields C, Andrews LS, Pemberton MA. Methyl methacrylate and respiratory sensitization: a critical review. Crit Rev Toxicol 2011;41:230-68.
4. Kanerva L, Henriks-Eckerman ML, Estlander T, Jolanki R, Tarvainen K. Occupational allergic contact dermatitis and composition of acrylates in dentin bonding systems. J Eur Acad Dermatol Venerol 1994;3:157-68.
5. Enoch SJ, Roberts DW, Cronin MT. Electrophilic reaction chemistry of low molecular weight respiratory sensitizers. Chem Res Toxicol 2009;22:1447-53.
6. Gautam R, Singh RD, Sharma VP, Siddhartha R, Chand P, Kumar R. Biocompatibility of polymethyl methacrylate resins used in dentistry. J Biomed Mater Res B Appl Biomater 2012;100:1444-50.
7. Ruyter IF. Release of formaldehyde from denture base polymers. Acta Odontal Scand 1980;38:17-27.
8. Tsuchiya H, Hoshino Y, Kato H, Takagi N. Flow injection analysis of formaldehyde leached from denture-base acrylic resins. J Dent 1993;21:240-3.
9. Chaves CA, Machado AL, Vergani CE, de Souza RF, Giampaolo ET. Cytotoxicity of denture base and hard chairside reline materials: a systematic review. J Prosthet Dent 2012;107:114-27.
10. Bural C, Aktaş E, Deniz G, Ünlüçerçi Y, Bayraktar G. Effect of leaching residual methyl methacrylate concentrations on *in vitro* cytotoxicity of heat polymerized denture base acrylic resin processed with different polymerization cycles. J Appl Oral Sci 2011;19:306-12.

[Downloaded free from http://www.jpbsonline.org on Saturday, August 29, 2020, IP: 103.58.116.141]

11. Ata SO, Yavuzyilmaz H. *In vitro* comparison of the cytotoxicity of acetal resin, heat-polymerized resin, and autopolymerized resin as denture base materials. J Biomed Mater Res B Appl Biomater 2009;91:905-9.
12. Kojima N, Yamada M, Paranjpe A, Tsukimura N, Kubo K, Jewett A, *et al*. Restored viability and function of dental pulp cells on poly-methylmethacrylate (PMMA)-based dental resin supplemented with N-acetyl cysteine (NAC). Dent Mater 2008;24:1686-93.
13. Tay LY, Herrera DR, Quishida CC, Carlos IZ, Jorge JH. Effect of water storage and heat treatment on the cytotoxicity of soft liners. Gerodontology 2012;29:e275-80.
14. Att W, Yamada M, Kojima N, Ogawa T. N-acetyl cysteine prevents suppression of oral fibroblast function on poly(methyl methacrylate) resin. Acta Biomater 2009;5:391-8.
15. Ebrahimi Saravi M, Vojdani M, Bahrani F. Evaluation of cellular toxicity of three denture base acrylic resins. J Dent (Tehran) 2012;9:180-8.
16. Bural C, Aktaş E, Deniz G, Ünlüçerçi Y, Kızılcan N, Bayraktar G. Effect of post-polymerization heat-treatments on degree of conversion, leaching residual MMA and *in vitro* cytotoxicity of autopolymerizing acrylic repair resin. Dent Mater 2011;27:1135-43.
17. Ajay R, Suma K, Ali SA. Monomer modifications of denture base acrylic resin: a systematic review and meta-analysis. J Pharm Bioallied Sci 2019;11:112-25.
18. Kim SK, Heo SJ, Koak JY, Lee JH, Lee YM, Chung DJ, *et al*. A biocompatibility study of a reinforced acrylic-based hybrid denture composite resin with poly-hedral oligosil sesquioxane. J Oral Rehab 2007;34:389-95.
19. Jiao Y, Ma S, Li J, Shan L, Yang Y, Li M, *et al*. The influences of N-acetyl cysteine (NAC) on the cytotoxicity and mechanical properties of poly-methylmethacrylate (PMMA)-based dental resin. Peer J 2015;3:e868.
20. Goiato MC, Freitas E, dos Santos D, de Medeiros R, Sonego M. Acrylic resin cytotoxicity for denture base—literature review. Adv Clin Exp Med 2015;24:679-86.
21. Ruyter IE, Svendsen SA. Flexural properties of denture base polymers. J Prosthet Dent 1980;43:95-104.
22. Ajay R, Suma K, Jaya Krishna Kumar S, Rajkumar G, Kumar SA, Geethakumari R. Chemical characterization of denture base resin with a novel cycloaliphatic monomer. J Contemp Dent Pract 2019;20:940-6.
23. Ranganathan A, Karthigeyan S, Murugesan SV, Kandasamy B, Veeramalai D, Natesan D. Evaluation of in-vitro cytotoxicity of heat-cure denture base resin processed with a dual-reactive cycloaliphatic monomer. J Contemp Dent Pract 2019;20:1279-85.
24. Meister LMB, Kovalik AC, Pellissari CV, Bail M, Campagnoli EB, Jorge JH, *et al*. Effect of post-polymerization heat treatment on a denture base acrylic resin: histopathological analysis in rats. Int J Dentistry Oral Sci. 2015;S2:1-7.
25. Meister LMB, Bail M, Pellissari CVG, Ban MCI, Campagnoli EB, Jorge JH, *et al*. Description of a rat palatal acrylic plate that can be relined. J Prosthodont 2015;24:562-8.
26. Lee H, Yu A, Johnson CC, Lilly EA, Noverr MC, Fidel PL Jr. Fabrication of a multi-applicable removable intraoral denture system for rodent research. J Oral Rehabil 2011;38:686-90.
27. Johnson CC, Yu A, Lee H, Fidel PL Jr, Noverr MC. Development of a contemporary animal model of *Candida albicans*-associated denture stomatitis using a novel intraoral denture system. Infect Immun 2012;80:1736-43.
28. Barclay SC, MacDonald DG, Watson IB. The effect of diet on palatal prosthetic coverage in rats. J Dent 1997;25:71-8.
29. Tsuruoka M, Ishizaki K, Sakurai K, Matsuzaka K, Inoue T. Morphological and molecular changes in denture-supporting tissues under persistent mechanical stress in rats. J Oral Rehabil 2008;35:889-97.
30. Kapur K, Shklar G. The effect of complete dentures on alveolar mucosa. J Prosthet Dent 1963;13:1030-7.
31. Maruo Y, Sato T, Hara T, Mori S, Shirai H, Minagi S. The effect of diabetes mellitus on the expression of argyrophilic nucleolar organizer regions (agnors) in mucosal epithelium under experimental denture bases in rats. J Oral Pathol Med 2003;32:171-5.
32. Stanley HR. Mucous membrane irritation test (Hamster's Pouch). In: Toxicity of dental materials. Boca Raton, FL: CRC Press; 1985. p. 55-60.
33. Jorge AO, Rego MA, Almeida OP. Inoculação de Candida albicans em ratos sialoadenectomizados portadores de placa acrílica no palato. Rev Biociênc 2001;7:71-7.
34. Barclay SC, MacDonald DG, Watson IB. The effect of chairside relining materials on rat palatal mucosa. J Dent 1997;25:251-5.