Original Article

# Cytogenetic Alterations in Oral Potentially Malignant Disorders Associated with Chronic Mechanical Irritation: A Comparative Analysis of Micronuclei, Silver-Stained Nucleolar Organiser Count and Comet Assays

**Arumugam Aarthi[1], Thuckanaickenpalayam Ragunathan Yoithapprabhunath[1,2], Nalliappan Ganapathy[1], Thangadurai Maheswaran[3], Vadivel Ilayaraja[1], Janardhanam Dineshshankar[1], Jerónimo Pablo Lazos[4], Eduardo David Piemonte[4]**

[1]Department of Oral and Maxillofacial Pathology and Microbiology, Vivekanandha Dental College for Women, Affiliated with the Tamil Nadu Dr. MGR Medical University, Namakkal, Tamil Nadu, India, [2]The Tamil Nadu Dr. MGR Medical University, Tamil Nadu, India, [3]Department of Oral and Maxillofacial Pathology and Microbiology, Adhiparasakthi Dental College and Hospital, Affiliated with the Tamil Nadu Dr. MGR Medical University, Melmaruvathur, Tamil Nadu, India, [4]Department of Oral Medicine, Dentistry College, Universidad Nacional de Córdoba, Córdoba, Argentina

## Abstract

**Background:** Chronic mechanical irritation (CMI) of the oral mucosa has been suggested as a potential cofactor for oral cancer (OC) as a dependent risk factor. OC could be preceded by oral potentially malignant disorders (OPMDs), and early detection can improve prognosis. The prevalence of genetic damage among the OPMD individuals associated with and without CMI remains unexplored. **Objectives:** The objective is to assess genetic damage in oral exfoliative cells of CMI-associated individuals presenting with and without OPMD using micronuclei count, argyrophilic nucleolar organizing region (AgNOR) count, and comet assay. **Materials and Methods:** Micronucleus assay, AgNOR assay, and comet assay analysis were performed in a total sample of 75 individuals grouped as control ($n$ = 25), CMI without OPMD ($n$ = 25), and CMI with OPMD ($n$ = 25). **Results:** A significant increase in DNA damage is not only found in CMI with OPMD group, but also in CMI without OPMD, where chronic irritation can act as an independent factor in causing DNA damage. **Conclusion:** CMI could cause permanent DNA damage and is considered a low-risk factor in cancer development.

**Keywords:** AgNOR, chronic oral mucosa irritation, comet assay, genetic damage, micronuclei, oral potentially malignant disorders

## Introduction

Cancer is considered a multifactorial disease, and it is the end product of an untamed proliferation of cells resulting from genetic alterations (mutations) in precursor cells.[1] According to Globocan 2022, oral cancer (OC) is the second most common cancer in India, with 143,759 cases, accounting for 10.2% of all cancers in the country. In 2022, OC was the 16th most common cancer worldwide, with 389,485 new cases and 188,230 deaths.[2] According to the 2022 India Cancer fact sheet, cancer of the lip and oral cavity showed a huge increase of 1,43,759 cases when compared to 2020, and is one of the major public health problems faced by the Indian subcontinent. It is proven that 30%–50% of OC cases originate from oral potentially malignant disorders (OPMDs). The prevalence of OPMDs globally ranges from 0.02% to 25.9%, with higher rates reported

Access this article online

Quick Response Code:

Website: https://journals.lww.com/jocy

DOI: 10.4103/joc.joc_156_25

**Address for correspondence:** Dr. Yoithapprabhunath Thuckanaickenpalayam Ragunathan, Department of Oral Pathology and Microbiology, Vivekanandha Dental College for Women, Namakkal 637205, Tamil Nadu, India.
E-mail: yoitha.dentist@gmail.com

This is an open access article distributed under the terms of the Creative Commons Attribution-NonCommercial-NoDerivatives 4.0 License (CC BY-NC-ND), where it is permissible to download and share the work provided it is properly cited. The work cannot be changed in any way or used commercially without permission from the journal.

**For reprints contact:** WKHLRPMedknow_reprints@wolterskluwer.com

**How to cite this article:** Aarthi A, Yoithapprabhunath TR, Ganapathy N, Maheswaran T, Ilayaraja V, Dineshshankar J, *et al.* Cytogenetic alterations in oral potentially malignant disorders associated with chronic mechanical irritation: A comparative analysis of micronuclei, silver-stained nucleolar organiser count and comet assays. J Cytol 2026;43:174-80.

**Submitted:** 26-Nov-2025; **Revised:** 24-Jan-2026; **Accepted:** 18-Mar-2026; **Published:** 09-Jul-2026

in South and Southeast Asia, where the habit of betel quid and areca nut chewing is prevalent. The overall malignant transformation rate of OPMDs is estimated to be between 0.13% and 36.4%, depending on the type, duration, and severity of the lesion as well as the presence of dysplasia on histopathological examination, indicating the seriousness of the problem.[3,4]

Chronic mechanical irritation (CMI) causes repeated injury to the oral mucosa by deleterious agents, either from teeth factors or prosthetic factors, which creates low-intensity mechanical injury, causing cytogenetic damage. Prosthetic factors associated with CMI are intra-oral ill-fitting and prostheses that have rough surfaces. Dental factors associated with CMI include sharp/fractures/rough surfaces of natural teeth and mal-positioned teeth. Also, the effect of dental and prosthetic factors could be facilitated by functional factors such as dysfunctional swallowing and tongue thrusting, among others. Chronic oral mucosa irritation has a significant association with oral squamous cell carcinoma (OSCC), and the nature of the association could be that of a potential cofactor (dependent risk factor) rather than an independent risk factor. This suggests that CMI factors play a role as promoters and progressors in oral carcinogenesis. Thus, if a cancer has eventually started from any other cause, CMI will probably hasten the process of carcinogenesis.[5,6] The prevalence of OPMDs globally ranges from 0.02% to 25.9%, with higher rates reported in South and Southeast Asia, where the habit of betel quid and areca nut chewing is prevalent.[6]

Oral exfoliative cytology is the microscopic examination of exfoliated cells from an epithelial surface. It is a noninvasive, simple, and sensitive staining technique used as an adjuvant for biopsy or in cases where biopsy is not feasible, as well as for mass screening.[7]

Micronuclei (MN) are formed during mitosis, where the chromatids are damaged during anaphase. Since 1937, MN have been used as an indicator of genotoxic exposure due to their association with chromosomal aberrations. They are detected from the exfoliated cells using nuclear staining. The formation of the MN assay is accepted as a marker of early carcinogenesis in screening tests among high-risk groups.[1,8,9] The argyrophilic nucleolar organizing regions (AgNORs) method is being used in both cytological and histological studies. Based on the ribosomal gene activity, the number of AgNOR dots can be detected in the nucleoli of the cell with a higher proliferation rate and genetically damaged cells. AgNOR assay is a good indicator of the proliferation index of genetically damaged cells and an efficient, reliable, cheap, and sensitive method, and has the ability to evaluate a large number of samples in a short time and economically, to achieve quantitative and comparable results, and to standardize test methods.[10,11] Comet assay or single-cell gel electrophoresis is used as a tool for detecting the quantification of double-strand breaks in the DNA. This technique was first established by Ostling and Johansson in the year 1984, and it is a rapid and noninvasive technique. This technique is known as single-cell gel electrophoresis. It is used to measure the DNA damage caused by radiation during carcinogenesis.[12,13]

The pathway linking CMI with OSCC has been seldom studied. The interaction between CMI and OPMD in the development of OSCC has not been studied, either in epidemiological models or in studies that explain biological phenomena.[14] This study aimed to analyze the cytogenetic damage by comparing the micronucleus assay, AgNOR assay, and comet assay in exfoliated epithelial cells of CMI-associated individuals presenting with and without OPMDs.

## Materials and Methods

### Ethical committee consent

All procedures performed in this study were approved by the institution review board and/or national research ethics committee (VDCW/IEC/224/2021 on March 15, 2021) in accordance with the 1964 Helsinki declaration and its later amendments.

### Sample size estimation

To determine the required sample size for this study, a calculation was performed using a standard formula for proportions. We assumed a 95% confidence level, which corresponds to an alpha ($\alpha$) level of 0.05 (two-tailed), resulting in a $Z$-score ($Z1-\alpha/2$) of 1.96. While the provided calculation focuses on the confidence interval, an implicit power ($1 - \beta$) of 80% is standard for such designs to minimize type II errors.

With an expected proportion ($P$) of 0.5 (providing maximum variance) and a margin of error ($d$) of 0.2, the calculated sample size is 24. To ensure robustness, this was rounded to 25 participants per group.

This study analysis was made in a total of 75 individuals, which was divided into three groups,

Group I: Control (individuals do not have OPMD and CMI factors)—25 individuals,
Group II: CMI (individuals having CMI without OPMD)—25 individuals, and
Group III: CMI + OPMDs (individuals having CMI with OPMD)—25 individuals.

Individuals presenting with dental or prosthetic factors contributing to CMI—such as fractured teeth, sharp cusps, extensive cavities, longstanding irritation from overhanging restorations, rough denture margins, or ill-fitting dentures—were included in the study, based on the criteria described by Lazos *et al.*[15] Participants exhibiting white or red lesions in areas associated with CMI were clinically diagnosed as

leukoplakia, erythroplakia, or oral lichen planus and were categorized under OPMDs. Only participants reporting CMI persisting for more than 6 months were included. Individuals with lesions clinically suggestive of malignancy, a history of diagnostic or therapeutic radiation exposure, systemic diseases or disorders, or habits such as smoking, smokeless tobacco use, areca nut chewing, or alcohol consumption were excluded from the study. Study participants were asked to rinse their mouths with water before sampling. A cyto-brush was used to obtain cell samples from the respective site of CMI. It was then transferred into centrifuge tubes with phosphate-buffered saline (PBS) at pH 7.2 and centrifuged for 10 min at 1500 rotations per minute (rpm). Supernatant was replaced with 5 mL of fresh PBS solution, centrifuged for 10 min at 1500 rpm, and repeated twice. This supernatant was discarded, and the pellet smeared onto clean microscopic slides.

### Feulgen staining procedure

The slide was immersed in 5 mol/L HCl for 15 min and rinsed in distilled water for 3 min. The slide was stained using Schiff reagent for 90 min and washed in distilled water for 10 min, then stained with 1% light green for 15 min. The slides were dried and mounted with dibutylphthalate polystyrene xylene (DPX) for bright-field microscopic analysis to determine the MN frequencies.[1]

### AgNOR staining procedure

The smear taken was air-dried, fixed, and rehydrated, and the slides were counterstained for 5 min using distilled water. The slide was stained with AgNOR working solution for 15 min and washed in distilled water for 3–4 changes to remove the silver deposits. The slide is then air-dried and mounted using DPX.[10]

### Procedure for comet assay

The collected samples were centrifuged. Slide preparation, agarose embedding, lysis, pre-electrophoresis, electrophoresis, neutralization, staining procedure, assessment of smear, and image analysis were followed according to Mohanapriya *et al.*[16]

### Statistical analysis

Statistical analysis was performed with IBM Statistical Package for the Social Science Statistics for Windows, version 23.0 (IBM Corp, Chicago, IL, USA). The level of significance ($P < 0.05$) was employed in all statistical comparisons. Quantitative data were recorded as mean ± standard deviation. To test the normality, the Kolmogorov–Smirnov (K–S) test was used, the Kruskal–Wallis test was used to compare across the groups, and the Dunn *post hoc* test was used to compare between groups.

## Results

The MN assay, AgNOR assay, and comet assay were used to assess the DNA damage in the cells of patients with CMI with lesions and CMI without lesions [Figures 1–3]. A total of 75 samples were taken for the study, which included 25 controls (Group I), 25 CMI without lesions (Group II), and 25 CMI with lesions (Group III). Groups II and III are study groups.

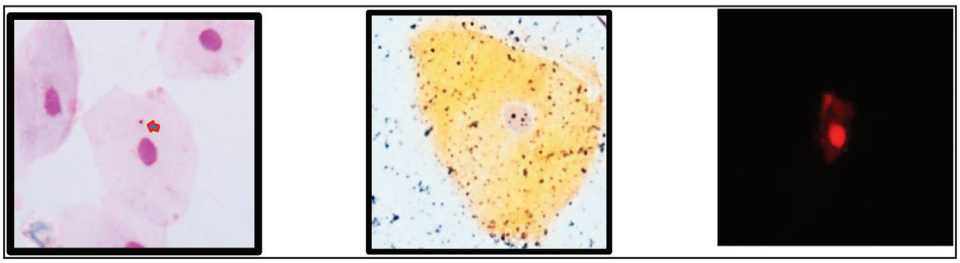

**Figure 1:** Micronuclei, argyrophilic nucleolar organizing region, and comet assay in the control group

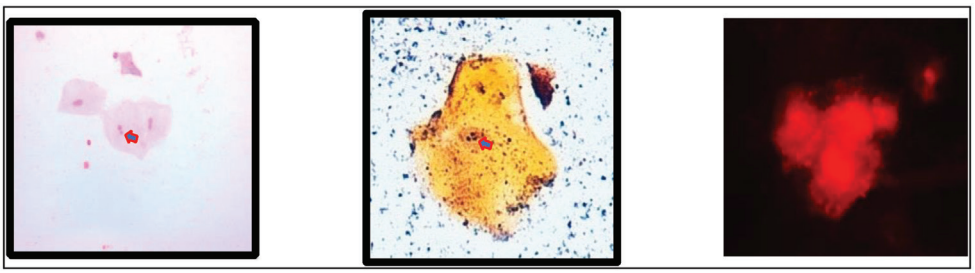

**Figure 2:** Micronuclei, argyrophilic nucleolar organizing region, and comet assay in chronic mechanical irritation without lesion

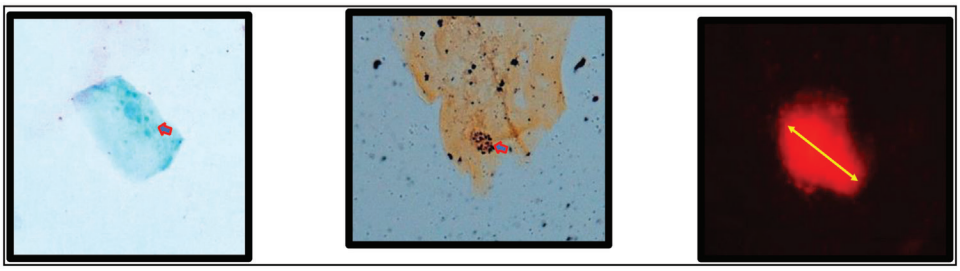

**Figure 3:** Micronuclei, argyrophilic nucleolar organizing region (AgNOR), and comet assay in chronic mechanical irritation with lesion. Representative photomicrographs of each group are shown in Figures 1–3, illustrating progressive cytogenetic damage with higher micronuclei frequency, increased AgNOR dot density, and elongation of the DNA tail

**Table 1: Test for normality**

| Parameter | Groups* | Statistic | df | Significance |
|---|---|---|---|---|
| Micronuclei | Control | 0.429 | 25 | 0.000 |
| | CMI | 0.355 | 25 | 0.000 |
| | CMI + OPMDs | 0.222 | 25 | 0.003 |
| AgNOR | Control | 0.521 | 25 | 0.000 |
| | CMI | 0.409 | 25 | 0.000 |
| | CMI + OPMDs | 0.347 | 25 | 0.000 |
| COMET assay | Control | 0.347 | 25 | 0.000 |
| | CMI | 0.380 | 25 | 0.000 |
| | CMI + OPMDs | 0.276 | 25 | 0.000 |

CMI = chronic mechanical irritation, OPMD = oral potentially malignant disorder, AgNOR = argyrophilic nucleolar organizing region
*Kolmogorov–Smirnov test, $P < 0.05$—statistically significant

**Table 2: Comparison across groups on micronuclei assay, argyrophilic nucleolar organizing region (AgNOR) assay, comet assay**

| Parameter | Groups* | Mean rank | Chi-square | df | Significance |
|---|---|---|---|---|---|
| Micronuclei | Control | 25.90 | 15.3 | 2 | 0.00 |
| | CMI | 40.70 | | | |
| | CMI + OPMDs | 47.40 | | | |
| AgNOR | Control | 30.50 | 7.61 | 2 | 0.02 |
| | CMI | 39.50 | | | |
| | CMI + OPMDs | 44.00 | | | |
| COMET assay | Control | 26.14 | 14.15 | 2 | 0.001 |
| | CMI | 41.52 | | | |
| | CMI + OPMDs | 46.34 | | | |

CMI = chronic mechanical irritation, OPMD = oral potentially malignant disorder
*Kruskal–Wallis test, $P < 0.05$—statistically significant

Table 1 depicts the assessment of data distribution. The K–S test showed a significant difference, rejecting the null hypothesis; the data follows a non-parametric (skewed) distribution.

In the MN assay, control showed a K–S statistic value of 0.429, CMI showed a value of 0.355, and CMI + OPMD showed a value of 0.222. Control had a *P* value of 0.000, CMI had a *P* value of 0.000, and CMI + OPMD had a *P* value of 0.003. Hence, the *P* value is significant in all three groups.

In the AgNOR assay, control showed a K–S statistic value of 0.521, CMI showed a value of 0.409, and CMI + OPMD showed a value of 0.347. Control had a *P* value of 0.000, CMI had a *P* value of 0.000, and CMI + OPMD had a *P* value of 0.000. Hence, the *P* value is significant in all three groups.

In the comet assay, control showed a K–S statistic value of 0.347, CMI showed a value of 0.380, and CMI + OPMD showed a value of 0.276. Control had a *P* value of 0.000, CMI had a *P* value of 0.000, and CMI + OPMD had a *P* value of 0.000. Hence, the *P* value is significant in all three groups.

In the MN assay, control showed a mean of 25.90, CMI showed a mean of 40.70, and CMI + OPMDs showed a mean of 47.40. Kruskal–Wallis Test showed a significant difference in the three groups (chi-square = 15.3, *P* value = 0.00). The MN were found to be increased in the study groups (CMI and CMI + OPMD) in comparison with the control group. Among the study groups, CMI + OPMD shows increased MN in comparison with CMI.

In the AgNOR assay, control showed a mean of 30.50, CMI showed a mean of 39.50, and CMI + OPMD showed a mean of 44.00. Kruskal–Wallis test showed a significant difference in the three groups (chi-square = 7.61, *P* value = 0.02). The AgNOR dots were found to be increased in the study groups (CMI and CMI + OPMD) in comparison with the control group. Among the study groups, CMI + OPMD shows increased AgNOR dots in comparison with CMI.

In the comet assay, control showed a mean of 26.14, CMI showed a mean of 41.52, and CMI + OPMD showed a mean of 46.34. Kruskal–Wallis test showed a significant difference in the three groups (chi-square = 14.15, *P* value = 0.001). The comet tail length was found to be increased in the study groups (CMI and CMI + OPMD) in comparison with the control group (control). Among

**Table 3: Comparison between groups**

| Groups | Control versus CMI | Control versus CMI + OPMD | CMI versus CMI + OPMD |
|---|---|---|---|
| Micronuclei | 0.02* | 0.00* | 0.70 |
| AgNOR | 0.21 | 0.02* | 1.00 |
| Comet assay | 0.018* | 0.001* | 1.00 |

CMI = chronic mechanical irritation, OPMD = oral potentially malignant disorder, AgNOR = argyrophilic nucleolar organizing region
*Dunn *post hoc* Test, $P < 0.05$—statistically significant

the study groups, CMI + OPMD shows increased comet tail in comparison with CMI [Table 2].

Table 3 shows the intergroup comparison. MN assay between control and CMI (0.02) and control and CMI + OPMD (0.00) showed significance, while CMI and CMI + OPMD (0.70) showed no significance. Intergroup comparison of AgNOR assay between control and CMI + OPMD (0.02) showed significance, while control and CMI (0.21) and CMI and CMI + OPMD (1.00) showed no significance. Intergroup comparison of comet assay between control and CMI (0.018) and control and CMI + OPMD (0.001) showed significance, while CMI and CMI + OPMD (1.00) showed no significance.

## Discussion

Traumatic ulcers heal within 7–10 days, but some persist for weeks to months due to constant irritation. The presence of CMI is detected in any case of ulceration, keratosis, hyperplasia, erythema, atrophy, indentation, or fibrosis in direct contact with a "mechanical agent" (e.g., teeth or denture), during functional/parafunctional movements, or decubitus position. CMI due to sharp/broken teeth is one of the main etiology may not be able to produce genetic mutation, but may prompt epigenetic changes that ultimately promote genetic damage and inhibit DNA repair.[1] Epidemiological evidence linking CMI with OC is limited, and since it is not feasible to develop cohort studies, the level of evidence that can be obtained is restricted. Frequency of MN, AgNOR assay, and comet assay were proved as a reliable biomarker for assessing the genotoxicity, cellular proliferation, and DNA damage to assess the initiation and neoplastic progression.

In this study, a significant difference in the frequency of MN was found between the study groups and the control group. There was no significant difference in the frequency of MN between the groups having CMI without OPMDs and CMI with OPMDs. Hence, a significant increase of genetic damage is not only found in association with OPMD, but also CMI as an independent factor.

Yoithapprabhunath *et al.*[1] analyzed genetic damage through the frequency of MN in young individuals exposed to CMI in the lateral border of the tongue due to sharp teeth. There was an increase in MN frequency in the sharp tooth-associated lateral border of the tongue, when compared with the normal side, hence concluded that sharp teeth induced CMI can act as a sole/associated factor in the initiation and promotion of multistep carcinogenesis.[1] Piemonte *et al.*[17] analyzed the association of OC with CMI of the oral mucosa and reported that the available evidence suggests that CMI could play a role at least as a tumor promoter, but the pathological mechanisms are still not completely understood. If CMI could only act to increase exposure or penetration of carcinogens, its role would be tied to the absorbed carcinogen. CMI could be regarded as a risk factor for OC.[17] Kohli *et al.*[18] have analyzed the genotoxic changes using the micronucleus assay in patients with tobacco use, oral leukoplakia, and oral submucous fibrosis. They found that a significant increase in the count was observed during the transition of normal mucosa to OPMDs.[18]

In this study, a significant difference in the distribution of AgNOR dots was found between the control group and the study group having CMI with OPMD. No significant difference in the distribution of AgNOR dots was found between CMI without OPMDs and CMI with OPMDs.

Fontes *et al.*[19] have evaluated the AgNOR count in the tongues of smokers and nonsmokers. The results indicate that higher proliferative activity was noted in smoking patients compared to nonsmoking patients, even in the absence of clinical lesions. They concluded that a larger number of AgNOR proteins in exfoliative cytology specimens obtained from the mucosa of the lateral border of the tongue in smokers who presented with no clinically visible alterations, when compared to nonsmokers.[19] Sharma *et al.*[10] have quantified the AgNOR expression in exfoliated oral mucosal cells of tobacco chewers with and without lesions. They found that a significant difference was observed between tobacco chewers with and without lesions.[11] Jindal *et al.*[20] have assessed the silver-stained nucleolar organizer regions and MN in buccal mucosal cells due to the effect of tobacco and alcohol. Cytological changes in each group revealed an increase in mean AgNORs and MN count in subjects with combined alcohol and tobacco consumption when compared with individual groups.[20] Significant increase in MN counts and AgNOR counts in this study demonstrates that CMI not only acts as a cofactor in causing genetic damage, inhibition of gene repair mechanisms, and also induces proliferative activity that results in the initiation and progression of the neoplastic process.

In this study, the comet assay showed a significant difference in the increase of tail length between the study groups and the control group. Among study groups, no significant difference in the increase of tail length was appreciated between CMI with OPMD and CMI without OPMD.

Mohanapriya *et al.*[16] studied DNA damage in tobacco-associated human buccal cells using the comet assay and reported that there was increased tail length among the tobacco-associated individuals. The study suggested that assessment of potentially malignant lesions with the comet assay will help in early detection of DNA damage and prevent the malignant transformation at a much earlier stage.[15] In contrast to our study, no difference was found between the malignant group and the normal group in a study conducted by Harréus *et al.*[21] However, they suggested that a combination of the comet assay and the FISH technique enables the identification of DNA damage and repair in specific chromosomes and genetic sites. Hence, a significant increase in DNA damage is not only found in CMI with OPMD group, but also in CMI without OPMD, where CMI can act as an independent factor in causing DNA damage.

The results from this study state a strong relationship between CMI due to the presence of sharp teeth and MN formation, even in the absence of any habits such as the usage of tobacco in smoking/smokeless form, areca nut chewing, or alcohol consumption. These findings correlate with the existing literature that any CMI will result in inflammation, which paves the way to genetic instability such as MN formation, AgNOR dots, and comet tail formation. Studies have indicated that the DNA damage can be due to many reasons, but CMI is an unnoticeable cause of DNA damage without the knowledge of the patient. The MN count, AgNOR, and comet assay are excellent and reliable tools to detect the cytogenetic damage and proliferative potential of the cell.

While these findings provide valuable insights into the role of CMI in the development of OPMDs, certain methodological limitations should be acknowledged. In interpreting the results, it should be noted that the CMI cases included were of heterogeneous origin. Although participants with irritation lasting more than 6 months were selected to maintain consistency, variations in the intensity and nature of CMI could not be completely standardized, which may have contributed to minor variability in the outcomes. Despite this, the observed associations remained consistent, supporting the relevance of CMI as a contributing factor in oral mucosal pathology. Lack of a full range of information during data collection, potential variability between operators, difficulty in quantifying oxidative damage, potential artifacts, achieving isolated cells, and limited time/sample size for the study were also considered to be limitations for this study.

## Conclusion

CMI in the oral cavity acts as a form of chronic stress that can lead to genotoxic effects, including DNA damage, but is frequently under-considered as an independent factor in causing oral cytogenetic damage in the affected oral mucosa. CMI, by inducing oxidative stress and inhibiting DNA repair mechanisms, facilitates a "silent" accumulation of genetic instability without the patient's awareness. Consequently, CMI must be elevated from a secondary clinical observation to a primary risk factor in OC screenings because the clinical significance of CMI is frequently underrepresented in risk assessments. Early detection of CMI through prevention programs and elimination of mechanical irritants are vital to preventing the progression of the multistep carcinogenesis process.

### Financial support and sponsorship

Nil.

### Conflicts of interest

There are no conflicts of interest.

## References

1. Yoithapprabhunath TR, Ganapathy N, Renugadevi S, Rafath JM, Aparna V, Dineshshankar J. Cytogenetic analysis of genetic damage in young individuals exposed to chronic mechanical irritation in the lateral border of the tongue due to sharp teeth – A novel study. Med Pharm Rep 2021;94:88-93.
2. Bray F, Laversanne M, Sung H, Ferlay J, Siegel RL, Soerjomataram I, *et al*. Global cancer statistics 2022: GLOBOCAN estimates of incidence and mortality worldwide for 36 cancers in 185 countries. CA Cancer J Clin 2024;74:229-63.
3. Piemonte ED, Gilligan GM, Garola F, Lazos JP, Panico RL, Normando AGC, *et al*. Differences among oral carcinomas arising de novo from those associated with oral potentially malignant disorders: A systematic review and meta-analysis. Oral Surg Oral Med Oral Pathol Oral Radiol 2024;137:613-31.
4. Aljohani K, Alqarni A, Harte M, Alghamdi R, Alzahrani S, Albuquerque R. Oral potentially malignant disorders and oral cancer in Saudi Arabia: An epidemiological review of the literature. J Clin Med 2024;13:1376.
5. Piemonte ED, Lazos JP, Gilligan GM, Panico RL, Werner LC, Yang YH, *et al*. Chronic mechanical irritation enhances the effect of tobacco and alcohol on the risk of oral squamous cell carcinoma: A case-control study in Argentina. Clin Oral Investig 2022;26:6317-26.
6. Gupta AA, Kheur S, Varadarajan S, Parveen S, Dewan H, Alhazmi YA, *et al*. Chronic mechanical irritation and oral squamous cell carcinoma: A systematic review and meta-analysis. Bosn J Basic Med Sci 2021;21:647658.
7. Jaitley S, Agarwal P, Upadhyay R. Role of oral exfoliative cytology in predicting premalignant potential of oral submucous fibrosis: A short study. J Cancer Res Ther 2015;11:471-4.
8. Fenech M, Kirsch-Volders M, Natarajan AT, Surralles J, Crott JW, Parry J, *et al*. Molecular mechanisms of micronucleus, nucleoplasmic bridge and nuclear bud formation in mammalian and human cells. Mutagenesis 2011;26:125-32.
9. Singam PK, Majumdar S, Uppala D, Kotina S, Namana M, Ayyagari KR. Evaluation of genotoxicity by micronucleus assay in oral leukoplakia and oral squamous cell carcinoma with deleterious habits. J Oral Maxillofac Pathol 2019;23:300.
10. Sharma A, Saxena S. Quantification of AgNOR expression in exfoliated oral mucosal cells of tobacco chewers with and without lesion. Indian J Dent Res 2012;23:251-6.
11. Kabaklıoğlu M, Eroz R, Kaya M. May argyrophilic nucleolar organizer regions be used as a biomarker for the detection of the degree of ischemic damage instead of tunel in testicular torsion? Medicina 2021;57:1177.

12. Russo C, Acito M, Fatigoni C, Villarini M, Moretti M. B-Comet assay (Comet assay on buccal cells) for the evaluation of primary DNA damage in human biomonitoring studies. Int J Environ Res Public Health 2020;17:9234.
13. Madhulika N, Rangdhol RV, Sitra G, Ballaiah J, Jaikumar RA, Brooklyin S. A case-control study to detect the extent of DNA damage in oral lichen planus and oral lichenoid reactions using comet assay. J Pharm Bioallied Sci 2015;7:S451-6.
14. Piemonte ED, Lazos J. Evidence for chronic mechanical irritation as a causative factor in oral cancer: Application of Bradford Hill criteria. Transl Res Oral Oncol 2018;3:2057178X18791034.
15. Lazos JP, Piemonte ED, Lanfranchi HE, Brunotto MN. Characterization of chronic mechanical irritation in oral cancer. Int J Dent 2017;2017:6784526.
16. Mohanapriya S, Maheswaran T, Ganapathy N, Yoithapprabhunath TR, Dineshshankar J, Ilayaraja V, *et al*. Evaluation of DNA damage in tobacco associated human buccal cells using comet assay. Med Pharm Rep 2021;94:214-9.
17. Piemonte E, Lazos J, Belardinelli P, Secchi D, Brunotto M, Lanfranchi-Tizeira H. Oral cancer associated with chronic mechanical irritation of the oral mucosa. Med Oral Patol Oral Cir Bucal 2018;23:e151-60.
18. Kohli M, Ahuja P, Mehendiratta M, Sharma M, Dutta J. Micronucleus assay: An early diagnostic tool to assess genotoxic changes in patients with tobacco use, oral leukoplakia and oral submucous fibrosis. J Clin Diagn Res 2017;11:ZC28-32.
19. Fontes PC, Corrêa GH, Issa JS, Brandão AA, Almeida JD. Comparison of exfoliative pap stain and AgNOR counts of the tongue in smokers and nonsmokers. Head Neck Pathol 2008;2:157-62.
20. Jindal S, Chauhan I, Grewal HK. Alteration in buccal mucosal cells due to the effect of tobacco and alcohol by assessing the silver-stained nucleolar organiser regions and micronuclei. J Cytol 2013;30:174-8.
21. Harréus UA, Kleinsasser NH, Zieger S, Wallner B, Reiter M, Schuller P, *et al*. Sensitivity to DNA-damage induction and chromosomal alterations in mucosa cells from patients with and without cancer of the oropharynx detected by a combination of Comet assay and fluorescence in situ hybridization. Mutat Res 2004;563:131-8.