https://doi.org/10.46389/rjd-2023-1140
Rom J Diabetes Nutr Metab Dis2023;
www.jrdiabet.ro
Volume 30, Issue 4, pages 1140-1145

Original Article

CORRELATION OF MAXILLARY SINUS PATHOLOGIES WITH PERIAPICAL DISEASES OF MAXILLARY POSTERIOR TEETH USING CONE BEAM COMPUTED TOMOGRAPHY (CBCT) IN TAMILNADU POPULATION – A RETROSPECTIVE STUDY

Dr. Sivaraman G S[1*], Dr. Ramasamy Sarvathikari[2], Dr. Ahamed AMHR Alkandari[3], Dr. Khaja Khalid Nawaz[4], Dr Preethi Subramanian[5], Dr Arrvinthan SU[6]

[1*]M.D.S., Reader, Department of Oral Medicine and Radiology, Vivekanandha dental college for women, Tamilnadu, India
[2]M.D.S., Professor & HOD, Department of Oral Medicine and Radiology, Annamalai University, cuddalore, Tamilnadu, India
[3]B.D.S., Assitant Registrar, MOH, Kuwait
[4]M.D.S., FDS RCS (Eng)., FCGDent (Lon)., FICD., MFDS RCPS (Glasg)., MFDS RCS (Eng)., Senior Practitioner, Al Jahra speciality dental centre, MOH, Kuwait
[5]Senior lecturer, Department of Orthodontics, Vivekanandha dental college for women, Tamilnadu, India
[6]Senior lecturer, Department of Oral and Maxillofacial Surgery, Vivekanandha dental college for women, Tamilnadu, India

***Corresponding author:** Dr. Sivaraman G S
*M.D.S., Reader, Department of Oral Medicine and Radiology, Vivekanandha dental college for women, Tiruchengode - 637 205, Tamilnadu, India, E-mail: sivaramanmds@gmail.com

ABSTRACT:
Introduction: Odontogenic infections such as periapical lesions of maxillary posterior teeth can cause pathological changes in the maxillary sinus mucosa that could result in infectious, inflammatory, or traumatic changes in the maxillary sinus. CBCT, a cross-sectional 3-dimensional imaging modality can clearly analyse the relationship between the maxillary sinus and the maxillary root apices which could be helpful for proper clinical diagnosis and to provide prompt treatment plans.
Aim: To assess the maxillary sinus pathologies and its correlation with periapical diseases of maxillary posterior teeth using cone-beam computed tomography scans.
Materials and Methods: This retrospective study evaluated 300 CBCT scans (600 right and left maxillary sinuses) collected from various CBCT centres to represent Tamilnadu population. CBCT images were viewed using the proprietary software giving a panoramic reconstruction view module and the multiplanar reformations module i.e., axial, sagittal and coronal slices. The data obtained were analysed using SPSS version 25, IBM, USA.
Results: Mucosal thickening in the presence of Periapical abscess, Periapical granuloma, Periapical cyst and Breach was noted in 30%, 19.52%, 25% and 51.79% of cases respectively. Polypoidal mucosal thickening in the presence of Periapical abscess, Periapical granuloma, Periapical cyst and Breach was noted in 32.50%, 13.79%, 50% and 23.21% of cases respectively. Opacification in the presence of Periapical abscess, Periapical granuloma, Periapical cyst and Breach was noted in 30%, 19.52% 25% and 51.79% of cases respectively.
Conclusion: This study concluded that the maxillary sinus pathologies have direct correlation with periapical diseases of the maxillary posterior teeth. Therefore, thorough radiographic assessment is necessary for early diagnosis and treatment in cases of chronic odontogenic infections with close proximity to maxillary sinus to prevent maxillary sinus pathologies.

Keywords: Cone-beam computed tomography, Maxillary sinus pathologies, Mucosal thickening, Polypoidal mucosal thickening, Opacification, odontogenic infections, Periapical pathologies

INTRODUCTION:

The maxillary sinus pathologies are often seen in patients with chronic odontogenic infections such as periapical lesions, cysts or tumors.[2] Maxillary sinusitis is a common condition with significant health-related complications. Identifying the relationship between the maxillary sinus pathologies and periapical diseases particularly of maxillary posterior teeth is essential to establish correct diagnosis and prompt treatment plan for the patients. Radiographic assessment plays a crucial role in identifying the relationship between the maxillary sinus and the maxillary root apices.
Cone-beam computerized tomography (CBCT), a 3-dimensional imaging modality, is increasingly employed for maxillofacial radiology. CBCT provides

© 2023 The Authors. Romanian Journal of Diabetes, Nutrition and Metabolic Diseases published by Sanatatea Press Groupon behalf of the Romanian Society of Diabetes Nutrition and Metabolic Diseases. This is an open access article under the terms of the Creative Commons Attribution License (CC-BY-NC- ND 3.0)

essential information on both dental and maxillofacial structures. As compared to Computed tomography (CT), CBCT imaging provides high-quality and high contrast 3-dimensional images with more rapid acquisition and less scanning time using a negligible radiation dosage.[1]

CBCT is more frequently indicated for assessment of dental implant site, periapical and periodontal pathologies, endodontic lesions, maxillofacial trauma and infections, temporomandibular joint (TMJ) pathology, orthodontics, impacted and supernumerary teeth, developmental and congenital jaw deformities.[2] The increase in use of CBCT by dentists and maxillofacial radiologists opens up an opportunity for evaluation of relationship between the maxillary sinus and odontogenic pathologies, which would be helpful for proper diagnosis and management of the patient.[2]

The purpose of the study was to retrospectively assess the maxillary sinus pathologies and its correlation with periapical diseases of maxillary posterior teeth using CBCT images.

Methods:

Source of data:

This study is a retrospective study, which was conducted in the Department of Oral Medicine and Radiology.

Ethical clearance:

A detailed protocol of this study was submitted to the institutional Ethical committee and the study was conducted after obtaining ethical committee approval.

Sample size:

A total of 300 CBCT scans (600 right and left maxillary sinuses) were collected from various CBCT centres in Madurai, Chennai, Salem and Tirunelveli to represent the Tamilnadu population. CBCT scans of patients ranged from 18 to 70 years of age were included in the study. Digitized CBCT images were selected based on the inclusion and exclusion criteria.

Inclusion criteria:

The CBCT scans indicated for –

- Assessment of dental implant site
- Surgical extraction of complex tooth
- Orthodontic treatment planning
- Trauma cases without involving maxilla
- TMJ evaluation
- Endodontic procedures
- Periapical and periodontal pathologies

Exclusion criteria:

The CBCT scans of –

- Patients below 18 years of age
- Patients with maxillofacial trauma involving the middle one-third of the face and who had undergone maxillofacial surgery
- Patients with bone pathologies like skeletal asymmetries, congenital disorders and anomalies
- Images with artefacts

The sample size was categorized into six age groups, Group (1) 18-25; Group (2) 26-35; Group (3) 36-45; Group (4) 46-55; Group (5) 56-65 and Group (6) 66-70 years of age.

Figure 1: Mucosal thickening – OPG view

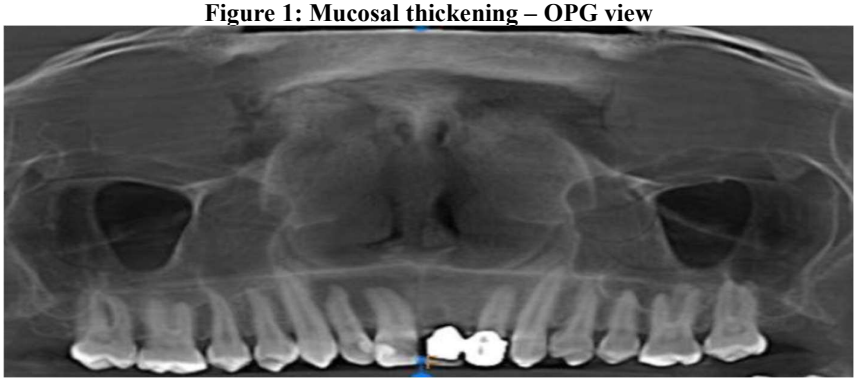

Figure 2: Opacification of maxillary sinus- Axial view

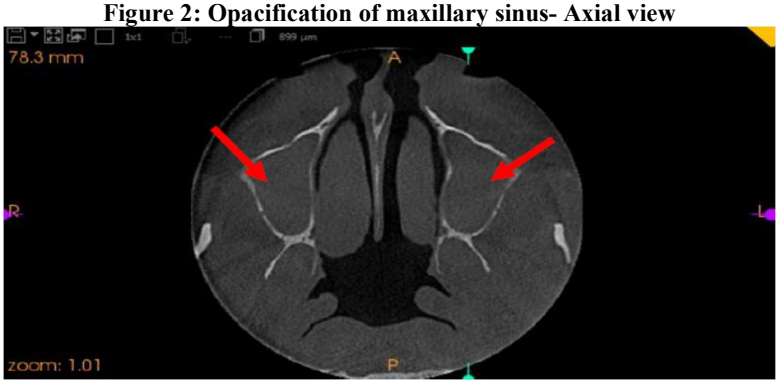

Figure 3: Opacification of maxillary sinus- Sagittal view

https://doi.org/10.46389/rjd-2023-1140
© 2023 The Authors

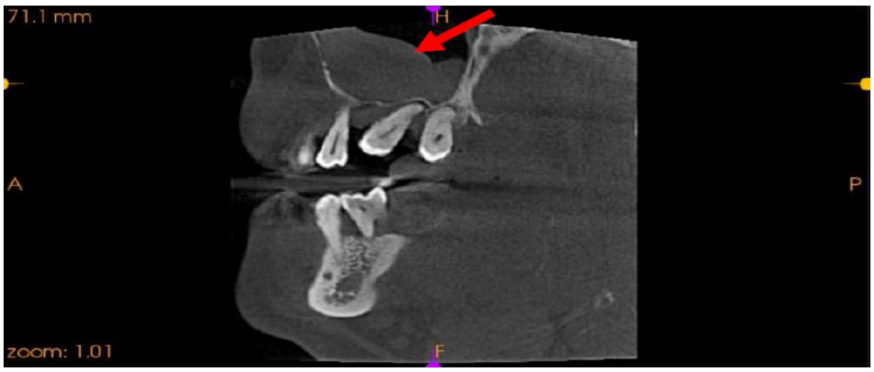

Figure 4: Periapical abscess in relation to 15 with mucosal thickening of right maxillary sinus

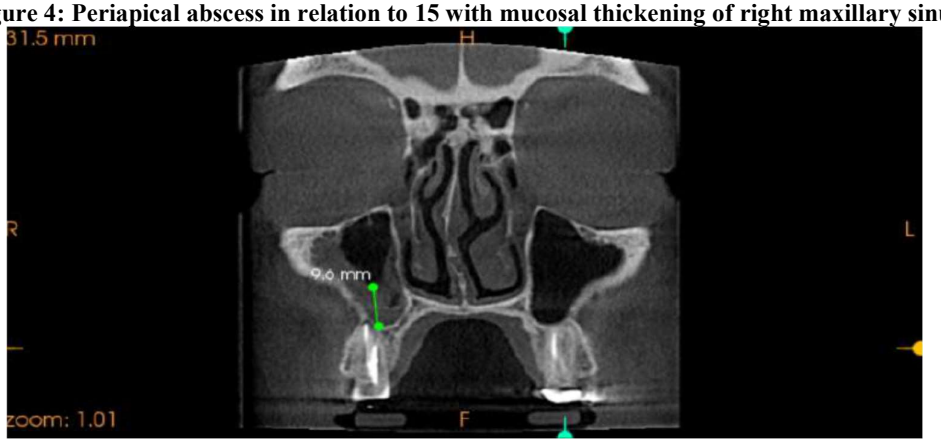

Figure 5: Periapical abscess in relation to 15 with Polypoidal mucosal thickening of right maxillary sinus

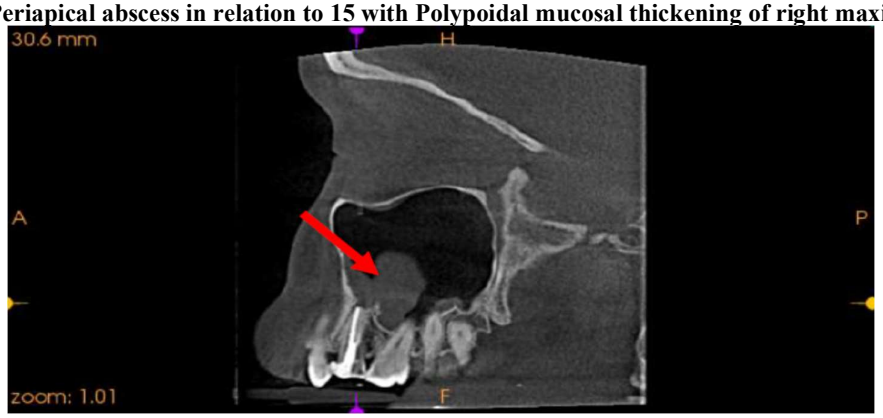

Figure 6: Generalised chronic periodontitis with breach in the Left maxillary sinus



The CBCT scans were obtained with an X-ray tube and Image intensifier/CCD detector. The exposure factors were field of view ranging from 5x5 mm to 17x13.5 mm, with X-ray source voltage and current of 80-90 kvp

and 5 mA respectively and voxel size 90-500µ. The data acquired from CBCT imaging was reconstructed with 0.2mm slice interval and thickness. The CBCT images were viewed using the proprietary software giving a panoramic reconstruction view module and the multiplanar reformations module, i.e., axial, sagittal, and coronal slices. The images were assessed under standardized conditions at the same examination workplace. To prevent inter- and intra- observer bias, all the observations were carried out by two maxillofacial radiologists and the observers were allowed to adjust brightness and contrast of the images and to zoom. In the event of any disagreement, the images were evaluated again and a consensus was reached by discussion between the two observers.

STATISTICAL ANALYSIS:

After data collection, data entry was done in Excel sheet and the analysis was performed with SPSS Software Version 25, IBM statistics, USA. Descriptive statistics were presented with the help of frequency and percentage table. The results were analysed using Chi-square test and the correlation coefficients. The level of significance was set as $p< 0.05$ and the inter-observer agreement was assessed by Kappa statistics.

RESULTS:

A total of 300 (600 right and left maxillary sinuses) CBCT files were retrospectively analysed wherein, the most common findings of maxillary sinus pathologies included mucosal thickening in the right and left maxillary sinuses of 40.65% and 46.45%, respectively, radiopacification in the right and left maxillary sinuses of 62.71% and 23.73%, respectively, and Polypoidal mucosal thickening in the right and left maxillary sinuses were similar with the prevalence of 40.21% as shown in **Table 1**.

The most common indications for CBCT scans were for the assessment of the dental implant site (30.67%),

Endodontic procedures (29.00%), Orthodontic treatment planning (16.67%), Surgical extraction of complex tooth extraction (8.67%), TMJ evaluation (4.66%) and Trauma without maxillary involvement (4.33%) as shown in **Table 2**.
Furthermore, the relationship between the maxillary sinus pathologies and periapical diseases showed Mucosal thickening in the presence of Periapical abscess, Periapical granuloma, Periapical cyst and Breach was noted in 30%, 19.52%, 25% and 51.79% of cases respectively. Polypoidal mucosal thickening in the presence of Periapical abscess, Periapical granuloma, Periapical cyst and Breach was noted in 32.50%, 13.79%, 50% and 23.21% of cases respectively. Opacification in the presence of Periapical abscess, Periapical granuloma, Periapical cyst and Breach was noted in 30%, 19.52% 25% and 51.79% of cases respectively and a statistically significant correlation was found between the maxillary sinus pathologies and periapical lesions of maxillary posterior teeth as shown in **Table 3**.

DISCUSSION:

In dentistry, 3-dimensional imaging technologies have a wide range of potential advantages with its capability to collect thin slices, provide multiplanar images and permit visualization of the bone and soft tissues.[5] CBCT machines specifically designed for maxillofacial imaging have extensive applications in dentistry which is an alternative to conventional fan beam helical computed tomography (CT) machines.[6,7]

Therefore, the present study evaluated the relationship between maxillary sinus pathologies and periapical diseases of maxillary posterior teeth using CBCT images and corroborated the aforementioned potential abilities of CBCT imaging in identification of odontogenic origin of maxillary sinus pathologies.
The roots of the maxillary posterior teeth with pulpal inflammation or periapical lesions that are present in close proximity to the maxillary sinus floor can cause inflammatory changes in the mucosal lining that may result in maxillary sinusitis.[16] Depending on the severity of odontogenic infection, the disease can range from a simple sinusitis to severe rhino sinusitis and even brain abscess.[4]

In the present study, the most common findings of maxillary sinus pathologies included mucosal thickening which was more frequently observed than other diseases. These findings were consistent with other studies by Raghav et al.[8] (35.1%), Munde et al.[11] (25.3%), Pazera et al.[9] (23.7%) and Malik et al., Mucosal thickening was typically associated to some kind of irritation, such as allergic reactions or odontogenic disease.

Table 1: Frequency of radiographic findings of maxillary sinus pathologies

	Mucosal thickening		Polypoidal Mucosal thickening		Opacification	
	N	%	N	%	N	%
Left side	72	46.5	39	40.21	14	23.73
Right side	63	40.65	39	40.21	37	62.71
Both side	20	12.90	19	19.58	8	13.56

https://doi.org/10.46389/rjd-2023-1140
© 2023 The Authors

Table 2: Prevalence of patients indicated for CBCT scans

Indications	Numbers(N)	%
Dental implant site assessment	92	30.7
Surgical extraction of complex tooth	26	8.67
Orthodontic treatment planning	50	16.7
Trauma without involving maxilla	13	4.33
TMJ evaluation	14	4.66
Endodontic procedures	87	29
Periapical and periodontal pathology	18	6

Table 3: Frequency of maxillary sinus pathologies associated to the periapical lesions

	Periapical abscess		Periapical granuloma		Periapical cyst		Breach		χ^2	p
	N	%	N	%	N	%	N	%		
Mucosal thickening	12	30	19	19.52	1	25	29	51.79	**281.44**	**0.0001**
Polypoidal mucosal thickening	13	32.5	4	13.79	2	50	13	23.21		
Opacification	15	37.5	6	20.69	2	25	14	25		
Total	40	100	29	100	4	100	56	100		

The most common indications for CBCT scans that were included in this study were for the assessment of dental implant site (30.67%). These findings correlated with other studies conducted by Ritter et al.[10] and Raghav et al.[8] wherein 6.53% and 24.3% of CBCT scans respectively, were indicated for dental implant site assessment.

Remarkably, the present study showed that Mucosal thickening in the presence of Periapical abscess, Periapical granuloma, Periapical cyst and Breach was noted in 30%, 19.52%, 25% and 51.79% of cases respectively. This result was consistent with that of a systematic review by Eggmann et al.[13], Shanbhag et al.[14] and Lu et al.[16]

Polypoidal mucosal thickening in the presence of Periapical abscess, Periapical granuloma, Periapical cyst and Breach was noted in 32.50%, 13.79%, 50% and 23.21% of cases respectively. This result supported the prevalence reported by Zadsirjan et al.[3] and Nunes et al.[14] which ranged from 6.5% to 19.4% and 23% respectively.

Opacification in the presence of Periapical abscess, Periapical granuloma, Periapical cyst and Breach was noted in 30%, 19.52% 25% and 51.79% of cases respectively.

However, the present study had certain limitations. The sample size was less size to represent the population of Tamil Nadu and sample collection could be considerably increased from various other CBCT centres in Tamil Nadu. Since this was a retrospective study, various sociodemographic variables such as history of smoking and the onset of infection was lacking.

To improve the accuracy, future studies should take into account, the clinical assessment of patients and evaluation of their medical data with an increase in the sample size to yield better results.In spite of the limitations, the present study shows that CBCT scans play a crucial role in early diagnosis of pathologies in asymptomatic patients.

CONCLUSION:

The present study concluded that there was a significant correlation between maxillary sinus pathologies and periapical diseases of maxillary posterior teeth. Hence oral and maxillofacial radiologists need to have a thorough radiographic assessment for early diagnosis and prompt treatment in cases of chronic odontogenic infections with close proximity to maxillary sinus to prevent maxillary sinus pathologies.

REFERENCES:

1. Jouhar R, Alkhames HM, Ahmed MA, Almadeh NM, Faheemuddin M, Umer MF. CBCT Evaluation of Periapical Pathologies in Maxillary Posterior Teeth and Their Relationship with Maxillary Sinus Mucosal Thickening. InHealthcare 2023 Mar 7 (Vol. 11, No. 6, p. 787). MDPI.
2. Raghav M, Karjodkar FR, Sontakke S, Sansare K. Prevalence of incidental maxillary sinus pathologies in dental patients on cone-beam computed tomographic images. Contemporary clinical dentistry. 2014 Jul;5(3):361.
3. Zadsirjan S, Sheikhi M, Dakhilalian A, Feli M. Association of Inflammatory Periapical Lesions with Maxillary Sinus Abnormalities: a Retrospective Cone-Beam Computed Tomography Study. Journal of Dentistry. 2021 Dec;22(4):273.
4. Vijayan A, Sreejith VP, Surendran R, Ahamed G. Orbital abscess arising from an odontogenic infection. J Contemp Dent Pract. 2012 Sep 1;13(5):740-3.
5. Nair UP, Nair MK. Maxillary sinusitis of odontogenic origin: cone-beam volumetric computerized tomography–aided diagnosis. Oral Surgery, Oral Medicine, Oral Pathology, Oral Radiology, and Endodontology. 2010 Dec 1;110(6):e53-7.
6. Ludlow JB, Timothy R, Walker C, Hunter R, Benavides E, Samuelson DB, Scheske MJ. Effective dose of dental CBCT—a meta analysis of published data and additional data for nine CBCT units. Dentomaxillofacial Radiology. 2015 Jan;44 (1):20140197.

© 2023 The Author

7. Ludlow JB, Ivanovic M. Comparative dosimetry of dental CBCT devices and 64-slice CT for oral and maxillofacial radiology. Oral Surgery, Oral Medicine, Oral Pathology, Oral Radiology, and Endodontology. 2008 Jul 1;106(1):106-14.
8. Raghav M, Karjodkar FR, Sontakke S, Sansare K. Prevalence of incidental maxillary sinus pathologies in dental patients on cone-beam computed tomographic images. Contemporary clinical dentistry. 2014 Jul;5(3):361.
9. Pazera P, Bornstein MM, Pazera A, Sendi P, Katsaros C. Incidental maxillary sinus findings in orthodontic patients: a radiographic analysis using cone-beam computed tomography (CBCT). Orthodontics & craniofacial research. 2011 Feb;14(1):17-24.
10. Ritter L, Lutz J, Neugebauer J, Scheer M, Dreiseidler T, Zinser MJ, Rothamel D, Mischkowski RA. Prevalence of pathologic findings in the maxillary sinus in cone-beam computerized tomography. Oral Surgery, Oral Medicine, Oral Pathology, Oral Radiology, and Endodontology. 2011 May 1;111(5):634-40.
11. Munde AD, Sawade R, Nayak P, Deshpande A, Mishra SS, Farooqui A. Incidental findings of maxillary sinuses in Cone Beam Computed Tomography (CBCT). Annals of the Romanian Society for Cell Biology. 2021 Jun 3;25(6):7441-52.
12. Eggmann F, Connert T, Bühler J, Dagassan-Berndt D, Weiger R, Walter C. Do periapical and periodontal pathologies affect Schneiderian membrane appearance? Systematic review of studies using cone-beam computed tomography. Clinic Oral Invest. 2017; 21: 1611-1630
13. Shanbhag S, Karnik P, Shirke P, Shanbhag V. Association between periapical lesions and maxillary sinus mucosal thickening: a retrospective cone-beam computed tomographic study. Journal of endodontics. 2013 Jul 1;39(7):853-7.
14. Nunes CA, Guedes OA, Alencar AH, Peters OA, Estrela CR, Estrela C. Evaluation of periapical lesions and their association with maxillary sinus abnormalities on cone-beam computed tomographic images. Journal of Endodontics. 2016 Jan 1;42(1):42-6.
15. Rege IC, Sousa TO, Leles CR, Mendonça EF. Occurrence of maxillary sinus abnormalities detected by cone beam CT in asymptomatic patients. BMC oral health. 2012 Dec;12:1-7.
16. Lu Y, Liu Z, Zhang L, Zhou X, Zheng Q, Duan X, Zheng G, Wang H, Huang D. Associations between maxillary sinus mucosal thickening and apical periodontitis using cone-beam computed tomography scanning: a retrospective study. Journal of endodontics. 2012 Aug 1;38(8):1069-74.

 https://doi.org/10.46389/rjd-2023-1140 © 2023 The Authors