ORIGINAL RESEARCH

Rat Subcutaneous Tissue Reaction to New Dental Restorative Composite Resin Copolymers Containing 2π + 2π Photo-dimerized Cinnamyl Methacrylate Crosslinker: A Histocompatibility Research

Ranganathan Ajay[1], Murugesan Sreevarun[2], Nasir N Nisha[3], Venkatesan Sudhakar[4], Kalyanasundaram Srinath[5], Karthigeyan Suma[6]

Received on: 01 November 2024; *Accepted on:* 04 December 2024; *Published on:* 20 June 2025

Abstract

Aim: To investigate the histocompatibility of newly developed restorative composite resins (RCR) copolymers photocured with photo-dimerized cinnamyl methacrylate (PD-CMA) photo-crosslinker, engrafted in rats subdermally.

Materials and methods: The experiment involved 18 male Wistar rats. Resins were prepared by mixing the base monomers (B) with or without triethyleneglycol dimethacrylate (TEGDMA; D) and PD-CMA. Photocured copolymeric specimens were categorized into four groups: control group—no PD-CMA + 20 wt.% TEGDMA [C0; P(BD)]; experimental groups—10 wt.% PD-CMA + 10 wt.% TEGDMA [E10; P(BD-Co-CMA)], and 20 wt.% PD-CMA without TEGDMA [E20; P(B-Co-CMA)]. A specimen from each group was surgically implanted subcutaneously in each rat's dorsum at three different sites, with a fourth negative control group (NC) site without implantation. The implantation sites were resected after 1, 2, and 4 weeks, with six rats per week. The collected tissues were analyzed using histomorphometric and histopathological methods.

Results: Concerning the time intervals, a significant difference in the inflammation with C0 was observed, whereas there were no differences in the E10, E20, and NC. From least to most, the inflammatory degree was NC < E20 < E10 < C0. There were significant differences in fibrous capsular thickness among the groups across all time intervals and variations within each group at each specific time point.

Conclusion: P(BD-Co-CMA) and P(B-Co-CMA) exhibited superior histocompatibility in rats when compared to P(BD).

Clinical significance: The adverse effects of the TEGDMA can be circumvented when the RCR is formulated with the PD-CMA. The resultant biocompatible P(BD-Co-CMA) and P(B-Co-CMA) copolymers would function harmoniously in the oral cavity without inflicting adverse reactions on the surrounding tissues.

Keywords: Cinnamyl methacrylate, Cross-link, Histocompatibility, Photocure, Photo-dimerized.

World Journal of Dentistry (2025): 10.5005/jp-journals-10015-2519

Introduction

Restorative composite resins (RCR) are popular esthetic materials employed in restoring posterior teeth owing to high concerns of esthetics and shortcomings of mercury in amalgam restorations.[1] Despite the improvements in the physico-mechanical properties of RCRs, *in vivo* studies evinced that their utility is sometimes sequentially linked to pulpo-periodontal irritation and necrosis.[2,3] Numerous studies have been conducted on the physico-mechanical properties of resin composite restorative (RCR) containing base matrix monomers (B), especially bis-phenol-A-glycerolate dimethacrylate (bis-GMA) and diurethane dimethacrylate (DUDMA), as well as the diluent monomers (D), triethyleneglycol dimethacrylate (TEGDMA) and 2-hydroxy-ethylmethacrylate (HEMA), on their homo- and copolymeric forms.[4,5] Intracellular reactive oxygen species (ROS) are generated by leached unreacted monomeric residuum (UMR) and their hazardous byproducts, such as the ester derivative of 2,3-epoxy-2-methyl-propanoic acid, methacrylic acid, 2,3-epoxy-2-methylpropionic acid, and bis-phenol-A-bis-(2,3-dihydroxypropyl) ether. These ROS then cause inflammatory responses *via* inflammatory mediators.[6,7] The most common comonomer to leach in polymerized RCR is TEGDMA, which is thought to have a significant cytotoxic potential that inhibits cell

[1,2]Department of Prosthodontics and Crown & Bridge, Vivekanandha Dental College for Women, Tiruchengode, Tamil Nadu, India

[3]Department of Conservative Dentistry and Endodontics, MAHSA University, Jenjarom, Selangor, Malaysia

[4]Department of Conservative Dentistry and Endodontics, Adhiparasakthi Dental College and Hospital, Melmaruvathur, Tamil Nadu, India

[5]Department of Oral and Maxillofacial Surgery, Vivekanandha Dental College for Women, Tiruchengode, Tamil Nadu, India

[6]Department of Prosthodontics and Crown & Bridge, Government Dental College and Hospital, Cuddalore, Tamil Nadu, India

Corresponding Author: Murugesan Sreevarun, Department of Prosthodontics and Crown & Bridge, Vivekanandha Dental College for Women, Tiruchengode, Tamil Nadu, India, Phone: +91 9080730064, e-mail: dr.varunmds@gmail.com

How to cite this article: Ajay R, Sreevarun M, Nisha NN, *et al.* Rat Subcutaneous Tissue Reaction to New Dental Restorative Composite Resin Copolymers Containing 2π + 2π Photo-dimerized Cinnamyl Methacrylate Crosslinker: A Histocompatibility Research. World J Dent 2025;16(4):323–330.

Source of support: Nil

Conflict of interest: None

© The Author(s). 2025 Open Access. This article is distributed under the terms of the Creative Commons Attribution 4.0 International License (https://creativecommons.org/licenses/by-nc/4.0/), which permits unrestricted use, distribution, and non-commercial reproduction in any medium, provided you give appropriate credit to the original author(s) and the source, provide a link to the Creative Commons license, and indicate if changes were made. The Creative Commons Public Domain Dedication waiver (http://creativecommons.org/publicdomain/zero/1.0/) applies to the data made available in this article, unless otherwise stated.

growth.[8] Nevertheless, while contouring/polishing/removal of RCRs, their particulates could get lodged within labial[9] and gingival tissues, commonly proximal to class V restorations,[10] which could trigger tissue pathosis. Therefore, the biocompatibility of any dental biomaterial is of paramount importance. Among different methods for biocompatibility determination in the literature, *in vitro* cytotoxicity tests on cell cultures and subcutaneous connective tissue implantation in experimental mammals are customary.[11] One of the factors influencing the biocompatibility of RCR is chiefly its monomer-to-polymer conversion (MPC), which determines the UMR release quantity while polymerization.[12] The MPC percentage relies on sub-factors like the monomeric chemical structure, initiator type, and polymerization conditions.[13] Reduction in MPC could not only cause detrimental effects on the properties of RCRs but also elevate the UMR release.[14]

Many studies have created various modern polymerization chemistries for RCR materials with innovative compositions to develop myriad copolymers with improved properties, esthetics, and adhesion to hard tissues.[15] However, the biocompatibility of these copolymers is still uncertain. Additionally, the cytotoxicity of traditional organic matrix comonomers remains a persistent problem. Thus, there is a need to identify a new comonomer that improves the histocompatibility and overall properties of RCR when copolymerized with conventional comonomers.

Recently, Sreevarun et al.[16] photo-dimerized cinnamyl methacrylate (PD-CMA) and efficiently substituted/replaced the TEGDMA by copolymerizing it with the base-forming comonomers, yielding P(BD-Co-CMA) and P(B-Co-CMA) copolymers with higher MPC and glass transition temperature than the conventional resin. However, no research has looked at their possible inflammatory tissue reactivity in living beings. Hence, the current research aimed to assess the histocompatibility of these above-new RCR copolymers when implanted in rats' subdermal tissue. The null hypothesis states that the novel copolymers incorporating PD-CMA do not affect rats' histocompatibility.

Materials and Methods

The research was conducted at Swamy Vivekanandha College of Pharmacy, Tamil Nadu, and received authorization from the Institutional Animal Ethics Committee (Approval No. SVCP/IAEC/PhD/4/04/2020) for 2 months (January–February 2024). The materials employed in this study are tabulated in Table 1. CMA's photo-dimerization (PD) was executed by the method described by Sreevarun et al.[16]

Formulation of Composite Matrices and Photocuring

The control and experimental RCR matrices and fillers were quantified and blended by emulating the steps explained by Aydınoğlu and Yoruç.[17] The chemical formulation of the groups (control: C0; experimental: E10 and E20) and the resulting copolymers are delineated in Table 1. Disc-shaped specimens (4 mm diameter; 2 mm thick; $n = 54$) were prepared and photo-cured adhering to the technique described by Feiz et al.[18] The specimens in the C0 group ($n = 18$) were photo-cured without PD-CMA. The specimens in the E10 group ($n = 18$) were photo-cured with PD-CMA substituting TEGDMA partially, yielding P(BD-Co-CMA) copolymer. The specimens in the E20 group ($n = 18$) were photo-cured with PD-CMA replacing TEGDMA, yielding P(B-Co-CMA) copolymer.

Animal Model and Implantation Procedure

About 18 ($n = 18$) mature, 4–5 months male Wistar Albino rats (200–250 gm) were used in this research. The ARRIVE guidelines were rigorously followed for animal care. The animals were accommodated in poly(1-methylethylene) enclosures (23 ± 2°C; 55 ± 10% relative humidity) with unlimited access to water and rodent pellet food. Husk bedding in the cages was changed thrice a week.[19] The animals were then exposed to cyclic bright-dark ambiance for 12 hours every day for acclimatization. The rats were randomly divided into three sub-divisions based on the time of tissue harvesting ($n = 6$ per week; at the end of 1st, 2nd, and 4th week) for histological analysis.

The rats were anesthetized for approximately 30 minutes by intraperitoneal injection of ketamine hydrochloride (80 mg/kg—Ketajet®50) and xylazine (10 mg/kg—Xylaxin®). Four sites on the dorsal side of the rats, with maximum intersite distance, were selected, shaved, and disinfected. Incisions of 1 cm in length and 1 cm in depth were made at each site. The skin with connective tissue was divided from the underlying muscular fascia to create a pouch for the specimen's implantation. In each rat, the surgical site in the left cranial site was closed without specimen implants for the negative control (NC). The C0, E10, and E20 specimens were inserted into the right cranial, right caudal, and left caudal subcutaneous pouches, respectively, and sutured. The rats at appropriate time intervals were anesthetized at the end of the 1st, 2nd, and 4th week following the implantation. The resinous implants, along with a 1 cm margin of healthy subdermal tissues, were harvested and subsequently sutured. The tissues were preserved in 10% formalin. The tissue processing, sectioning, hematoxylin-eosin staining, 40× magnification, and histomorphometric measurements of the fibrous capsular thickness were followed as described by Sivakumar et al.[20] The measurements were performed by a single investigator. The thickness of the fibrous capsule around the implanted specimen was noted in the micrometer (µm). In terms of inflammation, cellular varieties in connective tissues were evaluated. The degree of tissue inflammation and the inflammatory process were qualitatively optimized using a scale of four points.[18] The inflammatory grading criteria are tabulated in Table 2.

The analysis of the data was carried out using the Statistical Package for the Social Sciences software (SPSS Inc., Chicago, IL, USA; version 29.0). The Kolmogorov–Smirnov and Shapiro–Wilk normality tests confirmed a normal distribution of the data for assessing fibrous capsular thickness through various times and groups. A one-way ANOVA test with Tukey HSD *post hoc* multiple

Table 1: Composition of matrices and their copolymers

	Composition and copolymer				
Group	*Base comonomers (B)*	*Diluent TEGDMA (D)*	*PD-CMA*	*Initiator and fillers*	*Copolymer*
C0	50 wt.% bis-GMA + 30 wt.% DUDMA	20 wt.%	Absent	CQ:DMAEMA (1:2) 1 wt.% 30 wt.% BaO + 30 wt.% BaF2 + 40 wt.% YSZ	P(BD)
E10		10 wt.%	10 wt.%		P(BD-Co-CMA)
E20		Absent	20 wt.%		P(B-Co-CMA)

70 wt.% fillers were added in the base comonomers in all the groups

Table 2: Description of the inflammatory grades

No inflammation (grade 0)	*Mild inflammation (grade I)*	*Moderate inflammation (grade II)*	*Severe inflammation (grade III)*
No inflammatory cells	Appearance of macrophages and/or plasma cells	Appearance of macrophages and/or plasma cells along with granulocytic-lymphocytic accumulation	A high density of inflammatory cellular infiltration
>30 fibroblasts	<30 inflammatory cells	Inflammatory cells range between 30 and 60	≥60 inflammatory cells
Mature fibrous tissue with many collagen fibers	Fibroblasts range between 10 and 30 Immature fibrous tissue with few collagen fibers	Fibroblasts range between 5 and 9	Local necrosis Fibroblasts range between 1 and 4

Table 3: The degree of inflammation and the mean (SD) fibrous capsular thickness

	1 week					*2 weeks*					*4 weeks*				
	Degree of inflammation				*Mean (SD) fibrous capsular thickness (μm)*	*Degree of inflammation*				*Mean (SD) fibrous capsular thickness (μm)*	*Degree of inflammation*				*Mean (SD) fibrous capsular thickness (μm)*
	0	*I*	*II*	*III*		*0*	*I*	*II*	*III*		*0*	*I*	*II*	*III*	
C0[bB]	0	1	5	0	450.63 (11.87)[aA]	0	0	3	3	416.14 (27.14)[aA]	1	4	1	0	259.73 (4.91)[aA]
E10[bc]	2	4	0	0	356.77 (14.46)[aA]	0	4	2	0	297.52 (15.82)[aA]	2	4	0	0	189.81 (13.58)[aA]
E20[bc]	2	4	0	0	222.80 (7.34)[aA]	4	2	0	0	176.76 (8.56)[aA]	6	0	0	0	117.25 (5.79)[aA]
NC[bc]	4	2	0	0	None	5	1	0	0	None	6	0	0	0	None

Fibrous capsular thickness: [a]substantial variation among the groups at every period ($p < 0.05$); [A]substantial variation across the groups at different periods ($p < 0.05$). Inflammation: [b]substantial variation among the groups at every period ($p < 0.05$); [B]substantial variation in C0 at different periods ($p < 0.05$); [c]insignificant differences in E10, E20, and NC at different time intervals ($p > 0.05$)

comparisons was performed ($\alpha = 0.05$). The Chi-square and Friedman tests were used to compare inflammatory levels between groups and week intervals ($\alpha = 0.05$).

Results

Table 3 summarizes the inflammation levels and mean fibrous capsule thickness [standard deviation (SD)] for each group across the three time points. Following the 1st week, C0 displayed mild (16.7%) to moderate (83.3%) inflammation, while E10 and E20 showed inflammation ranging from none (33.3%) to mild (66.7%) ($p = 0.002$). After 2 weeks, C0 showed moderate (50.0%) to severe (50.0%) inflammation, whereas E10 showed mild (66.7%) to moderate (33.3%) inflammation, and E20 displayed none (66.7%) to mild (33.3%) inflammation ($p = 0.001$).

In the 4th week, the inflammation in C0 varied from none to moderate (none: 16.6%; mild: 66.7%; moderate: 16.6%). The inflammation in E10 ranged between none (33.3%) and mild (66.7%), whereas, in E20, there was no inflammation (100%) ($p = 0.011$). At the 1st and 2nd weeks, the inflammatory reaction in the NC ranged from none to mild, with no inflammation after the 4th week. In the three time intervals, there was a substantial variation ($p < 0.008$) in inflammation with C0, whereas there were no significant differences in E10 ($p = 0.058$), E20 ($p = 0.091$), and NC ($p = 0.368$). In terms of inflammation, the order from lowest to highest was NC < E20 < E10 < C0. Considerable disparities in fibrous capsular thickness were evident among the groups at each time interval and within the groups across all three periods ($p < 0.05$). In all three time intervals, the fibrous capsule thickness was higher for the C0 group and lowest for the E20 group. Among the time intervals, the 4th week exhibited the least fibrous capsule thickness. Except for the NC, all other groups exhibited fibrous encapsulation around the implanted specimens. The histological results in both the control and experimental groups are shown in Table 4. Figures 1 to 3 show the histopathological characteristics of the groups related to the distinct resinous specimens at various periods. The lesser the fibrous capsule thickness, the greater the histocompatibility at each time interval. Therefore, P(BD-Co-CMA) and P(B-Co-CMA) copolymers were histocompatible with the rats' subcutaneous tissues.

Discussion

This study encompassed histological assessments performed at the 1st, 2nd, and 4th weeks, following the criteria set by the American National Standards Institute, to evaluate the short- and long-term tissue responses to the control and experimental resin specimens.[21] The photocuring of resinous substances conduces to the onset of a solid phase, which aids in minimizing the release of potentially obnoxious byproducts and stimulants. Nonetheless, photocured resins tend to deteriorate over time, and complete photocuring may not always be achievable, resulting in the leaching of potentially harmful components such as TEGDMA, HEMA, or bis-GMA, consequently eliciting unfavorable responses in cell cultures.[22,23,12,24] Studies have indicated that the cytotoxicity potential of fundamental monomers is most pronounced in the case of bis-GMA, succeeded by UDMA, TEGDMA, and HEMA.[25] Bis-GMA is recognized for its cytotoxic properties and provocation of synthetic estrogenicity,[5,26] while the lipophilic nature of TEGDMA facilitates its penetration into the cytoplasm and lipid bilayers of the mammalian cell membranes.[27]

Alizadehgharib et al.[28] revealed that the combination of TEGDMA and UDMA promoted a pro-inflammatory response in neutrophils, causing the secretion of interleukin-8 and the development of neutrophil extracellular traps. This could alter the body's inflammatory response, resulting in unpalatable immunological responses. Similarly, Reichl et al.[29] and Manojlovic et al.[30] found that the susceptibility of different cell lines to certain monomers fluctuated depending on the quantity and time of

Table 4: Histopathological descriptions of the groups

Time interval	*NC*	*C0*	*E10 and E20*
1 week (Figs 1A to D)	No to mild inflammatory alterations and no necrosis were noticed. There was no evidence of fibrosis or fibrous capsules	A substantial fibrous capsule was spotted with inflammation, tissue necrosis, and apparent fibrosis. The inflammatory reaction revealed an array of neutrophils and tissue macrophages	The results show a modest fibrinous inflammatory response with significant granulation tissue. The inflammatory cells ingress seemed slight, consisting primarily of lymphocytes, tissue macrophages, and some PMN cells
2 weeks (Figs 2A to D)	No to mild inflammatory alterations and no necrosis were noticed. There was no evidence of fibrosis or fibrous capsules	Inflammatory reactions ranged from moderate to severe involving the infiltration of PMNs and multinuclear giant cells with slight angiogenesis were observed. Also, there was marked thickening of the fibrous capsule	There was a marked reduction in inflammation, along with a regression of inflammatory cells. The fibrous capsule was lined with a layer of active fibroblasts, and the infiltration of inflammatory cells was less, consisting mainly of macrophages and lymphocytes
4 weeks (Figs 3A to D)	No inflammation was noted	An inflammatory response ranging from no to moderate was observed, with the presence of PMNs and lymphocytic infiltrations along with slight angiogenesis. Furthermore, there was a noticeable fibrous capsule thickening	As the healing process progressed, there was a gradual reduction in the infiltration of inflammatory cells. A well-formed fibrous capsule with multiple parallel collagen fibers was observed. The infiltration of lymphocytes and macrophages decreased significantly, indicating an appreciable reduction in inflammatory reactions

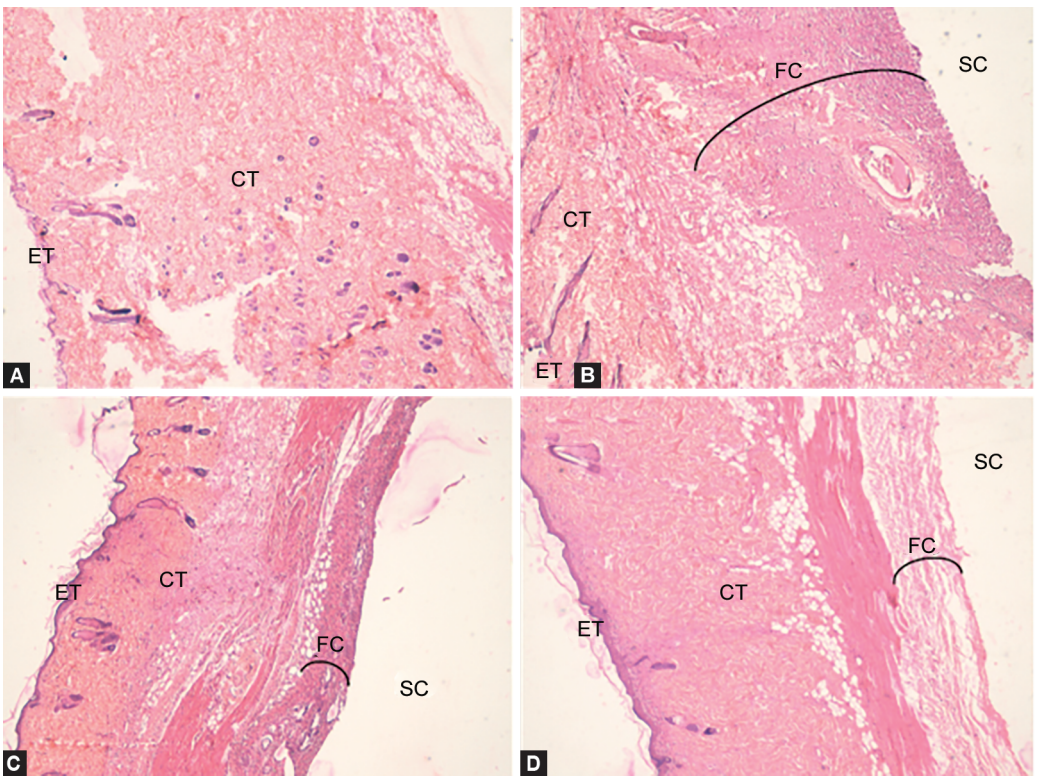

Figs 1A to D: Histological sections of the groups in 1st week; (A) NC; (B) C0; (C) E10; (D) E20. CT, connective tissue; ET, epithelium; FC, fibrous capsule; SC, specimen cavity. (Hematoxylin-eosin stained; 40× magnification)

exposure. Al-Hiyasat et al.[31] reported that TEGDMA absorption in the mice intestines diminished pregnancy by 54.5%. In a similar vein, Darmani and Al-Hiyasat[32] showed enteral TEGDMA administration for 28 days had a substantial detrimental impact on female mice's reproductive system. In cell culture experiments, TEGDMA displayed robust cytotoxicity and the capacity to rapidly permeate cell membranes, triggering interactions with intracellular components. It also caused a substantial amount of mutations owing to a crucial ablation of DNA regions. Furthermore, TEGDMA was revealed as a substantial sensitizer in patients as well as doctors.[27] Moreover, Gupta et al.[33] determined that TEGDMA encouraged the propagation of *Streptococcus mutans* and *Streptococcus salivarius* growth in a pH-sensitive pathway. TEGDMA became known to permeate the pulp, with worst-case values as high as 4 mM.[34,35] 3 mM TEGDMA activated both caspase-dependent and caspase-independent mechanisms of apoptosis in pulp cells, resulting in cell

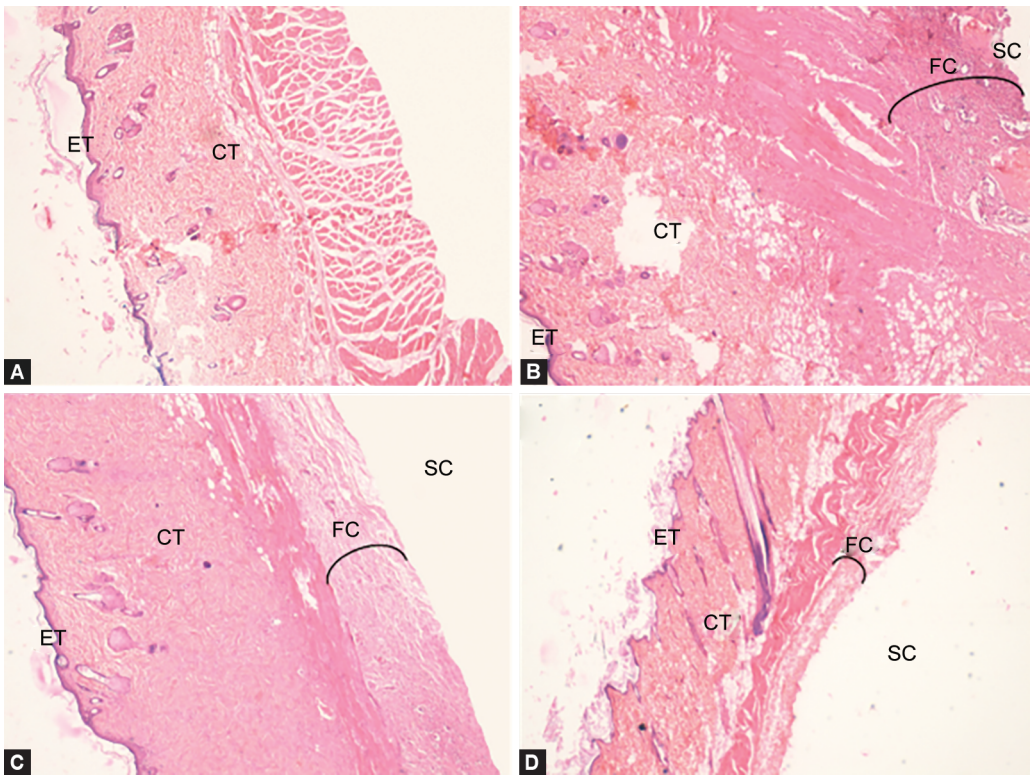

Figs 2A to D: Histological sections of the groups in 2nd week; (A) NC; (B) C0; (C) E10; (D) E20. CT, connective tissue; ET, epithelium; FC, fibrous capsule; SC, specimen cavity. (Hematoxylin-eosin stained; 40× magnification)

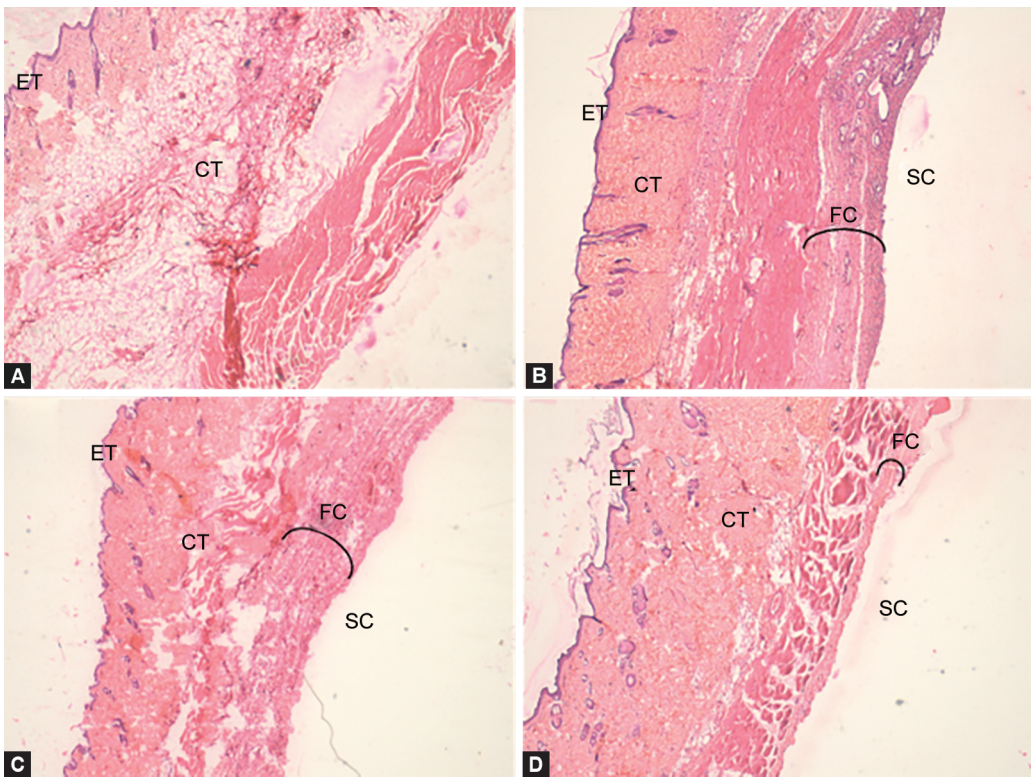

Figs 3A to D: Histological sections of the groups in 4th week; (A) NC; (B) C0; (C) E10; (D) E20. ET, epithelium; CT, connective tissue; FC, fibrous capsule; SC, specimen cavity. (Hematoxylin-eosin stained; 40× magnification)

death after a day's exposure.[36] Also, doses of 0.1–0.2 mM TEGDMA enhanced the intrapulpal synthesis of MMP-2, MMP-8, and MMP-9, activating collagenase.[37] Based on the aforementioned findings, in the current study, TEGDMA was partially substituted and completely replaced by the PD-CMA photo-crosslinker.

In the 1st week, mild-to-moderate inflammation was evident with both the control and experimental specimen implants, which subsequently progressed to moderate-to-severe inflammation at the end of the 2nd week. This was due to the UMR (conspicuously TEGDMA) being leached over time, which triggered adverse inflammatory responses. It is possible that the rats' immune system was unresponsive to the foreign bodies, which would explain the moderate or severe reaction.[18] After the 4th week, the inflammatory reactions reduced to moderate and mild levels due to the immune cells clearing UMR from the body. The E20 group exhibited the lowest inflammation compared to the C0 group, which showed the highest inflammation. The development of fibrous capsules or fibrosis around the resin implants demonstrates good tissue tolerance.[38,39] Similarly, in the present research, except for the NC sites, all the groups exhibited fibrous encapsulation around the specimen showing tissue tolerance with varying degrees of inflammatory reactions. Additionally, E20 specimens implanted subcutaneously displayed expedited healing with a distinct, thin fibrous capsule 4 weeks after the implantation. On the contrary, the C0 specimens demonstrated extensive fibrosis, which was evident up to the 4th week with a thick remodeling fibrous capsule. The tissue response of E10 implants was comparable to that of C0 specimens but with a significantly lower degree and a medium fibrous capsular formation. The compatibility of RCR is highly reliant on the size and chemical properties of the percolated UMR. Therefore, the PD-CMA photo-crosslinker present in E20 specimens produced favorable results and ultimately supported the acceptance of the null hypothesis. Based on the information provided above, it can be discerned that the experimental groups released minimal or negligible amounts of TEGDMA, which reduced inflammatory reactions and improved histocompatibility in the rats.

The current study's findings were largely in alignment with Ozbas et al.'s[11] study except for the 2nd week's highest inflammatory response. On the contrary, the peak inflammatory response exhibited by all the groups in the present study at the end of the 2nd week was congruent with the study conducted by Feiz et al.[18] Various factors such as the degree of conversion, matrix monomers' combinations, specimen dimensions, and engrafting techniques may have contributed to this disparity.[18] According to Ortengren et al.,[39,40] the maximum release of monomers took place within the initial 7 days. Hence, the release of monomers was monitored in this present study at the end of the 1st week following photo-polymerization. All groups of rats showed an ingress of polymorphonuclears (PMN), lymphocytes, fibroblasts, and epithelioid cells following the implantation of resin implants in their subcutaneous tissues. As time passed, the number of fibroblasts and epithelioid cells rose, and the lymphocytic ingress dropped. A granulomatous inflammatory reaction persisted in C0 even following 4 weeks of implantation, suggesting that the lodged resin particles in oral tissues can initiate persistent inflammation.[41] Therefore, animal trials are indispensable and mandatory to evaluate the histocompatibility of any newly developed resinous restorative material before clinical trials on humans. Animal histopathological studies have shown that the dimensions and physical form of these implanted materials can affect the tissue reactions, leading to toxicity and inflammation.[11] In some research studies, resin specimens were implanted directly into the subcutaneous connective tissues,[42] while in others, they were contained within inert tubes.[11,43] The shape and nature of the resin specimens also play a significant role in determining the histocompatibility.[44–47] The response of the tissue in these investigations varied from the presence of inflammatory cells to the formation of fibrous tissue around combined implants along with a low level of chronic inflammation.[41] To replicate the clinical scenarios, RCR implant specimens with a thickness of 2 mm were implanted in this present research.

The compatibility of dental biomaterials with living tissues can be determined in laboratory animals by subcutaneously implanting these materials. In the present study, the rats employed belong to nonprimate mammals. More appropriate results could have been derived by testing the specimens on primate mammals, such as orangutans, rhesus monkeys, etc. Nevertheless, efforts to obtain ethical clearance for primates were unattainable and unfeasible in the case of the present research. Biological and genetic differences between animals and humans can lead to results that do not accurately translate to human conditions. Treatments that work in animals may not have the same effects in humans. Animals are typically housed in controlled environments that differ significantly from human living conditions. This can influence the results and limit their applicability to real-world human scenarios. Different animal species and even individual animals may respond differently to the same experiment, leading to variability that complicates the interpretation of findings. Animal models are often limited in their ability to mimic complex human psychological, emotional, and social factors, which are critical in dentistry. These limitations mean that while animal models are valuable for preliminary research, their findings must be carefully validated in human studies. Future investigations shall be executed as human trials with the same experimental RCR specimens with PD-CMA.

Conclusion

Based on the findings of the conducted research, it can be concluded that the photocured RCR copolymers, namely P(BD-Co-CMA) and P(B-Co-CMA), containing 10 and 20 wt.% PD-CMA photo-crosslinking comonomer, exhibit superior histocompatibility in rats compared to the RCR copolymer P(BD) that had only TEGDMA diluent.

References

1. Sweeney M, Creanor SL, Smith RA, et al. The release of mercury from dental amalgam and potential neurotoxicological effects. J Dent 2002;30(5–6):243–250. DOI: 10.1016/s0300-5712(02)00040-4
2. Caughman WF, Caughman GB, Shiflett RA, et al. Correlation of cytotoxicity, filler loading, and curing time of dental composites. Biomaterials 1991;12(8):737–740. DOI: 10.1016/0142-9612(91)90022-3
3. Nasjleti CE, Castelli WA, Caffesse RG. Effects of composite restorations on the periodontal membrane in monkeys. J Dent Res 1983;62(1):75–78. DOI: 10.1177/00220345830620011801
4. Chang HH, Guo MK, Kasten FH, et al. Stimulation of glutathione depletion, ROS production and cell cycle arrest of dental pulp cells and gingival epithelial cells by HEMA. Biomaterials 2005;26(7):745–753. DOI: 10.1016/j.biomaterials.2004.03.021
5. Chang MC, Lin LD, Chan CP, et al. The effect of BisGMA on cyclooxygenase-2 expression, PGE_2 production and cytotoxicity via reactive oxygen species- and MEK/ERK-dependent and -independent pathways. Biomaterials 2009;30(25):4070–4077. DOI: 10.1016/j.biomaterials.2009.04.034

6. Seiss M, Langer C, Hickel R, et al. Quantitative determination of TEGDMA, BHT, and DMABEE in eluates from polymerized resin-based dental restorative materials by use of GC/MS. Arch Toxicol 2009;83(12):1109–1115. DOI: 10.1007/s00204-009-0470-7
7. Kostoryz EL, Eick JD, Glaros AG, et al. Biocompatibility of hydroxylated metabolites of BISGMA and BFDGE. J Dent Res 2003;82(5):367–371. DOI: 10.1177/154405910308200508
8. Engelmann J, Leyhausen G, Leibfritz D, et al. Metabolic effects of dental resin components *in vitro* detected by NMR spectroscopy. J Dent Res 2001;80(3):869–875. DOI: 10.1177/00220345010800030501
9. Goodman JR. Fractured composite restoration embedded in the lip. Br Dent J 1984;156(8):293–294. DOI: 10.1038/sj.bdj.4805347
10. Moore DL, Barker BF. A foreign body lesion of the gingiva subsequent to the placement of a composite resin restoration. Quintessence Int 1986;17(12):785–787. PMID: 3468528.
11. Ozbas H, Yaltirik M, Bilgic B, et al. Reactions of connective tissue to compomers, composite and amalgam root-end filling materials. Int Endod J 2003;36(4):281–287. DOI: 10.1046/j.1365-2591.2003.00649.x
12. Goldberg M. *In vitro* and *in vivo* studies on the toxicity of dental resin components: a review. Clin Oral Investig 2008;12(1):1–8. DOI: 10.1007/s00784-007-0162-8
13. Alshali RZ, Silikas N, Satterthwaite JD. Degree of conversion of bulk-fill compared to conventional resin-composites at two time intervals. Dent Mater 2013;29(9):e213–e217. DOI: 10.1016/j.dental.2013.05.011
14. Łagocka R, Jakubowska K, Chlubek D, et al. Elution study of unreacted TEGDMA from bulk-fill composite (SDR™ Dentsply) using HPLC. Adv Med Sci 2015;60(2):191–198. DOI: 10.1016/j.advms.2015.02.003
15. Bouillaguet S, Virgillito M, Wataha J, et al. The influence of dentine permeability on cytotoxicity of four dentine bonding systems, *in vitro*. J Oral Rehabil 1998;25(1):45–51. DOI: 10.1046/j.1365-2842.1998.00205.x
16. Sreevarun M, Ajay R, Suganya G, et al. Formulation, configuration, and physical properties of dental composite resin containing a novel 2π + 2π photodimerized crosslinker—cinnamyl methacrylate: an *in vitro* research. J Contemp Dent Pract 2023;24(6):364–371. DOI: 10.5005/jp-journals-10024-3480
17. Aydınoğlu A, Yoruç ABH. Effects of silane-modified fillers on properties of dental composite resin. Mater Sci Eng C Mater Biol Appl 2017;79:382–389. DOI: 10.1016/j.msec.2017.04.151
18. Feiz A, Zavareh FA, Razavi SM, et al. Reaction of rat subcutaneous connective tissue to resin composites polymerized with different light curing units and different lightening methods. Int J Dent 2012;2012:156352. DOI: 10.1155/2012/156352
19. Ajay R, Suma K, Arulkumar S, et al. Histocompatibility of novel cycloaliphatic comonomer in heat-cured denture base acrylic resin: histomorphometric analysis in rats. J Pharm Bioallied Sci 2020;12(Suppl 1):S453–S461. DOI: 10.4103/jpbs.JPBS_139_20
20. Sivakumar JS, Ajay R, Gokulapriyan K, et al. Histocompatibility of dental restorative composite resin photocured with a novel multifunctional comonomer: a histopathological analysis in rats. J Pharm Bioallied Sci 2021;13(Suppl 2):S1124–S1130. DOI: 10.4103/jpbs.jpbs_203_21
21. American National Standards Institute/American Dental Association Document no. 41 for recommended standard practices for biological evaluation of dental materials. Council on dental materials and devices. J Am Dent Assoc 1979;99(4):697–698.
22. Al-Hiyasat AS, Darmani H. *In vivo* effects of BISGMA-a component of dental composite-on male mouse reproduction and fertility. J Biomed Mater Res A 2006;78(1):66–72. DOI: 10.1002/jbm.a.30667
23. Bodrumlu E. Biocompatibility of retrograde root filling materials: a review. Aust Endod J 2008;34(1):30–35. DOI: 10.1111/j.1747-4477.2007.00085.x
24. St John KR. Biocompatibility of dental materials. Dent Clin North Am 2007;51(3):747–760. DOI: 10.1016/j.cden.2007.03.003
25. Tkáčiková S, Sabo J. Release of monomers from dental composite materials into saliva and the possibility of reducing the toxic risk for the patient. Medicina (Kaunas) 2023;59(7):1204. DOI: 10.3390/medicina59071204
26. Becher R, Kopperud HM, Al RH, et al. Pattern of cell death after *in vitro* exposure to GDMA, TEGDMA, HEMA and two compomer extracts. Dent Mater 2006;22(7):630–640. DOI: 10.1016/j.dental.2005.05.013
27. Geurtsen W, Leyhausen G. Chemical-biological interactions of the resin monomer triethyleneglycol-dimethacrylate (TEGDMA). J Dent Res 2001;80(12):2046–2050. DOI: 10.1177/00220345010800120401
28. Alizadehgharib S, Östberg AK, Rudin AD, et al. The effects of the dental methacrylates TEGDMA, Bis-GMA, and UDMA on neutrophils *in vitro*. Clin Exp Dent Res 2020;6(4):439–447. DOI: 10.1002/cre2.296
29. Reichl FX, Esters M, Simon S, et al. Cell death effects of resin-based dental material compounds and mercurials in human gingival fibroblasts. Arch Toxicol 2006;80(6):370–377. DOI: 10.1007/s00204-005-0044-2
30. Manojlovic D, Dramićanin MD, Miletic V, et al. Cytotoxicity and genotoxicity of a low-shrinkage monomer and monoacylphosphine oxide photoinitiator: comparative analyses of individual toxicity and combination effects in mixtures. Dent Mater 2017;33(4):454–466. DOI: 10.1016/j.dental.2017.02.002
31. Al-Hiyasat AS, Darmani H, Milhem MM. Cytotoxicity evaluation of dental resin composites and their flowable derivatives. Clin Oral Investig 2005;9(1):21–25. DOI: 10.1007/s00784-004-0293-0
32. Darmani H, Al-Hiyasat AS. The effects of BIS-GMA and TEG-DMA on female mouse fertility. Dent Mater 2006;22(4):353–358. DOI: 10.1016/j.dental.2005.04.029
33. Gupta SK, Saxena P, Pant VA, et al. Release and toxicity of dental resin composite. Toxicol Int 2012;19(3):225–234. DOI: 10.4103/0971-6580.103652
34. Gerzina TM, Hume WR. Diffusion of monomers from bonding resin-resin composite combinations through dentine *in vitro*. J Dent 1996;24:125–128. DOI: 10.1016/0300-5712(95)00036-4
35. Noda M, Wataha JC, Kaga M, et al. Components of dentinal adhesives modulate heat shock protein 72 expression in heat-stressed THP-1 human monocytes at sublethal concentrations. J Dent Res 2002;81:265–269. DOI: 10.1177/154405910208100408
36. Lovász BV, Berta G, Lempel E, et al. TEGDMA (triethylene glycol dimethacrylate) induces both caspase-dependent and caspase-independent apoptotic pathways in pulp cells. Polymers (Basel) 2021;13(5):699. DOI: 10.3390/polym13050699
37. Lovász BV, Lempel E, Szalma J, et al. Influence of TEGDMA monomer on MMP-2, MMP-8, and MMP-9 production and collagenase activity in pulp cells. Clin Oral Investig 2021;25(4):2269–2279. DOI: 10.1007/s00784-020-03545-5
38. Maher WP, Johnson RL, Hess J, et al. Biocompatibility of retrograde filling materials in the ferret canine. Amalgam and IRM. Oral Surg Oral Med Oral Pathol 1992;73(6):738–745. DOI: 10.1016/0030-4220(92)90021-h
39. Marcotte LR, Dowson J, Rowe NH. Apical healing with retrofilling materials amalgam and gutta-percha. J Endod 1975;1(2):63–65. DOI: 10.1016/S0099-2399(75)80082-3
40. Ortengren U, Wellendorf H, Karlsson S, et al. Water sorption and solubility of dental composites and identification of monomers released in an aqueous environment. J Oral Rehabil 2001;28(12):1106–1115. DOI: 10.1046/j.1365-2842.2001.00802.x
41. Hansasuta C, Neiders ME, Aguirre A, et al. Cellular inflammatory responses to direct restorative composite resins. J Prosthet Dent 1993;69(6):611–616. DOI: 10.1016/0022-3913(93)90291-u
42. De Oliveira Mussel RL, De Sá Silva E, Costa AMA, et al. Mast cells in tissue response to dentistry materials: an adhesive resin, a calcium hydroxide and a glass ionomer cement. J Cell Mol Med 2003;7(2):171–178. DOI: 10.1111/j.1582-4934.2003.tb00216.x
43. Anagnostou M, Chatzigianni E, Doucoudakis S, et al. Biocompatibility of resin composites subcutaneously implanted in rats with experimentally induced arthritis. Dent Mater 2009;25(7):863–867. DOI: 10.1016/j.dental.2008.09.012

44. Eley BM. The fate of amalgam implanted in soft tissues—an experimental study. J Dent Res 1979;58(3):1146–1152. DOI: 10.1177/00220345790580031901
45. Wennberg A, Mjör IA, Hensten-Pettersen A. Biological evaluation of dental restorative materials—a comparison of different test methods. J Biomed Mater Res 1983;17(1):23–36. DOI: 10.1002/jbm.820170103
46. Harsanyi BB, Angelopoulos AP, Gourley JM. Subcutaneous tissue response to composite resins in dogs. Oral Surg Oral Med Oral Pathol 1974;37(2):308–319. DOI: 10.1016/0030-4220(74)90429-0
47. Bauer JG, Al-Rubayi A. Tissue response to direct filling materials. J Prosthet Dent 1987;58(5):584–589. DOI: 10.1016/0022-3913(87)90388-x