International Journal of Medical and Dental Case Reports (2017), Article ID 100517, 3 Pages

CASE REPORT

Osteomyelitis with proliferative periostitis of mandible involving deciduous teeth - An unusual case report

Patil Disha[1], P. Poornima[2], Rupali Sharma[3], M. Manoharan[1]

[1]Department of Pedodontics, Vivekanandha Dental College for Women, Elayampalayam, Thiruchengode, Namakkal, Tamil Nadu, India, [2]Department of Pedodontics, College of Dental Sciences, Davangere, Karnataka, India, [3]Consultant Pedodontist, Apollo White Dental, GK1, New Delhi, Tamil Nadu, India

Correspondence
Dr. Patil Disha, Department of Pedodontics, Vivekanandha Dental College for Women, Elayampalayam, Thiruchengode, Namakkal, Tamil Nadu, India. Phone: +91-9600497127. Email: dishapatil26@gmail.com

Received 18 March 2017;
Accepted 15 April 2017

doi: 10.15713/ins.ijmdcr.61

How to cite the article:
Disha P, Poornima P, Sharma R, Manoharan M. Osteomyelitis with proliferative periostitis of mandible involving deciduous teeth - An unusual case report. Int J Med Dent Case Rep 2017;4:1-3.

Abstract

Garre's sclerosing osteomyelitis is a kind of chronic osteomyelitis that is mainly seen in children and adolescents. It was formerly documented only in long bones, particularly tibia. Proliferative osteomyelitis of the jaw was described only in the late 1970s. Since then, this clinical entity is well illustrated in dental literature and is frequently linked with an odontogenic infection, mainly involving permanent teeth. This article describes an atypical manifestation of Garre's osteomyelitis of the mandible in a 7-year-old-girl, which was a result of infection of primary mandibular first molar. Extraction of the primary right first molar and antibiotic treatment resulted in complete healing, clinically and radiologically, after 6 months.

Keywords: Children, Garre's osteomyelitis, primary teeth

Introduction

Garre's sclerosing osteomyelitis is a type of chronic non-suppurative osteomyelitis seen exclusively in children or young adults. Carl Garre in 1893, was the first to describe this entity as "a focal gross thickening of periosteum with peripheral reactive bone formation resulting from infection"[1] and therefore termed as Garre's Osteomyelitis. Several names have been used to denote this condition, such as chronic non-suppurative sclerosing osteomyelitis, more recently as periostitis ossificans and the most commonly used today, although cumbersome but nearly accurate is chronic osteomyelitis with proliferative periostitis.[2] It was formerly documented only in long bones, particularly tibia until 1948, when Berger described a case involving the mandible.[3] Proliferative osteomyelitis of the jaw which is a rather rare pathology was described only in the late 1970s. Later, a few more[4-7] were added and explained in the English literature. Since then, this disease is well illustrated in dental literature and frequently occurs in the mandible secondary to odontogenic infection, mainly involving permanent teeth. However, certain cases following dental decay, pericoronitis or a mild periodontitis, or also of unknown etiology have been reported.[7-9] This case report describes a peculiar case of Garre's osteomyelitis in a 7-year-old child, which was a result of infection in deciduous right first molar.

Case Report

A 7-year-old female child reported to the department of pediatric and preventive dentistry with a chief complaint of the presence of a stony hard mass involving the right side of the mandible. The parents noticed an asymptomatic swelling appear on the right side of lower face approximately before six months. The patient was apparently normal with an insignificant past medical history. Extraorally, gross facial asymmetry was noted with the presence of swelling overlying the right lower border of the mandible, 2.0 × 1.0 cm in size [Figure 1a]. The swelling was bony hard, firm, non-fluctuant, and not tender on palpation. The skin overlying the swelling was normal. Cervical lymph nodes were non-palpable. Intraorally, the swelling was smooth and had caused vestibular obliteration in the area of the primary second molar and first permanent molar. The overlying mucosa was normal with respect to color and texture. The patient had mixed dentition with the right lower first primary molar being cariously involved [Figure 1b]. Occlusal radiograph revealed enlargement of the bone on the lateral side of the body of the mandible extending from the first primary molar to the first permanent molar with a pathognomic feature of "onion skin" appearance [Figure 1c]. A final diagnosis of Garre's osteomyelitis was arrived at, based on the clinical and radiographic findings. The

involved primary right first molar was extracted, and antibiotics were prescribed for 5 days. After recall visit at 6 months, the mandibular first premolar had erupted in place; the occlusal radiograph had shown complete remodeling of bone, and child's face was symmetrical [Figure 2].

Discussion

Chronic infectious stimulation leads to periosteal reaction in the bone, causing subperiosteal new bone formation in case of Garre's osteomyelitis. It usually affects the mandible of young children secondary to dental infection. It does not seem to occur in the maxilla. Osteomyelitis with proliferative periostitis is found in children due to increased blood supply, greater bone regenerative characteristics in children, and stronger immune system. Microorganisms which are most commonly isolated include *Staphylococci pyogenes*, variety of aureus or albus, although various Streptococci and some mixed organisms can be associated.[1] Management includes removal of the source of infection and antibiotic therapy.[2] Garre's osteomyelitis should be differentiated from Ewing's sarcoma, infantile cortical hyperostosis, fibrous dysplasia, osteogenic sarcoma, cherubism, and histiocytosis X.

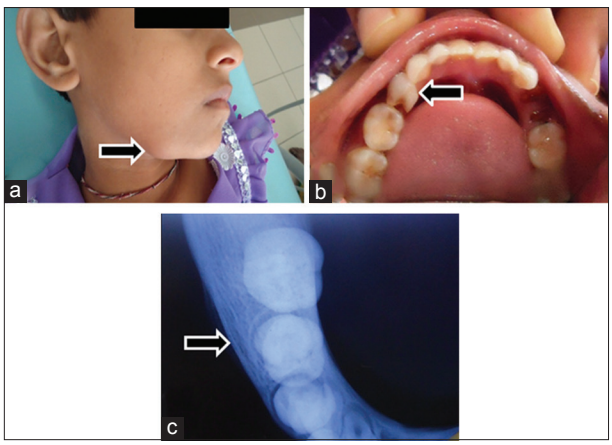

Figure 1: Pre-operative photograph of the patient, (a) 7-year-old female patient with swelling on the right side of the mandible, (b) intraoral photograph showing cariously involved deciduous right first molar, (c) pre-operative occlusal radiograph

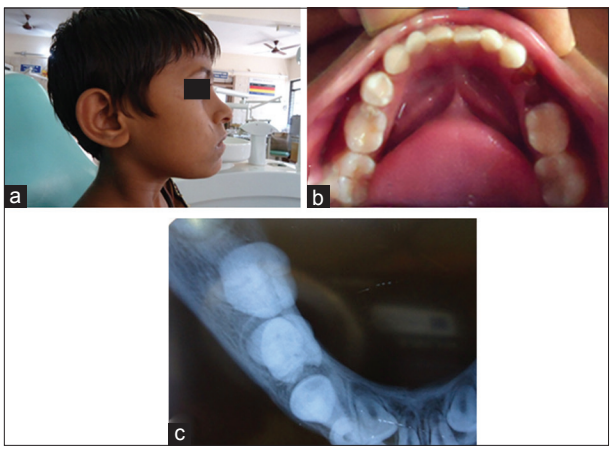

Figure 2: Post-operative photograph of the patient, (a) shows absence of swelling, (b) right first premolar erupted in place, (c) post-operative occlusal radiograph

It is well known that in the presence of infection, the microorganisms are responsible for causing proliferative response in the host, especially if it is chronic infection in young patients. The periosteum of young patients is capable of vigorous osteoblastic activity resulting in balance between the virulence of the microorganisms and the resistance of the host. The extent and duration of the symptoms depend on several critically integrated conditions such as the virulence of the causal organisms, infection, and the immunity of the host.[8] Although this disease entity is a rare manifestation, an increasing prevalence of the same has been noted during the recent years.[9] A review of literature showed most of the cases reported were due to odontogenic infection involving the permanent teeth.[1,6,8,10] This case exhibited the same characteristic features mentioned below as those reviewed in the literature, except that the source of infection was a primary teeth:

1. A long-standing carious lesion or other odontogenic infectious process associated with a bony hard swelling lateral to the inferior border of the mandible producing facial asymmetry, which brought the patient to seek treatment rather than the pain
2. The regression of the lesion with subsequent bone remodeling occurred within the same 6-8 months period as seen in the literature.[1]

Because this case was associated with obvious dental causes and revealed characteristic clinical and radiographic features of Garre's osteomyelitis, it was not considered necessary to perform any bone biopsies. Once identified, treatment procedure involves extraction of the tooth. Since the jaw growth persists, recontouring of the cortical expansion is not required because the jaws are gradually remodeled.

Conclusion

Since Garre's osteomyelitis is commonly seen in younger age group, the patients presenting with any maxillofacial infections, with or without oral symptoms, should be sent to a dentist for an evaluation.

Clinical significance

- This supposedly rare form of bone infection is becoming more and more common
- Disease presents itself mainly in the younger age group, following odontogenic infection
- And also, with a peculiar involvement of mandibular primary molar in our case, we feel, therefore, that pediatric dentists should be aware of the situation.

References

1. Schwartz S, Pham H. Garre's osteomyelitis: A case report. Pediatr Dent 1981;3:283-6.
2. Tong AC, Ng IO, Yeung KM. Osteomyelitis with proliferative periostitis: An unusual case. Oral Surg Oral Med Oral Pathol Oral Radiol Endod 2006;102:e14-9.
3. Berger A. Perimandibular ossification of possible traumatic origin; Report of case. J Oral Surg (Chic) 1948;6:353-6.
4. Smith SN, Farman AG. Osteomyelitis with proliferative periostitis (Garré's osteomyelitis). Report of a case affecting the mandible. Oral Surg Oral Med Oral Pathol 1977;43:315-8.
5. Asada K. Garré's osteomyelitis and chronic sclerosing osteomyelitis of the mandible. Kokubyo Gakkai Zasshi 1978;45:504-5.
6. McWalter GM, Schaberg SJ. Garre's osteomyelitis of the mandible resolved by endodontic treatment. J Am Dent Assoc 1984;108:193-5.
7. Van den Bossche LH, Demeulemeester JD, Bossuyt MH. Periodontal infection leading to periostitis ossificans ("Garrè's osteomyelitis") of the mandible. Report of a case. J Periodontol 1993;64:60-2.
8. Suma R, Vinay C, Shashikanth MC, Subba Reddy VV. Garre's sclerosing osteomyelitis. J Indian Soc Pedod Prev Dent 2007;25 Suppl: S30-3.
9. Gumber P, Sharma A, Sharma K, Gupta S, Bhardwaj B, Jakhar KK. Garre's sclerosing osteomyelitis - A case report. J Adv Med Dent Sci Res 2016;4(2):78-83.
10. Eswar N. Garre's osteomyelitis: A case report. J Indian Soc Pedod Prev Dent 2001;19:157-9.

This work is licensed under a Creative Commons Attribution 4.0 International License. The images or other third party material in this article are included in the article's Creative Commons license, unless indicated otherwise in the credit line; if the material is not included under the Creative Commons license, users will need to obtain permission from the license holder to reproduce the material. To view a copy of this license, visit http://creativecommons.org/licenses/by/4.0/ © Disha P, Poornima P, Sharma R, Manoharan M. 2017