[Downloaded free from http://www.jpbsonline.org on Wednesday, October 07, 2015, IP: 117.230.237.156]

Granularity in granular cell ameloblastoma

Andamuthu Yamunadevi, G. S. Madhushankari[1], Manickam Selvamani[1], Praveen S. Basandi[1], Thukanayyakanpalayam Ragunathan Yoithapprabhunath, N. Ganapathy

Department of Oral and Maxillofacial Pathology, Vivekanandha Dental College for Women, Tiruchengode, Namakkal, Tamil Nadu, [1]Department of Oral and Maxillofacial Pathology and Microbiology, College of Dental Sciences and Hospital, Davangere, Karnataka, India

Address for correspondence:
Dr. Andamuthu Yamunadevi,
E-mail: yamunaoralpath@gmail.com

Received : 30-03-14
Review completed : 30-03-14
Accepted : 09-04-14

ABSTRACT

Granular cell ameloblastoma (GCA) is one of the rare histological variants of ameloblastoma (1.5-3.5%), identified by Krompechner in 1918 and is diagnosed by the characteristic presence of granular cells. These granular cells are seen in several physiological and pathological conditions and the granularity in GCA is due to lysosomal aggregates. This review is about the clinical features, histopathological features and differential diagnosis of GCA and also adds the theories for occurrence of granularity, electron microscopic findings, cell signaling pathways and immunohistochemistry findings related to these granular cells in GCA.

KEY WORDS: Granular cells, granular cell ameloblastoma, lysosomes

"Ameloblastoma is a true neoplasm of the enamel organ type which does not undergo differentiation to the point of enamel formation."[1] It is the second most common odontogenic tumor, arising from rests of dental lamina or from a developing enamel organ or from the epithelial lining of an odontogenic cyst, or from the basal cells of the oral mucosa.[1] It may be multicystic (86%), unicystic (13%) or peripheral (1%) in occurrence.[2]

Conventional solid or multicystic ameloblastoma exhibits six microscopic subtypes namely follicular, plexiform, acanthomatous, granular cell, desmoplastic and basal cell ameloblastoma.[2] All these types present with tall columnar ameloblast like cells with hyperchromatic palisaded nuclei, oriented away from the basement membrane and subnuclear vacuolization as described by Vickers and Gorlin.[1] Stellate reticulum like cells, cystic degeneration, induction phenomenon exhibiting hyalinization changes are common observations.[1,2]

Granular cell ameloblastoma (GCA) is one of the rare histological variants of ameloblastoma with marked transformation of the cytoplasm of stellate reticulum like cells into a coarse, granular eosinophilic appearance.[1] It appears to be aggressive in nature, with a marked propensity for recurrence and can show metastasis.[1]

Histopathologically, several lesions can show granular cell changes,[3] of which GCA is most commonly encountered in the oral and maxillofacial pathology. This review picturises the clinical and histopathological features, differential diagnosis of GCA, theories for occurrence of granularity, electron microscopic findings, cell signaling pathways and immunohistochemistry (IHC) findings related to these granular cells in GCA.

Access this article online

Quick Response Code:

Website: www.jpbsonline.org

DOI: 10.4103/0975-7406.137253

How to cite this article: Yamunadevi A, Madhushankari GS, Selvamani M, Basandi PS, Yoithapprabhunath TR, Ganapathy N. Granularity in granular cell ameloblastoma. J Pharm Bioall Sci 2014;6:S16-20.

[Downloaded free from http://www.jpbsonline.org on Wednesday, October 07, 2015, IP: 117.230.237.156]

Granular Cell Ameloblastoma

Granular cell change in ameloblastoma is a rare histopathological entity (accounting for 1-5% of ameloblastomas [Reichart *et al*. - 3.5%[4]]), first seen by Krompecher in 1918[5] and was called as pseudoxanthomatous cells.

Clinical and radiological features

- Compared to the other ameloblastoma subtypes, no distinguishing clinical or radiographic findings have been reported[4]
- Jaw swelling and pain are the most frequent presenting symptoms
- Its age distribution is considered to be quite similar to the other types of ameloblastomas, for which an average median age of 35 years old, ranging from 4 to 92 years is reported[4]
- Hartman studied 20 cases of GCA from the files of Armed Forces Institute of Pathology and suggested that the granular-cell ameloblastoma occurs predominantly at the posterior regions of the mandible, with no gender predilection and demonstrates a marked propensity to recur (73%) following conservative therapy.[6] The average age of the patients in this series was 40.7 years (age range 21-65 years), and 40% of the cases occurred in nonCaucasians[6]
- Granular cell ameloblastomas treated by conservative treatment like enucleation or curettage exhibit a high recurrence rate due to the fact that "the border of the tumor within cancellous bone lies beyond the apparent macroscopic surface and the radiographic boundaries of the lesion." Therefore, radical surgical methods and accurate preoperative diagnosis and regular follow-up are recommended[4,6]
- Reichart *et al*. in their study found that the recurrence rate is 33.3%, greater than other common types of ameloblastomas.[4] Shows higher incidence of malignancy[3] and can metastasize to distant sites like lungs[7] and thoracic vertebra.[8] Hence, GCA is considered to be aggressive in clinical behavior
- Few researchers debate that GCA is not recurring at the higher rate with radical surgical treatment, and hence, its biological behavior and prognosis is not different from that of other histological types of solid ameloblastoma. Furthermore, granular cell changes are thought to be due to age changes or degenerative changes rather than indicating aggressiveness
- Its occurrence in cystic ameloblastoma is very rare[9] and such occurrence is known as granular cell odontogenic cyst.[3]

Histopathological features

Granular cell ameloblastoma is characterized by the presence of granular cells, which measures about 1 μm in size[10] (giant granular cells are up to 30 μm and rarely seen).[10] Granular cells occur typically within the central area of ameloblastic tumor follicles, [Figure 1] progressively replacing the stellate reticulum. This may extend to include the peripheral columnar

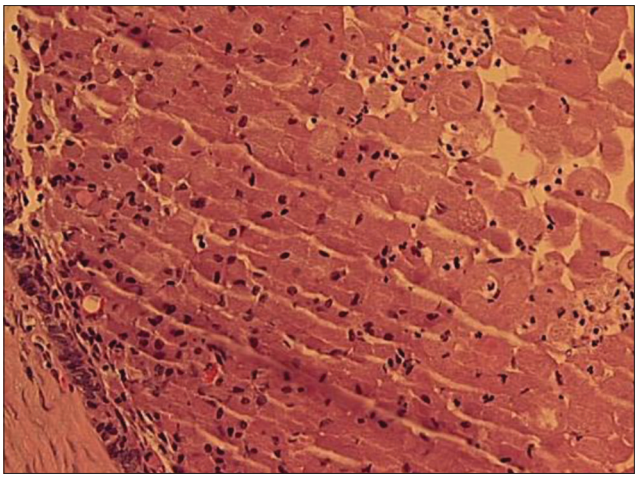

Figure 1: Granular cells in granular cell ameloblastoma

or cuboidal cells as well.[1] Sometimes plexiform type can also exhibit granular cell changes and the granular cells are cuboidal, columnar, or round in shape, with the cytoplasm being filled with acidophilic granules, which have been identified ultrastructurally as lysosomal aggregates.[11] The nuclei of these cells are described as pyknotic and hyperchromatic, oriented away from the basement membrane, showing the back-to-back arrangement.[12]

Cystic ameloblastoma exhibiting nodular ball like thickening of granular cells along the lining is also seen (granular cell odontogenic cyst).[9]

Fine-needle aspiration cytology smears can show characteristic granular cells along with spindle and basaloid cells.[13]

Histological differential diagnosis

Histologically, eosinophilic granular cells can appear in various normal and pathogenic conditions as listed in Table 1.

Among these granular cell lesions, GCA, granular cell ameloblastic fibroma, granular cell myoblastoma and congenital epulis shows striking morphological resemblance of the granular cells. Due to this, few authors have initially considered congenital epulis as a granular cell myoblastoma occurring in childhood and GCA as a coincidental mixture of ameloblastoma and granular cell myoblastoma.[11] Histogenetically, the GCA's are of epithelial nature, and arise from ameloblasts and expresses amelogenin, a precursor of enamel.[14] Conversely, the granular cells found in granular cell ameloblastic fibroma, granular cell myoblastoma, and congenital epulis are of mesenchymal derivation.[15] The differentiating features of these four benign granular cell lesions are listed in Table 2.

The occurrence of granular cells in developing enamel organ of 37 weeks old stillborn female infant[16] is reported and Patankar et al have stated that "the presence of granular cells in an ameloblastoma might be of some prognostic significance in terms of initial treatment performed"[17].

[Downloaded free from http://www.jpbsonline.org on Wednesday, October 07, 2015, IP: 117.230.237.156]

Table 1: Large eosinophilic granular cells in normal and pathologic human tissues (modified from Navarrete and Smith[11])

Cells showing cytoplasmic eosinophilic granularity	Reasons for granularity	Special stains
Oxyphils (parathyroid) Oncocytes (salivary glands) Hurthle or Askanszy cells (thyroid)	Mitochondria	PAS-negative PTAH-positive
Granular cells in Granular cell ameloblastoma Granular cell myoblastoma (also known as tumor of Abrikosoff, granular cell tumor, granular cell neurofibroma, or granular cell schwannoma)[3] Granular cell odontogenic fibroma/ granular cell odontogenic tumor Congenital epulis of newborn (also known as CGCL), congenital epulis, Neumann's tumor, or congenital gingival granular cell tumor)[3] Granular cell leiomyoma (very rare)[3] Granular cell basal cell carcinoma[3] Enamel organ of developing teeth[16] Ameloblasts during amelogenesis[16] Odontogenic epithelium[10]	Lysosomes	PAS-positive PTAH-negative
Calcifying epithelial odontogenic tumor	Polyribosomes	PAS-negative (few are PAS positive, but disappears on diastase action)

Granular cell changes[3] are also seen in perivascular epitheloid cell tumors, alveolar soft part sarcoma, paraganglioma, dermatofibroma, rhabdomyoma, at traumatic sites as reactive change, renal cell carcinoma, cutaneous granular cell angiosarcoma, melanocytic lesions, histiocytic lesions and metastatic lesions and show positivity for concerned tissue of origin during IHC and special stains.
IHC: Immunohistochemistry, CGCL: Congenital granular cell lesion, PAS: Periodic acid Schiff, PTAH: Phosphotungstic acid hematoxylin

Special stains for granular cells in granular cell ameloblastoma

All granular cells, including the peripheral lining cells in GCA show periodic acid Schiff (PAS)-positive and PAS with diastase positive cytoplasmic granules. The ameloblasts present in plexiform type reveal occasional PAS-positive cytoplasmic granules as compared to those lining the islands of granular cells.[11] The other staining reactivity of the granular cells is enlisted in Table 3.

Reasons for granularity in granular cell ameloblastoma

Ultrastructurally, it has been revealed that it is the lysosomal overload in the granular cells of GCA that imparts the characteristic granularity.[18] The speculators hypothesize that the granular cell change in ameloblastoma can be "a degenerative process in a long standing lesion or a dysfunctional status of neoplastic cells or a metabolic change in response to aging phenomenon[19] or an indicator of a more aggressive course." The reasons for these varying concepts are discussed below

1. During the secretory and postsecretory stages (absorptive stage and while changing from reduced ameloblasts to squamous epithelium) of amelogenesis, ameloblasts normally show an increase in autophagic lysosomes.[20] Similarly, the odontogenic epithelium of ameloblastoma seems to undergo granular changes under certain conditions like lysosomal insufficiency or overproduction of unused materials in odontogenic epithelial cells[12]
2. Aging theory: During early days, Tsukada[8], Navarrette and Smith,[11] observed granular change in ameloblastoma more than two decades after the initial tumor. Hartman[6] in 1975 observed that the average age of the patients in his

Table 2: Differential diagnosis for GCA[2]

Lesion	Histopathological feature	Differentiating feature from GCA
Granular cell odontogenic fibroma/granular cell odontogenic tumor	Small islands or cords of the odontogenic epithelium may be seen interspersed among the granular cells, while small cementum-like deposits and dystrophic calcifications are often found within the lesion Treatment-enucleation and vigorous curettage Recurrence-rare/nil Prognosis-very good	In contrast to granular cell ameloblastoma, the granular cells of granular cell odontogenic tumor are not located within epithelial islands but constitute part of the tumor stromas No cementum like particles or calcifications in GCA Immunohistochemically positive for vimentin, CD68, muramidase, bcl-2 and negative for cytokeratin and S-100 protein[15]
Granular cell myoblastoma/ granular cell schwannoma/ granular cell tumor	Histopathology reveals large polygonal cells with abundant, pale, eosinophilic granular cytoplasm, with a small vesicular nucleus, arranged into sheets, cords or nests Cell borders are often indistinct, resulting in syncytial appearance The occasional presence of pseudoepitheliomatous hyperplasia of the overlying epithelium, which can result in misdiagnosis of squamous cell carcinoma, is noteworthy	Differential diagnosis from a GCA is necessary when there is peripheral localization or cortical perforation and soft tissue extension of the ameloblastoma Positive for vimentin and S-100 protein, which could indicate neural origin[15]
Congenital epulis/congenital granular cell lesion/ congenital epulis of new born	Granular cells appear as large rounded cells with abundant, granular, eosinophilic cytoplasm and round to oval, lightly basophilic nuclei. In older tumors, they become elongated Atrophy of rete ridges with no pseudoepitheliomatous hyperplasia	No need to distinguish as it occurs in newborn whereas GCA occurs in adults Immunohistochemical investigation is negative for S-100 protein[15]

Granular cells in GCA[15]-are positive for cytokeratin (membranous positivity), CD68 (cytoplasmic positivity), lysozyme and alpha-1-antichymotrypsin, but negative for vimentin, desmin, S-100 protein, neuron-specific enolase and CD15, indicating epithelial origin, but the granular cells in the other three lesions are mesenchymal in origin.[15] GCA: Granular cell ameloblastoma

[Downloaded free from http://www.jpbsonline.org on Wednesday, October 07, 2015, IP: 117.230.237.156]

Table 3: Reactivity of granular cells in GCA for special stains[12]

Special stain	Specificity	Reactivity[12]
PAS	Glycogen	++
PAS with diastase	No glycogen	++
Hale's dialysed iron	Acid mucopolysaccharide	?
Alcian blue pH 2.5	Mucin (highly acidic)	–
Alcian blue pH 4	Mucin (slightly acidic)	–
Alcian blue pH 5.8	Mucin (neutral; slightly acidic)	–
Mucicarmine[8]	Mucin	–
Oil-red 0	Lipid	+
PTAH	Intracellular filaments	–
Verhoeff's stain[8]	Elastic fibers	–
Gritlley's reticulum[8]	Elastic fibers	–
NASD-chloroacetate esterase	Mast cells-myeloid series	–
Duray's technique	Lysosomal acid phosphatase	+,++
r-naphthylacetate	Substrate of ester hydrolases of carboxylic acids	+
P-glucuronidase	Hydrolysis of glycosyl compounds	+
Alkaline phosphatase	Hydrolysis of glycosyl compounds	–

PAS: Periodic acid schiff, NASD: Naphthol ASD, PTAH: Phosphotungstic acid hematoxylin, GCA: Granular cell ameloblastoma

GCA series was 40.7 years, which was 8 years more than the mean age of the conventional ameloblastomas. Thus, it was speculated that with increasing age, more of unnecessary or aged components are getting deposited in the cytoplasm of the tumor cells; however, the ability of lysosomes to digest or dispose of these materials decreases with age.[17] Thus, the numerous lysosomes might represent the epiphenomenon of an increased cellular activity of the tumor ameloblast in digesting unwanted compounds[12]

Therefore, the granular change is thought to be due to dysfunctional status of lysosomes in the tumor cells and the pathogenesis seems to be age related,[12]but by observing later case reports, Neville *et al.* says aging change cannot be considered, as this variant has been seen in younger patients also[2]

3. On ultrastructural examination, numerous apoptotic cell fragments with condensed nuclei in granular cell clusters are seen. Most of these fragments are phagocytosed by adjacent granular cells. These features suggest that increased apoptotic cell death of neoplastic cells and subsequent phagocytosis by neighboring cells might have caused the cytoplasmic granularity.[15] Identification of apoptotic markers and death signaling pathways in these granular cells support this degenerative mechanism.[15]
4. Electron microscopically, all the granular cells show regular nuclei and no degenerative change is seen. Because of this, the presence of numerous lysosomes is considered to have an active function, rather than representing aging phenomenon or degenerative changes.[18]

Among these concepts, aging phenomenon and degenerative changes are widely accepted.

Electron microscopic study of granular cells

Electron microscopically the cytoplasmic granules are approximately 0.6 μ[18] (0.4-1.4 μ[11]) in diameter, and will be surrounded by limiting membrane. Most of these granules reveal high electron density and are osmiophilic, exhibiting various patterns (pleomorphic) and are identified as lysosomes.[18] The various patterns observed are

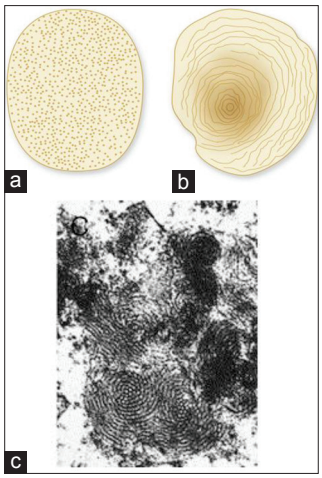

Figure 2: (a-c) Varying patterns of lysosomes[21]

1. Homogenous - some granules, usually round or oval, composed of homogenous amorphous osmiophilic material of different density[11]
2. Myelin figures - those containing concentrically laminated membranes[11] [Figure 2b]
3. Fingerprint pattern - lysosomes containing fine parallel membranes that run in different directions[11] [Figure 2c]
4. Few are packed mainly with tiny vesicles[11] [Figure 2a].

Many granules contain different patterns and appear to be transitional forms. In lysosomal storage disorders, similar kind of varying morphologies are observed and each of these shapes seems to represent various phases of disease progression.[21] Vesicular appearance is seen in the earlier course of disease and the other patterns appear in later stages of disease due to autophagy and secondary disruption of lipid metabolism.[21]

Apart from these granules, the cytoplasm of these granular cells contain round or oval mitochondria, well-developed golgi complexes, scanty rough-surfaced endoplasmic reticulum, and pleomorphic vacuoles limited by a single membrane.[11]

Cell signaling pathways in granular cell ameloblastoma causing lysosomal aggregation

At the molecular level, lysosomal aggregation within the cytoplasm is caused by dysfunction of either a lysosomal enzyme or a lysosome-associated protein, which is related to enzyme activation, enzyme targeting, or lysosomal biogenesis.[21]

Sathi *et al.*[22] focused on the role of bone morphogenic proteins (BMPs) and the Wnt signaling pathway molecules (important cell signaling molecules responsible for cell proliferation, cytodifferentiation and secretion) in GCAs by IHC studies. Strong expression of the β-catenin and Wnt-5a and weak expression of BMP-4 and no expression of Wnt-2 were noted within the granular cells.[22]

[Downloaded free from http://www.jpbsonline.org on Wednesday, October 07, 2015, IP: 117.230.237.156]

They speculate that the synthesis and secretion processes for the cell signaling molecules within the granular cells may be altered in two ways. First, these cells may be able to synthesize signaling molecules such as β-catenin and Wnt-5a, but their transportation or secretion process is impaired. As a result, the molecules accumulate within the cytoplasm as autophagosomes.[22]

Second, both synthesis and secretion processes are arrested for BMP-4 and Wnt-2, and these molecules are thus not accumulated within the granular cells in ameloblastoma.[22]

These cell signaling pathways have co-localization with heparin sulfate (HS) and hence secretion and function of HS is also affected in granular cells.[22]

Immunohistochemical expression of molecular markers in GCA

Apoptotic markers-GCA shows positivity for apoptosis related molecules (BH3 - only proteins), whereas other types of ameloblastoma do not show.[23]

Furthermore, regarding apoptosis related proteins, strong expression of Fas antigen, weakly positive reaction for FasL, Caspase-3, and no expression of Bcl-2 are noted.[24]

Mitochondria-mediated apoptotic markers like apoptotic protease-activating factor-1, caspase-9 and apoptosis-inducing factor show less/no reactivity on IHC study in the granular cells.[25]

Angiogenic factors-GCAs show platelet derived endothelial cell growth factor/thymidine phosphorylase reactivity in granular neoplastic cells as well as in stromal cells.[26]

To find the role of signaling pathways such as Notch, sonic hedgehog and PI3K/Akt/mTOR, in the pathogenesis of ameloblastoma, IHC study has been done and the expression of Notch1, Notch2, Notch3, Denta1 and Jagged1 is identified in all ameloblastomas including GCA, but not in granular cells. These molecules are thought to play an important role in epithelial-mesenchymal interactions and cell proliferations during the growth of ameloblastoma.[27]

Conclusion

Granular cells in GCA are lysosomal aggregates formed due to dysfunction of lysosomal enzyme or related protein. They are PAS - positive and PTAH negative, thereby getting differentiated from other eosinophilic granular cells like oncocytes. They are of epithelial origin and are thought to be formed due to aging phenomenon or degenerative changes. IHC studies are helping us to identify the molecular pathogenesis behind the granular cell formation in GCA, so that more appropriate treatment plan can be utilized.

References

1. Shafer WG, Hine MK, Levy BM. Shafer's Textbook of Oral Pathology. 5th ed. Amsterdam: Elsevier Health Sciences; 2006.
2. Neville BW, Damm DD, Allen CM, Bouquot JE. Odontogenic cysts and tumours. In: Neville BW, Damm DD, Allen CM, Bouquot JE, editors. Oral and Maxillofacial Pathology. 3rd ed. St. Louis: Saunders; 2009.
3. Yogesh TL, Sowmya SV. Granules in granular cell lesions of the head and neck: A review. ISNR Pathol 2011;1-10. [Article ID 215251].
4. Reichart PA, Philipsen HP, Sonner S. Ameloblastoma: Biological profile of 3677 cases. Eur J Cancer B Oral Oncol 1995;31B: 86-99.
5. Krompecher E. The histogenesis and morphology of adamantinomas and other jaw tumors. Beitr Pathol Anat 1918;64:165-97.
6. Hartman KS. Granular-cell ameloblastoma. Oral Surg Oral Med Oral Pathol 1974;38:241-53.
7. Tsukada Y, Delapava S, Pickren JW. Granular-cell ameloblastoma with metastasis to the lungs: Report of a case and review of the literature. Cancer 1965;18:916-25.
8. Takahashi K, Kitajima T, Lee M, Iwasaki N, Inoue S, Matsui N, *et al*. Granular cell ameloblastoma of the mandible with metastasis to the third thoracic vertebra. A case report. Clin Orthop Relat Res 1985;197:171-80.
9. Thillaikarasi R, Balaji J, Gupta B, Ilayarja V, Vani NV, Vidula B, *et al*. Cystic granular cell ameloblastoma. J Maxillofac Oral Surg 2010;9:310-3.
10. Nasu M, Takagi M, Yamamoto H. Ultrastructural and histochemical studies of granular-cell ameloblastoma. J Oral Pathol 1984;13:448-56.
11. Navarrette AR, Smith M. Ultrastructure of granular cell ameloblastoma. Cancer 1971;27:948-55.
12. Lo Muzio L, Mignogna MD, Staibano S, De Rosa G. Granular cell ameloblastoma: A case report with histochemical findings. Eur J Cancer B Oral Oncol 1996;32B: 210-2.
13. Deshpande A, Umap P, Munshi M. Granular cell ameloblastoma of the jaw. A report of two cases with fine needle aspiration cytology. J Oral Maxillofac Pathol 2012;16:122-4.
14. Kumamoto H, Yoshida M, Ooya K. Immunohistochemical detection of amelogenin and cytokeratin 19 in epithelial odontogenic tumors. Oral Dis 2001;7:171-6.
15. Kumamoto H, Ooya K. Immunohistochemical and ultrastructural investigation of apoptotic cell death in granular cell ameloblastoma. J Oral Pathol Med 2001;30:245-50.
16. Sunderland EP, Sunderland R, Smith CJ. Granular cells associated with the enamel organ of a developing tooth. J Oral Pathol 1983;12:1-6.
17. Patankar SR, Mehtha A. Granular cell ameloblastoma: A case report. Int J Oral Maxillofac Pathol 2011;2:63-7.
18. Noda M, Suzuki A. Ultrastructural study of granular cell ameloblastoma. Pathol Int 1980;30:145-56.
19. Saigal S, Bhargava M, Chalishazar M. Granular cell ameloblastoma – A case report. Oral Maxillofac Pathol J 2011;2:ISSN 0976-1225.
20. Reith EJ. The stages of amelogenesis as observed in molar teeth of young rats. J Ultrastruct Res 1970;30:111-51.
21. Parkinson-Lawrence EJ, Shandala T, Prodoehl M, Plew R, Borlace GN, Brooks DA. Lysosomal storage disease: Revealing lysosomal function and physiology. Physiology (Bethesda) 2010;25:102-15.
22. Sathi GS, Han PP, Tamamura R, Nagatsuka H, Hu H, Katase N, *et al*. Immunolocalization of cell signaling molecules in the granular cell ameloblastoma. J Oral Pathol Med 2007;36:609-14.
23. Kumamoto H, Ooya K. Immunohistochemical detection of BH3-only proteins in ameloblastic tumors. Oral Dis 2008;14:550-5.
24. Luo HY, Yu SF, Li TJ. Differential expression of apoptosis-related proteins in various cellular components of ameloblastomas. Int J Oral Maxillofac Surg 2006;35:750-5.
25. Kumamoto H, Ooya K. Detection of mitochondria-mediated apoptosis signaling molecules in ameloblastomas. J Oral Pathol Med 2005;34:565-72.
26. Kumamoto H, Ooya K. Immunohistochemical detection of platelet-derived endothelial cell growth factor/thymidine phosphorylase and angiopoietins in ameloblastic tumors. J Oral Pathol Med 2006;35:606-12.
27. Kumamoto H, Ohki K. Detection of Notch signaling molecules in ameloblastomas. J Oral Pathol Med 2008;37:228-34.

Source of Support: Nil, **Conflict of Interest:** None declared.