CASE REPORT

Biodentine as BioRoot Inlay: A Case Report

Gayatrikumary Thiyagarajan[1], M Manoharan[2], Mahesh Mathian Veerabadhran[3], Gawthaman Murugesan[4], Vinodh S[5], Mohanraj Kamatchi[6]

Abstract

Aims and background: The success of endodontic treatment in open apex teeth depends on the establishment of an ideal apical barrier so that apical canal space between the periodontium and the root canal system is filled. Biodentine is a calcium silicate-based cement having several advantages over mineral trioxide aggregate (MTA), glass ionomer cement (GIC), and calcium hydroxide in the treatment of teeth with open apices. Orthograde delivery of biodentine is technique-sensitive and requires multiple radiographs for verification, as well as retrograde placement of biodentine requires surgical intervention. To use the advantages of biodentine and to overcome the disadvantages of placement techniques, an innovative technique was done to obturate the tooth with an open apex using a custom-fit prefabricated BioRoot inlay in this case report.

Case description: In the present case, biodentine has been used as a BioRoot inlay to overcome the disadvantages of various management options of open apex with parallel dentinal walls. BioRoot inlay is an intraradicular custom-made prefabricated restoration which provides the three-dimensional seal of the root canal space and promotes an apical barrier formation in a wide-open apex. This BioRoot inlay, placed passively in the canal, had a good seal laterally and apically along with the Biodentine as sealer forming a monoblock. This sealer helps in sealing milder discrepancies between the plug and the root, providing a three-dimensional seal which had resulted in good healing of periradicular bone.

Conclusion: Biodentine, when used as BioRoot inlay, has been shown to induce faster periapical healing. It provides promising results when used in open apices with parallel walls. It establishes three-dimensional obturation and proper apical seal, which promotes effective root-end induction.

Clinical significance: It can be considered as the effective and definitive alternative for nonsurgical and surgical approaches to treating open apex.

Keywords: Apical closure, Biodentine, BioRoot inlay, Endodontic treatment, Open apex.

International Journal of Clinical Pediatric Dentistry (2023): 10.5005/jp-journals-10005-2580

Background

The apical root portion should be given major concern as it represents the junction of pulp and periodontium. When the phase of tooth eruption begins in the mouth, there are numerous morphological and anatomical changes in the apical foramen with age. The closure of the apical foramen is usually established 3 years after the eruption of the tooth. Any disturbances in the root apex during this growing phase interfere with the formation of the root.[1] Tooth fracture or injury is one of the major important health problems that necessitate a multidisciplinary approach to diagnose and treat the tooth, which has a huge impact on their quality of life. Open apex is also caused due to necrosis of the pulp associated with caries and periapical pathology.[2]

The success of endodontic treatment in open apex teeth depends on the establishment of proper apical closure, which fills up the gap in the root canal between the periodontium and root canal system.[3] Endodontic therapy for nonvital young permanent teeth due to traumatic exposure usually experiences technical difficulties due to presence of necrotic pulp remnants, large open apex, thinner dentin, diverged root morphology, and associated periapical pathology.[3]

To achieve a better prognosis of root canal therapy, proper canal disinfection, three-dimensional biomechanical preparation, and complete obturation of the tooth are needed.[4,5] The ideal necessity is to achieve a "closed apex" by means of custom fitting the filling material,[6] paste fills,[7] or apical surgery.[8] In order to achieve success in open apex root end therapy, care should be taken to ensure the biocompatibility of the product used and to establish a favorable physiological and histological response during its use.[3]

Biodentine is the derivative of calcium silicate cement with physical and chemical properties comparable to derivatives of Portland cement.[9] It shows superior results in treating open apex teeth than other cement-like GIC, calcium hydroxide, and MTA. Biodentine materials are mainly employed in apexification procedures, root perforation repair, and retrograde filling of roots. The physical and biocompatible properties of this cement were improved by modification of its powder composition and the inclusion of softeners and accelerators, and also changes in the mixing pattern. This resulted in more biocompatibility, improved setting reaction, and superior 24-hour push strength when compared with MTA.[9,10]

[1–6]Department of Pedodontics and Preventive Dentistry, Vivekananda Dental College for Women, Tiruchengode, Tamil Nadu, India

Corresponding Author: Gayatrikumary Thiyagarajan, Department of Pedodontics and Preventive Dentistry, Vivekananda Dental College for Women, Tiruchengode, Tamil Nadu, India, Phone: +91 9445564993, e-mail: gayatri28gayu@gmail.com

How to cite this article: Thiyagarajan G, Manoharan M, Veerabadhran MM, *et al.* Biodentine as BioRoot Inlay: A Case Report. Int J Clin Pediatr Dent 2023;16(2):400–404.

Source of support: Nil

Conflict of interest: None

© The Author(s). 2023 Open Access This article is distributed under the terms of the Creative Commons Attribution 4.0 International License (https://creativecommons.org/licenses/by-nc/4.0/), which permits unrestricted use, distribution, and non-commercial reproduction in any medium, provided you give appropriate credit to the original author(s) and the source, provide a link to the Creative Commons license, and indicate if changes were made. The Creative Commons Public Domain Dedication waiver (http://creativecommons.org/publicdomain/zero/1.0/) applies to the data made available in this article, unless otherwise stated.

The orthograde placement of biodentine is usually cumbersome and necessitates several radiographic confirmations. The retrograde delivery of biodentine can be done only by surgical method. In this study, a new technique was used in order to utilize the positive benefits of biodentine and negotiate the disadvantages of the placement procedure by obturating the open apex tooth with the custom-fit prefabricated BioRoot inlay.

Case Description

A patient aged 13 years presented to the Department of Pedodontics and Preventive Dentistry, Vivekananda Dental College for Women, Tiruchengode, Tamil Nadu, India, with the complaint of tooth fracture and discoloration of the upper anterior tooth for about last 5 months (Figs 1 and 2). The patient had a history of trauma 1 year ago. Intraoral examination showed that the left upper central incisor was discolored and traumatic (Fig. 3). The tooth did not respond to heat tests (heated gutta-percha points) and electric pulp testing (pulp tester; analytic Technology, Redmond, Washington, United States of America). Intraoral periapical of 21 regions showed an open apex with mild apical resorption and periapical radiolucency measured about 2 × 1.5 mm in size (Fig. 4). The tooth was isolated with a rubber dam, and the access opening was done under local anesthesia. The working length was measured as 19 mm with a 75-sized file by digital radiography. Around 3% sodium hypochlorite was used for minimal circumferential filing. After proper filing, the canal was dried and placed with intracanal medicament, that is, calcium hydroxide. The patient was recalled after 1 month for review. The tooth did not show any symptoms during the review. The medication was removed and irrigated with sodium hypochlorite and ethylenediaminetetraacetic acid solution. The canal was cleaned and dried. The root canal space was replicated by Elite P&P light body silicone impression material [Zhermack, Badia Polesine (Rovigo), Italy] loaded onto the master file. After the proper setting of the material, the light body impression was removed.

Biodentine™ powder (Septodont, St Maur-des-Fossıs, France) was taken on the hard surface, and five drops of liquid were added to the powder. The powder and liquid were mixed in the trituration for about 30 seconds, and hence the biodentine mixture was obtained. Initially, a small amount of mixture was placed into the mold using a compactor. It was then gently moved towards the apical portion using a root canal plugger. The mixture was added in minor increments to make a single plug of proper thickness to fill the mold. It was left in the mold space for about 15 minutes to achieve the proper setting. Once it was set, the inlay was removed and tried in and was confirmed by digital radiograph (Fig. 5). The finally prepared BioRoot inlay was inserted into the canal and sealed with biodentin sealer and the obturation was finished (Fig. 6). The tooth was finally restored with a metal-ceramic crown (Fig. 7).



Fig. 1: Biodentine



Fig. 3: Intraoral view—pretreatment



Fig. 2: Extraoral view

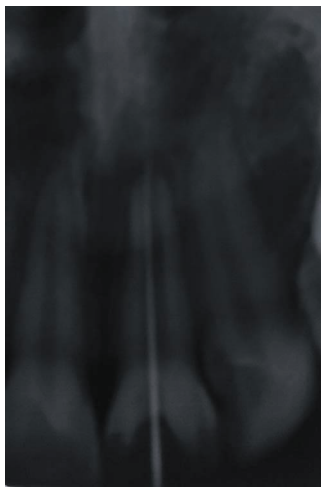

Fig. 4: Radiographic view—pretreatment



Fig. 5: Clinical procedure—steps

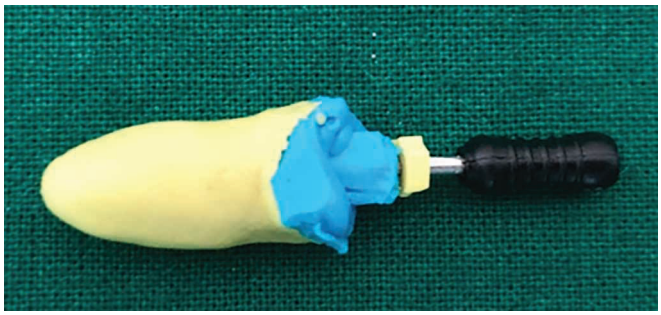

Fig. 6: Immediate postoperative view



Fig. 7: Pre and postoperative extraoral comparison

Resolution of the periapical lesion was observed 6 months after the treatment. The periapical areas revealed satisfactory radiographic evidence of bone healing (Figs 8 to 11).

Discussion

Open apex refers to incomplete closure of the root canal apex due to insufficient root formation, which resulted in a difference in canal morphology so that the apical portion was wider than the cervical portion. It is also called a blunderbuss canal, in which the conical shape of the canal is disturbed.[11] The treatment of open apex is usually technique sensitive and can be done either surgically or nonsurgically. The nonsurgical approach included a basic endodontic root canal procedure, which included apexogenesis



Fig. 8: BioRoot Inlay



Fig. 9: Immediate postoperative view



Fig. 10: Metal ceramic crown in 21

by roll cone technique or apexification with MTA, biodentine, or calcium hydroxide, which was later finished with obturation by gutta-percha and establishment of revascularization. The surgical approach included surgical removal of the apex and retrograde sealing, which was later finished with obturation by gutta-percha and establishment of revascularization. The apicectomy followed by root-end filling had potential benefits such as faster time, complete elimination of periapical pathology, and creation of apical seal BioRoot Inlay also several disadvantages like improper crown root ratio and appearance of crack during retrograde filling.[12]



Fig. 11: 12 months postoperative view

The tooth with an open apex usually poses various technical difficulties, such as incomplete elimination of pulp, incomplete apical seal formation, and improper filing due to delicate dentinal and root canal walls.[13] It often causes fractures of the tooth and failure of root canal therapy. This can be avoided by the proper establishment of the apical barrier by enhancing hard tissue formation at the apex, which is also known as apexification. Apexification can be done with various biocompatible materials, such as MTA, biodentine, bone morphogenetic protein, and calcium hydroxide.[14]

The conventional method for treatment of immature open apex teeth is done by apexification with calcium hydroxide followed by obturation of the canal with gutta-percha. The calcium hydroxide cement has excellent biocompatible and antimicrobial properties, which assist in root-end formation.[15,16] Cvek found that nearly 90% of teeth showed the formation of an apical hard tissue barrier.[17] It also causes ultrastructural modification within the radicular dentin, thereby decreasing the dentin fracture strength. Having good advantages and success rate, it also had various side effects, such as long duration to achieve root end closure, multiple appointments, high compliance of the patient, and chances of coronal microleakage and fracture.[18]

In order to achieve the proper apical seal, an equally biocompatible material called MTA has been introduced. MTA was considered an effective alternative for open apices as it forms an excellent barrier that achieves perfect seal by mild expansion during setting.[19] Before setting, this material exhibited excellent antimicrobial activity. After setting, it exhibited biocompatible and bioactive properties.[20] MTA also assists in the formation of a cementum-like hard barrier when contacting the periapical tissue.[21] The main drawback of this material was the high cost, the necessity of two visits, and technique sensitivity based on its setting and handling.

Biodentine is a recently developed bioactive agent with mechanical and biocompatible properties similar to dentin. It can be used as a dentin substitute in crown during pulp protection, pulpotomy, and pulp capping. It can also be used as a dentin substitute in root during the repair of perforation, external and internal resorption, and apexification.[22] This calcium silicate-derived cement has a powder composition of tricalcium silicate, calcium carbonate, and zirconium dioxide. The liquid composition included a calcium chloride solution with water reducing agent. Biodentine has the potential benefits of shorter setting time, better mechanical properties, and improved handling features.[23] It also eliminated the possibility of wall fracture due to its early placement as soon as the canal was prepared.[23]

In our present study, a case of immature open apex tooth was taken and a BioRoot inlay prepared with biodentine was employed to study its technical benefits and added advantages when compared with other treatment options. BioRoot inlay is the prefabricated replication of the prepared intraradicular canal, which helps in the three-dimensional sealing of the root canal and creates the proper apical barrier in the open apex.[24] The usage of the same biodentine as a sealer helps in sealing minor voids between the inlay and root surface and provides excellent seal apically, as well as laterally, throughout the canal. The formation of a proper seal helps in the healing of periradicular tissues and intraradicularly, it stimulates dentine regeneration.[25] The thickness of the Ca- and Si-rich layers increased over time, and the thickness of the Ca-and Si-rich layer was significantly larger in biodentine when compared to MTA.[26]

Biodentine has high alkaline pH, calcium, and phosphorus ion release resulting in the stimulation of mineralization of hard tissues.[27] The microleakage property of biodentine was superior to other materials and showed the least values.[28] These advantages have been used for the preparation of BioRoot inlay in our study, which provided better clinical results by avoiding voids and unnecessary X-ray exposure.

Conclusion and Clinical Significance

- Biodentine, when used as BioRoot inlay, has been shown to induce faster periapical healing.
- It provides promising results when used in open apices with parallel walls.
- It establishes three-dimensional obturation and proper apical seal, which promotes effective root-end induction.
- Hence, it can be considered as the effective and definitive alternative for nonsurgical and surgical approaches to treating open apex.

Patient Consent Statement

The author(s) have obtained written informed consent from the patient's parents/legal guardians for the publication of the case report details and related images.

References

1. Smyth R, Bob Philpot B. Management of the open apex in endodontics: Scottish Dental magazine. Available from: https://www.sdmag.co.uk/2017/0
2. Das T, Gupta S, Atom J, et al. Endodontic management of blunderbuss canal with open apex and ellis class IV fracture using mineral trioxide aggregate and compo-post. Int J Prev Clin Dent Res 2019;6(3):66. DOI: 10.4103/INPC.INPC_52_19
3. Karim FAA, Mahmud KH, Sultana A, et al. Management of non-vital anterior tooth with open apex by MTA apical plug–a case report. UpDCJ 2019;9(1):42–45. DOI: 10.3329/updcj.v9i1.41206
4. Khetarpal A, Chaudhary S, Talwar S, et al. Endodontic management of open apex using Biodentine as a novel apical matrix. Indian J Dent Res 2014;25(4):513–516. DOI: 10.4103/0970-9290.142555
5. Dali M, Rajbanshi L. Regenerative endodontics: changes, chances, and challenges of revascularization in pediatric dentistry. SRM J Res Dent Sci 2014;5(3):186–189. DOI: 10.4103/0976-433X.138743
6. Friend LA. The root treatment of teeth with open apices. Proc R Soc Med 1966;59(10):1035–1036.
7. Friend LA. The treatment of immature teeth with non–vital pulps. J Br Endod Soc 1967;1:28–33.

8. Ingle JI. Endodontics. Philadelphia: Lea & Febiger;1965.
9. Wang X, Sun H, Chang J. Characterization of Ca3SiO5/CaCl2 composite cement for dental application. Dent Mater 2008;24(1):74–82. DOI: 10.1016/j.dental.2007.02.006
10. Wongkornchaowalit N, Lertchirakarn V. Setting time and flowability of accelerated Portland cement mixed with polycarboxylate superplasticizer. J Endod 2011;37(3):387–389. DOI: 10.1016/j.joen.2010.11.039
11. Andreason JO, Andreason FM. Essentials of traumatic injuries to the teeth 2nd ed. Copenhagen: Munksgaard, 2000. p. 188
12. Grech L, Mallia B, Camilleri J. Characterization of set intermediate restorative material, Biodentine, bioaggregate and a prototype calcium silicate cement for use as root-end filling materials. Int Endod J 2013;46(7):632–641. DOI: 10.1111/iej.12039
13. Kvinnsland SR, Bårdsen A, Fristad I. Apexogenesis after initial root canal treatment of an immature maxillary incisor—a case report. Int Endod J 2010;43(1);76–83. DOI: 10.1111/j.1365-2591.2009.01645.x
14. Cvek M. Prognosis of luxated non-vital maxillary incisors treated with calcium hydroxide and filled with gutta-percha. A retrospective clinical study. Endod Dent Traumatol 1992;8(2):45–55. DOI: 10.1111/j.1600-9657.1992.tb00228.x
15. Sjögren U, Figdor D, Sundqvist G, et al. The antimicrobial effect of calcium hydroxide as a short-term intracanal dressing. Int Endod J 1991;24(3):119–25. DOI: 10.1111/j.1365-2591.1991.tb00117.x
16. Heithersay GS. Stimulation of root formation in incompletely developed pulpless teeth. Oral Surg Oral Med Oral Pathol 1970;29(4):620–630. DOI: 10.1016/0030-4220(70)90474-3
17. Cvek M. Treatment of non-vital permanent incisors with calcium hydroxide. I. Follow-up of periapical repair and apical closure of immature roots. Odontol Revy 1972;23(1):27–44.
18. Ray HA, Trope M. Periapical status of endodontically treated teeth in relation to the technical quality of the root filling and the coronal restoration. Int Endod J 1995;28(1):12–8. DOI: 10.1111/j.1365-2591.1995.tb00150.x
19. Jefferies SR. Bioactive and biomimetic restorative materials: a comprehensive review. Part I. J Esthet Restor Dent 2014;26(1):14–24. DOI: 10.1111/jerd.12069
20. Parirokh M, Torabinejad M. Mineral trioxide aggregate: a comprehensive literature reviewPart I: chemical, physical, and antibacterial properties–. J Endod 2010;36(1):16–27. DOI: 10.1016/j.joen.2009.09.006
21. Apaydin ES, Shabahang S, Torabinejad M. Hard-tissue healing after application of fresh or set MTA as root-end-filling material. J Endod 2004;30(1):21–4. DOI: 10.1097/00004770-200401000-00004
22. Biodentine: A dentin substitute for the repair of root perforations, apexification and retrograde root filling. Dr Francois Bronnec. Endod. 2010;36:400–413.
23. Journee Scientifique du CNEOC Lyon -June 2010.PUBLICATIONS AND COMMUNICATIONS ON BIODENTINE – SEPTODONT
24. Rosaline H, Rajan M, Deivanayagam K, et al. BioRoot inlay: an innovative technique in teeth with wide open apex. Indian J Dent Res 2018;29(4):521–524. DOI: 10.4103/ijdr.IJDR_559_16
25. About I, Laurent P, Tecles O. Bioactivity of Biodentine™ a CA3SiO5-based dentine substitute. Conference: IADR General Session 2010 2010;
26. Han L, Okiji T. Uptake of calcium and silicon released from calcium silicate-based endodontic materials into root canal dentine. Int Endod J 2011;44(12):1081–1087. DOI: 10.1111/j.1365-2591.2011.01924.x
27. Sulthan IR, Ramchandran A, Deepalakshmi A, et al. Evaluation of pH and calcium ion release of mineral trioxide aggregateand a new root-end filling material.E J Dent 2012;2:166-9
28. Kokate SR, Pawar AM. An in vitro comparative stereomicroscopic evaluation of marginal seal between MTA, glass inomer cement and Biodentine as root end filling materials using 1% methylene blue as tracer. Endodontology 2012;2(2):36–42. DOI: 10.4103/0970-7212.352091