Case Report

A Fixed Partial Appliance Approach towards Treatment of Anterior Single Tooth Crossbite: Report of Two Cases

M. Gawthaman, Patil Disha, V. Mahesh Mathian, Vinodh S

Department of Pedodontics, Vivekanandha Dental College for Women, Namakkal, Tamil Nadu, India

Abstract

Crossbite can be treated using both removable and fixed appliances. This paper describes the report of two cases by a method of treating anterior single tooth in crossbite which is locked out of arch form with a simple fixed partial appliance. Orthodontic treatment was initiated by creating space for the locked out incisor using open coil spring and further corrected using MBT brackets and nitinol archwire for alignment. Treatment goals were achieved, and esthetics and occlusion were maintained postoperatively. Treatment objectives were obtained within a short duration using this technique, and there was an improvement in patients' smile.

Keywords: Anterior crossbite, fixed partial appliance, NiTi wire, open coil spring

Introduction

The term anterior crossbite is used to describe a malocclusion in which one or more of the maxillary incisors occlude palatally to the mandibular incisors.[1] Crossbite can be of dental or skeletal in origin. Early correction of crossbite has always been given a greater importance and is recommended because of the fact that it will prevent further complications in malocclusion and also if left untreated would require further comprehensive treatment.[2,3]

Lee[4] summarized four factors to deem before selecting a treatment option:

- Sufficient space in the arch to reposition the tooth
- Enough overbite to hold the tooth in position after correction
- Apical position of the tooth in crossbite is the same as it would be in normal occlusion
- A Class I occlusion.

The following treatment methods have been suggested for correction of simple anterior dental crossbite:

Tongue blade therapy, lower inclined plane, stainless steel or composite crowns, Hawley retainer with auxiliary springs, labial and lingual archwires.[5]

This report presents a method of treating anterior single tooth crossbite with a simple fixed partial appliance.

Access this article online

Quick Response Code:

Website: www.ijds.in

DOI: 10.4103/IJDS.IJDS_19_17

Case Reports

Case 1

A 12-year-old female patient reported to the Department of Pedodontics and Preventive Dentistry, Tamil Nadu, with a chief complaint of irregularly placed upper front teeth since 2 years and also she was esthetically concerned, therefore wanted treatment for the same. The patient had no significant medical or dental history. No abnormality was detected on extraoral examination. Intraoral examination revealed mild dental fluorosis, Angle's Class I molar relation with permanent maxillary right central incisor in crossbite [Figure 1].

Space analysis showed that the maxillary arch had 2 mm arch length discrepancy. Thus, the best treatment option was to create 2 mm space for the maxillary right central incisor and correct the misalignment. Treatment was started in the maxillary arch by bonding MBT (preadjusted edgewise) brackets to the maxillary anterior teeth and molar bands with prewelded buccal tube to the maxillary first molars [Figure 2a]. NiTi open coil springs were then cut in length that was twice

Address for correspondence: Dr. Patil Disha, Department of Pedodontics, Vivekanandha Dental College for Women, Elayampalayam, Tiruchengode - 637 205, Namakkal, Tamil Nadu, India.
E-mail: dishapatil26@gmail.com

This is an open access article distributed under the terms of the Creative Commons Attribution-NonCommercial-ShareAlike 3.0 License, which allows others to remix, tweak, and build upon the work non-commercially, as long as the author is credited and the new creations are licensed under the identical terms.

For reprints contact: reprints@medknow.com

How to cite this article: Gawthaman M, Disha P, Mathian VM, Vinodh S. A fixed partial appliance approach towards treatment of anterior single tooth crossbite: Report of two cases. Indian J Dent Sci 2017;9:119-21.

longer than the distance between maxillary right lateral incisor and left central incisor and incorporated into the wire to regain the lost space [Figure 2b]. After space creation, the maxillary right central incisor was also bonded with MBT bracket, and a 0.016" round nitinol archwire was used for labial movement and alignment of the maxillary right central incisor.

A mandibular posterior removable bite plane appliance was used so as to achieve a 2 mm incisal clearance [Figure 2c]. The patient was asked to wear the appliance full time. Final alignment of the incisor was achieved as shown in Figure 3. No retention was provided as adequate overjet and overbite had been achieved. Brackets were debonded, and bite plane was removed.

Case 2

A 13-year-old female patient reported to the Department of Pedodontics and Preventive Dentistry, with a chief complaint of irregularly placed upper front teeth since 4 years and also she was esthetically concerned, therefore wanted treatment for the same. The patient had no significant medical or dental history. No abnormality was detected on extraoral examination. Intraoral examination revealed Angle's Class I molar relation with permanent maxillary right central incisor in crossbite [Figure 4].

Space analysis showed that the maxillary arch had 2 mm arch length discrepancy. Thus, the best treatment option was to create 2 mm space for the maxillary right central incisor and correct the misalignment. Treatment was started in the maxillary arch by bonding MBT (preadjusted edgewise) brackets to the maxillary anterior teeth and molar bands with prewelded buccal tube to the maxillary first molars. 0.016 NITI archwire was given for initial alignment of teeth. NiTi open coil springs were then cut in length that was twice longer than the distance between maxillary right lateral incisor and left central incisor and incorporated into the wire to regain the lost space [Figure 5a]. A mandibular posterior removable bite plane appliance was used so as to achieve a 2 mm incisal clearance and the patient was instructed to wear the appliance full time [Figure 5b]. After space creation, the maxillary right central incisor was also bonded with MBT bracket, and a 0.016" thermal activate nickel titanium archwire was used for labial movement of the incisor [Figure 5c and d]. Final alignment of the incisor was achieved as shown in Figure 6. No retention was provided as adequate overjet and overbite had been achieved. Brackets were debonded, and bite plane was removed.



Figure 1: Case 1: Preoperative intraoral photograph showing crossbite irt 11. (a) Frontal view, (b) maxillary occlusal view, (c) right lateral view in occlusion, (d) left lateral view in occlusion.

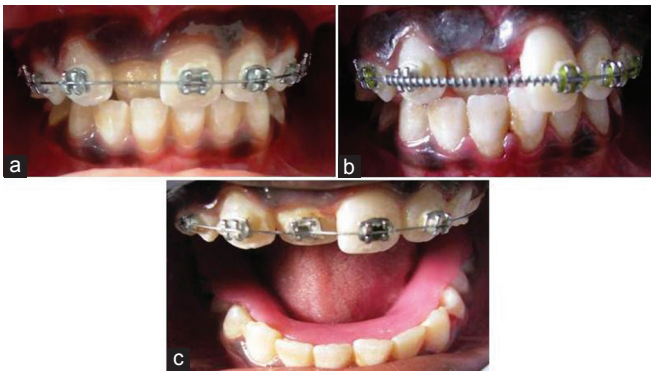

Figure 2: (a) Placement of brackets and wire, (b) creating space for 11 using open coil spring, (c) engaging 11 using NiTi 0.016" wire and lower removable posterior biteplane.



Figure 3: Postoperative intraoral photograph showing correction of crossbite irt 11. (a) Frontal view, (b) maxillary occlusal view, (c) right lateral view in occlusion, (d) left lateral view in occlusion.



Figure 4: Case 2: Preoperative intraoral photograph showing crossbite irt 11. (a) Frontal view, (b) maxillary occlusal view, (c) right lateral view in occlusion, (d) left lateral view in occlusion.

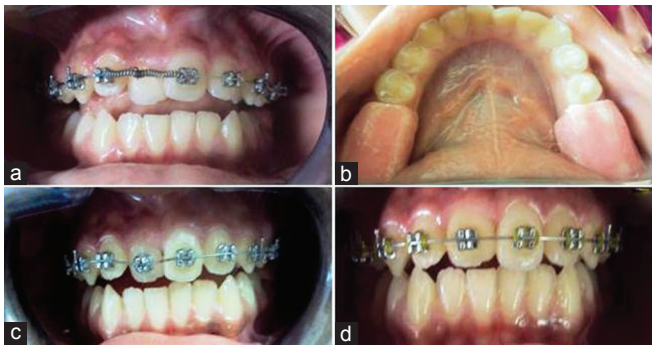

Figure 5: (a) Placement of brackets and wire and creating space for 11 using open coil spring, (b) lower removable posterior biteplane, (c) engaging 11 using NiTi 0.016" wire after space creation, (d) alignment of 11.



Figure 6: Postoperative intraoral photograph showing correction of crossbite irt 11. (a) Post treatment Frontal view (b) maxillary occlusal view, (c) right lateral (d) and left lateral view in occlusion.

Discussion

Anterior crossbite is the term used to define an abnormal labiolingual relationship between one or more maxillary and mandibular incisor teeth. Crossbite of dental origin can be treated using both removable and fixed appliances. However, removable appliances require a high level of patient cooperation and take longer time than fixed appliances to correct incisor crossbite.

The fixed partial appliance in our case made use of preadjusted MBT brackets which have their advantage of being versatile, delivering light continuous forces. Besides, inadequate room for the labial movement of the incisor in crossbite added to the use of open coil spring. NiTi springs display excellent spring back and a long range of superelasticity with a constant load for a large deflection, thereby delivering a more continuous force.[6] Once space is created, brackets will move the blocked out teeth tooth into alignment without arch form distortion. Considering, disocclusion beyond freeway space is necessary for labial movement of an upper central incisor with the help of posterior bite plane. NiTi archwires were used mainly because of their unique properties of superelasticity and shape memory which are chiefly useful to align severely malpositioned teeth.[7]

The appliance used here provides complete control over the arch form and allows three-dimensional control on the teeth involved in crossbite with the help of a continuous archwire. Hence, its more effectual plus offers good tooth positioning and arch alignment. Furthermore, no laboratory cost is concerned, and it requires only chairside time to fix the appliance. Granting patient cooperation is necessary during placement and removal of this appliance, additionally for maintenance. The other disadvantages of removable appliances like they allow only for tipping movements of teeth, cause difficulty in speech, eating, as well incorrect tooth movement caused by improper activation can be overcome with a fixed appliance.[8]

The cases reported here took 4 months for crossbite correction. Given that the teeth was locked out of arch form the use of open coil springs offers us with a quick and comfortable approach compared to disking the teeth or use of expansion screws and other removable appliances. In addition, the use of prefabricated and preadjusted MBT brackets used judiciously along with NiTi wires can serve as an innovative provision in the field of interceptive orthodontics.

Conclusion

The results were acceptable and steady while the treatment objectives were obtained within a short duration using this technique and there was an improvement in patients' smile.

Clinical significance

After having carefully weighed the pros and cons, this treatment option is a simple and effective method to correct anterior crossbite, particularly for teeth locked out of the arch form.

Financial support and sponsorship

Nil.

Conflicts of interest

There are no conflicts of interest.

References

1. Alam MK. Management of single tooth anterior crossbite. Med Today 2009;21:72-3.
2. Estreia F, Almerich J, Gascon F. Interceptive correction of anterior crossbite. J Clin Pediatr Dent 1991;15:157-9.
3. Fatima J, Jain P, Pathak AK, Angrish P. A witty hand of orthodontic treatment – Fixed partial appliance. J Appl Dent Med Sci 2015;1:86-9.
4. Lee BD. Correction of crossbite. Dent Clin North Am 1978;22:647-68.
5. Asher RS, kuster CG, Erickson L. Anterior dental crossbite correction using a simple fixed appliance: Case report. Pediatr Dent 1986;8:53-5.
6. Miura F, Mogi M, Ohura Y, Karibe M. The super-elastic Japanese NiTi alloy wire for use in orthodontics. Part III. Studies on the Japanese NiTi alloy coil springs. Am J Orthod Dentofacial Orthop 1988;94:89-96.
7. Abdelrahman RS, Al-Nimri KS, Al Maaitah EF. A clinical comparison of three aligning archwires in terms of alignment efficiency: A prospective clinical trial. Angle Orthod 2015;85:434-9.
8. Agarwal A, Mathur R. Segmental orthodontics for the correction of cross bites. Int J Clin Pediatr Dent 2011;4:43-7.