[Downloaded free from http://www.jpbsonline.org on Tuesday, May 28, 2019, IP: 223.181.246.18]

Original Article

A Comparative Evaluation of Intracanal Calcium Hydroxide Removal with Hand File, Rotary File, and Passive Ultrasonic Irrigation: An *In Vitro* Study

Sowmiya Tamil, Sivakumar A. Andamuthu, Ravi Vaiyapuri, Prasad A. S., Sampathkumar Sivakumar Jambai, Mathimaraiselvan Chittrarasu

Department of Conservative Dentistry and Endodontics, Vivekanandha Dental College for Women, Tiruchengode, Tamil Nadu, India

Abstract

Aim: The aim of this study was to compare the effectiveness of hand file (K-file), rotary file (HERO shaper), and passive ultrasonic irrigation (PUI; U-file) in removing $Ca(OH)_2$ from the root canal. **Materials and Methods:** Thirty single-rooted teeth were collected and decoronated to standardize the length to 14 mm. Cleaning and shaping were conducted using HERO shaper rotary files (up to no. 25, 4% taper). $Ca(OH)_2$ powder was mixed with normal saline and filled into the canals using lentulo spiral and the orifice was sealed with zinc oxide eugenol. After 7 days of incubation, samples were divided into three groups of 10 samples each: Group I (hand files)—no. 20 K-file; Group II (rotary files)—no. 25, 4% HERO shaper; Group III (PUI)—no. 20 U-file. $Ca(OH)_2$ paste was removed using 2 mL of 3% sodium hypochlorite solution followed by 1-minute activation of the respective file system. All the samples were finally irrigated with 17% ethylenediaminetetraacetic acid and flushed with distilled water. **Results:** Ultrasonic group was more effective in removing $Ca(OH)_2$ followed by HERO shaper and hand file. **Conclusion:** It was concluded that PUI had the highest ability to remove $Ca(OH)_2$ from the root canal walls.

Keywords: *$Ca(OH)_2$, K-file, HERO shaper, PUI*

Introduction

In Endodontics, the use of intracanal dressing is important between treatment sessions for periapical periodontitis.[1] Calcium hydroxide ($Ca(OH)_2$) was first introduced in Endodontics by Herman in 1920. It is alkaline in nature (pH of 12.5), inhibits tooth resorption, and even leads to hard tissue formation.[2] Because of these abilities, $Ca(OH)_2$ has been recommended for use in several clinical situations, the most common indication being an antimicrobial agent in endodontic therapy.[3] $Ca(OH)_2$ medicament should be completely removed from the canal walls before root canal fillings because any residues in the canal walls will negatively affect the quality of root canal filling. Furthermore, remnants of $Ca(OH)_2$ may influence the dentine bond strength by interfering with the sealing abilities of the root canal sealers, resulting in potential reduction of sealer adaptation.[4] The removal of $Ca(OH)_2$ residue from irregular canal walls is difficult. The most common method for removing $Ca(OH)_2$ is the use of "master apical file" (MAF) at working length combined with copious sodium hypochlorite (NaOCl) and ethylenediaminetetraacetic acid (EDTA) solution for irrigating the canals.[5,6] The removal of $Ca(OH)_2$ with hand files using irrigating solutions may be insufficient; hence, the use of rotary NiTi instruments has been advocated.[7] This study was conducted to compare and evaluate the efficacy of $Ca(OH)_2$ removal from the root canals and canal walls using hand files (K-file), rotary files (HERO shaper), and passive ultrasonic irrigation (PUI). Stereomicroscope was used to evaluate the efficacy.

Address for correspondence: Dr. Sowmiya Tamil, Department of Conservative Dentistry and Endodontics, Vivekanandha Dental College for Women, Elaiyampalayam, Tiruchengode 637205, Tamil Nadu, India.
E-mail: sowmiyatamil6@gmail.com

Access this article online

Quick Response Code:

Website: www.jpbsonline.org

DOI: 10.4103/jpbs.JPBS_65_19

This is an open access journal, and articles are distributed under the terms of the Creative Commons Attribution-NonCommercial-ShareAlike 4.0 License, which allows others to remix, tweak, and build upon the work non-commercially, as long as appropriate credit is given and the new creations are licensed under the identical terms.

For reprints contact: reprints@medknow.com

How to cite this article: Tamil S, Andamuthu SA, Vaiyapuri R, Prasad AS, Jambai SS, Chittrarasu M. A comparative evaluation of intracanal calcium hydroxide removal with hand file, rotary file, and passive ultrasonic irrigation: An *in vitro* study. J Pharm Bioall Sci 2019;11:S442-5.

[Downloaded free from http://www.jpbsonline.org on Tuesday, May 28, 2019, IP: 223.181.246.18]

Materials and Methods

Thirty single-rooted teeth, free of any cracks, caries, restorations, resorption, or open apices were selected for this study. The coronal portions of each tooth were sectioned using diamond disks to standardize the root length at 14 mm. K- file of size 10 was used to establish the patency, and cleaning and shaping were done using crown-down technique (HERO shaper no. 25, 4% taper). Using a syringe and a 27-G needle, the canals were irrigated with 2 mL of 3% NaOCl between each filling. The canals were finally rinsed with 3 mL of 17% EDTA and 2 mL of 3% NaOCl. The canals were dried using paper points. The apex was enlarged to taper MAF(HERO shaper no. 25, 4%). $Ca(OH)_2$ powder was mixed with normal saline to form a paste, which was then carried into the canals using lentulo spiral. The orifices were then restored with zinc oxide eugenol (ZOE) cement. Teeth were stored in an incubator for 7 days at 37°C and 100% relative humidity. After this period, samples were randomly assigned into three groups as follows (n = 10).

Group 1: Hand file (no. 20, 2% K-file): The file was placed through the working length and moved up and down for 1 minute using 2 mL of 3% NaOCl. Finally, the root canals were irrigated using 3 mL of 17% EDTA for 3 minutes. Canals were then dried with paper points.

Group 2: Rotary file (HERO shaper): Under constant irrigation using 2 mL of 3% NaOCl, the same file system that was used for cleaning and shaping was placed through the working length and moved up for 1 minute. Finally, the root canals were irrigated using 3 mL of 17% EDTA for 3 minutes and were dried with paper points.

Group 3: PUI (U-file): 2 mL of 3% NaOCl solution was ultrasonically agitated using no. 20 U-file, which was attached to woodpecker ultrasonic irrigation device. Following this, the canal was finally rinsed with 3 mL of a 17% EDTA solution for 3 minutes and was dried with paper points.

Two longitudinal grooves were made in the buccal and lingual aspect of each root, with a diamond disk and then were split into two halves using a chisel. Each section was examined under a stereomicroscope (Lafco, India) at ×20 magnification [Figures 1-3], and photographs were taken with a digital camera (Nikon, Japan). The photographs were evaluated by a single person who was not associated with this study. The marked middle and apical portions were evaluated as per the following scores:

Score 1 = absence of remnants;
Score 2 = scattered remnants; and
Score 3 = densely packed remnants.

Statistical analysis

The collected data were subjected to statistical analysis using one-way analysis of variance test using Statistical Package for the Social Sciences (SPSS, version 19.0) [Table 1].

Results

Minimal amount of $Ca(OH)_2$ was found in Group 3 (average score of 0%) and maximum was found in Group 1 (average score of 70%). This difference between the groups was statistically significant [Table 2, Figure 4].

Group 2 displayed greater amount of residual $Ca(OH)_2$ content as compared to Group 3 but lesser than Group 1. This difference among the groups was also statistically significant.

In the apical third, least amount of residual $Ca(OH)_2$ content was seen in Group 3 (average score of 0%), whereas maximal amount was seen in Group 1 (average score of 70%) [Table 2, Figure 4].

In the middle third, minimal amount of $Ca(OH)_2$ residual content was seen in Group 3 (average score of 0%), whereas maximal amount was seen in Group 1 (average score of 80%) [Table 3, Figure 5].

Discussion

The results of this study showed that neither one of the techniques removed $Ca(OH)_2$ completely. Despite the excellent antimicrobial characteristics, these remnants of $Ca(OH)_2$ can reduce the canal permeability by promoting the formation of calcium carbonate particles

Table 2: Residual calcium hydroxide in apical third

Row labels	Score 1	Score 2	Score 3
Group 1 (K-file)	0%	20%	80%
Group 2 (HERO shaper)	60%	40%	0%
Group 3 (U-file)	80%	20%	0%

Table 1: Statistical analysis using one-way analysis of variance

Source of variation	Sum of squares	df	Mean square	F	*P* value	F critical
Between groups	199	2	99.5	5.427273	0.100761	9.552094
Within groups	55	3	18.333333			
Total	254	5				

[Downloaded free from http://www.jpbsonline.org on Tuesday, May 28, 2019, IP: 223.181.246.18]

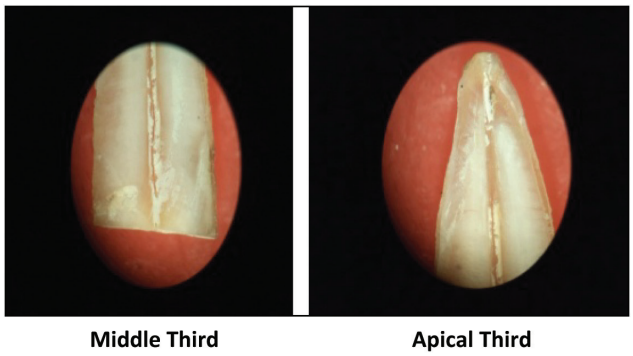

Figure 1: Group 1

Table 3: Residual calcium hydroxide in middle third

Row labels	Score 1	Score 2	Score 3
Group 1 (K-file)	0%	30%	70%
Group 2 (HERO shaper)	0%	60%	40%
Group 3 (U-file)	60%	30%	10%

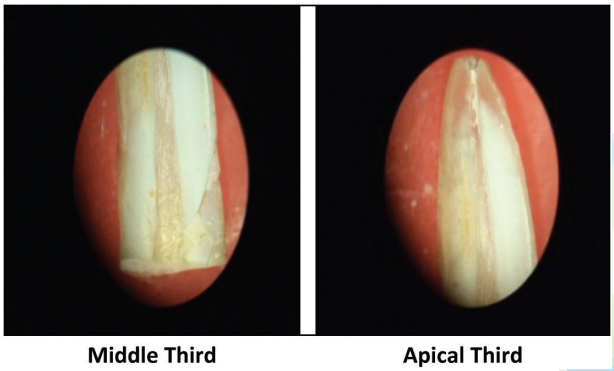

Figure 2: Group 2

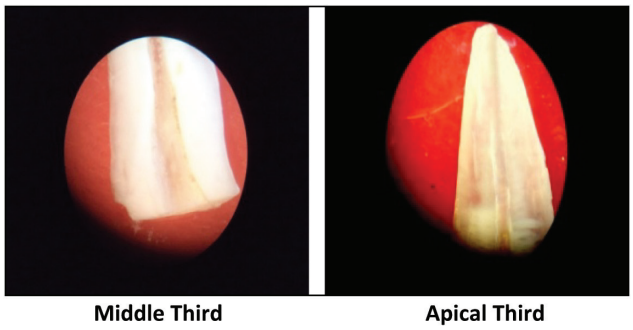

Figure 3: Group 3

and interfering with the sealing ability of endodontic sealers.[4,8] Therefore, different techniques have been proposed to improve $Ca(OH)_2$ removal.[5,9]

In our study, PUI was found to be most effective in $Ca(OH)_2$ removal whereas HERO shaper and K-file were least effective. The latter tends to release higher amount of hydroxyl ions within a short time, whereas the former, although effective for a longer duration,

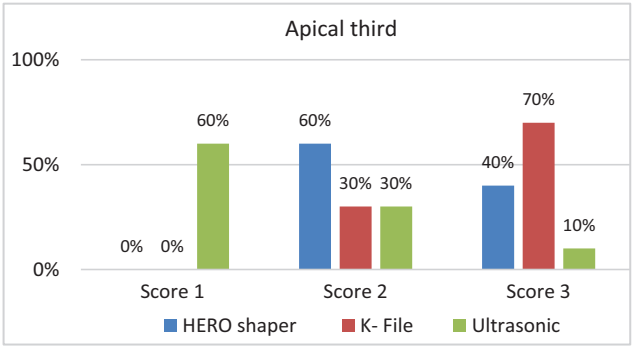

Figure 4: Residual calcium hydroxide in apical third

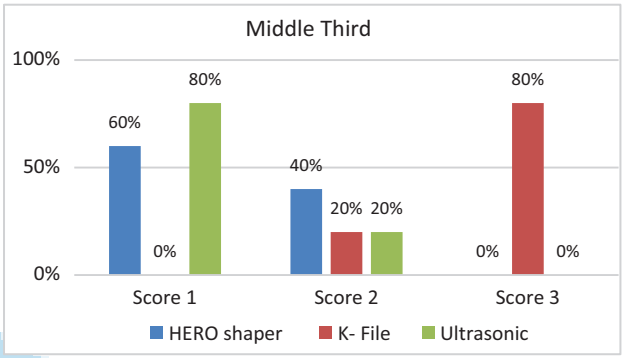

Figure 5: Residual calcium hydroxide in middle third

tends to release lower concentration of hydroxyl ions,[10] leading to diminished clinical effectiveness. The PUI is based on the transmission of energy from an ultrasonic oscillating instrument to the irrigant inside the root canal.[11] An irrigant solution in conjunction with ultrasonic vibration was directly associated with the removal of organic and inorganic debris from the root canal walls.[5,12] Thus, the effectiveness of irrigation depends on both the mechanical flushing action and the chemical ability to dissolve organic tissue.[4,8] In our study, the use of PUI improves the removal of $Ca(OH)_2$ from the root canal when compared to the manual technique. The HERO shaper has triple-helix cross section, constant taper, positive rake angle, noncutting tip,[6] no radial land, variable flute helical angle or increasing helical angle from tip to shank, variable flute pitch, and works at a speed of 300–600 rpm.[13,14] Positive rake angle cuts dentine effectively.[15-17] The long pitch prevents the screwing in phenomenon, increases the cutting action, and facilitates the excision and evacuation of dentine chips. This could be a possible reason for better removal of $Ca(OH)_2$ from root canal.[9] In this study, $Ca(OH)_2$ was removed more effectively in the middle third of the root as compared to the apical probably because of more anatomical variations and constrictions being present in the apical third.[18]

[Downloaded free from http://www.jpbsonline.org on Tuesday, May 28, 2019, IP: 223.181.246.18]

Conclusion

Within the limitations of this study, none of these systems were able to completely remove $Ca(OH)_2$ from root canal. PUI had the highest ability to remove $Ca(OH)_2$ from the root canal walls when compared to the use of HERO shaper followed by hand file system.

Financial support and sponsorship

Nil.

Conflicts of interest

There are no conflicts of interest.

References

1. Böttcher DE, de Mello Rahde N, Grecca FS. Calcium hydroxide removal: Effectiveness of ultrasonic and manual techniques. Rev Odonto Ciênc 2012;27:152-5.
2. Türker SA, Koçak MM, Koçak S, Sağlam BC. Comparison of calcium hydroxide removal by self-adjusting file, Endovac, and CanalBrush agitation techniques: An in vitro study. J Conserv Dent 2013;16:439-43.
3. Siqueira JF Jr, Lopes HP. Mechanisms of antimicrobial activity of calcium hydroxide: A critical review. Int Endod J 1999;32:361-9.
4. Calt S, Serper A. Dentinal tubule penetration of root canal sealers after root canal dressing with calcium hydroxide. J Endod 1999;25:431-3.
5. van der Sluis LW, Wu MK, Wesselink PR. The evaluation of removal of calcium hydroxide paste from an artificial standardized groove in the apical root canal using different irrigation methodologies. Int Endod J 2007;40:52-7.
6. Gutarts R, Nusstein J, Reader A, Beck M. In vivo debridement efficacy of ultrasonic irrigation following hand-rotary instrumentation in human mandibular molars. J Endod 2005;31:166-70.
7. Kuga MC, Campos EA, Faria-Junior NB, Só MV, Shinohara AL. Efficacy of NiTi rotary instruments in removing calcium hydroxide dressing residues from root canal walls. Braz Oral Res 2012;26:19-23.
8. Barbizam JV, Trope M, Teixeira EC, Tanomaru-Filho M, Teixeira FB. Effect of calcium hydroxide intracanal dressing on the bond strength of a resin-based endodontic sealer. Braz Dent J 2008;19:224-7.
9. Balvedi RP, Versiani MA, Manna FF, Biffi JC. A comparison of two techniques for the removal of calcium hydroxide from root canals. Int Endod J 2010;43:763-8.
10. Mohammadi Z, Dummer PM. Properties and applications of calcium hydroxide in endodontics and dental traumatology. Int Endod J 2011;44:697-730.
11. van der Sluis LW, Wu MK, Wesselink PR. A comparison between a smooth wire and a K-file in removing artificially placed dentine debris from root canals in resin blocks during ultrasonic irrigation. Int Endod J 2005;38:593-6.
12. Kenee DM, Allemang JD, Johnson JD, Hellstein J, Nichol BK. A quantitative assessment of efficacy of various calcium hydroxide removal techniques. J Endod 2006;32:563-5.
13. Oh SH, Park JK, Hur B, Kim HC. Comparison of screw-in effect of three NiTi file systems used by undergraduates. J Korean Acad Conserv Dent 2006;31:477-84.
14. George S, Anandaraj S, Issac JS, John SA, Harris A. Rotary endodontics in primary teeth—A review. Saudi Dent J 2016;28:12-7.
15. Dadresanfar B, Mehrvarzfar P, Saghiri MA, Ghafari S, Khalilak Z, Vatanpour M. Efficacy of two rotary systems in removing gutta-percha and sealer from the root canal walls. Iran Endod J 2011;6:69-73.
16. Schäfer E, Erler M, Dammaschke T. Comparative study on the shaping ability and cleaning efficiency of rotary Mtwo instruments. Part 1. Shaping ability in simulated curved canals. Int Endod J 2006;39:196-202.
17. Sanghvi Z, Mistry KU. Design features of rotary instruments in endodontics. J Ahmedabad Dent Coll Hosp 2011;2:6-11.
18. Bueno CE, Delboni MG, de Araújo RA, Carrara HJ, Cunha RS. Effectiveness of rotary and hand files in gutta-percha and sealer removal using chloroform or chlorhexidine gel. Braz Dent J 2006;17:139-43.