Original Article

Comparative evaluation of incidence of dentinal defects after root canal preparation using three different endodontic retreatment systems – An *in vitro* study

S. Aarthi, J. S. Sivakumar, A. Andamuthu Sivakumar, J. Saravanapriyan Soundappan, M. Chittrarasu, G. Jayanthi

Department of Conservative Dentistry, Vivekanandha Dental College for Women, Namakkal, Tamil Nadu, India

Downloaded from http://journals.lww.com/jcde by BhDMf5ePHKav1zEoum1tQfN4a+kJLhEZgbsIHo4XMi0hCywCX1AWnYQp/IlQrHD3i3D0OdRyi7TvSFl4Cf3VC4/OAVpDDa8K2+Ya6H515kE= on 03/12/2024

Abstract

Context: Safe and efficient removal of all root filling materials from the root canal system without compromising radicular dentin structure is essential for optimal nonsurgical retreatment.

Aims: The aim of this study was to evaluate and compare the incidence of dentinal defects caused during root canal filling removal using conventional, rotary, and reciprocating retreatment file systems.

Settings and Design: A detailed protocol explaining purpose and procedures of the study was submitted to the Institutional Ethics Committee and ethical clearance obtained.

Subjects and Methods: Sixty human maxillary permanent central incisors were collected and decoronated to 12-mm standardized length. The canals prepared up to a master apical file size F3 with Protaper hand files, obturated using AH plus sealer, examined under the stereomicroscope (×40 magnification): Group I: Control (n = 15), Group II: Conventional (n = 15), Group III: Protaper Universal Retreatment Files (n = 15), and Group IV: Reciproc Blue (n = 15). After instrumentation, teeth were sectioned at 3, 6, and 9 mm from the apex to evaluate the presence of dentinal defects under the stereomicroscope.

Statistical Analysis Used: Statistics were performed using the SPSS, version, 25 (SPSS Inc., Chicago, IL, USA). Initially, normality test was done using the Shapiro–Wilk test and data were not normally distributed followed by Kruskal–Wallis test. $P < 0.05$ is considered statistically significant.

Results: Maximum percentage increase in dentinal defects was observed in Protaper Universal Retreatment Files followed by Conventional method and Reciproc Blue.

Conclusions: Significantly Reciproc Blue reduced the incidence of dentinal defects after root canal preparation.

Keywords: AH plus sealer; dentinal defects; ProTaper hand files; retreatment; stereomicroscope

INTRODUCTION

The aim and objective of this study were to evaluate and compare the incidence of dentinal defects caused during root canal filling removal using conventional, rotary, and reciprocating retreatment file systems.

Address for correspondence:
Dr. J. S. Sivakumar,
Professor, Department of Conservative Dentistry and Endodontics, Vivekanandha Dental College for Women, Tiruchengode, Namakkal, TamilNadu, India.
E-mail: rohitsiva16@gmail.com

Date of submission : 07.11.2023
Review completed : 27.12.2023
Date of acceptance : 02.01.2024
Published : 06.03.2024

Access this article online

Quick Response Code:

Website: https://journals.lww.com/jcde

DOI: 10.4103/JCDE.JCDE_266_23

This is an open access journal, and articles are distributed under the terms of the Creative Commons Attribution-NonCommercial-ShareAlike 4.0 License, which allows others to remix, tweak, and build upon the work non-commercially, as long as appropriate credit is given and the new creations are licensed under the identical terms.

For reprints contact: WKHLRPMedknow_reprints@wolterskluwer.com

How to cite this article: Aarthi S, Sivakumar JS, Sivakumar AA, Soundappan JS, Chittrarasu M, Jayanthi G. Comparative evaluation of incidence of dentinal defects after root canal preparation using three different endodontic retreatment systems – An *in vitro* study. J Conserv Dent Endod 2024;27:262-7.

Downloaded from http://journals.lww.com/jcde by BhDMf5ePHKav1zEoum1tQfN4a+kJLhEZgbsIHo4XMi0hCywCX1AWnYQp/IlQrHD3i3D0OdRyi7TvSFl4Cf3VC4/OAVpDDa8K2+Ya6H515kE= on 03/12/2024

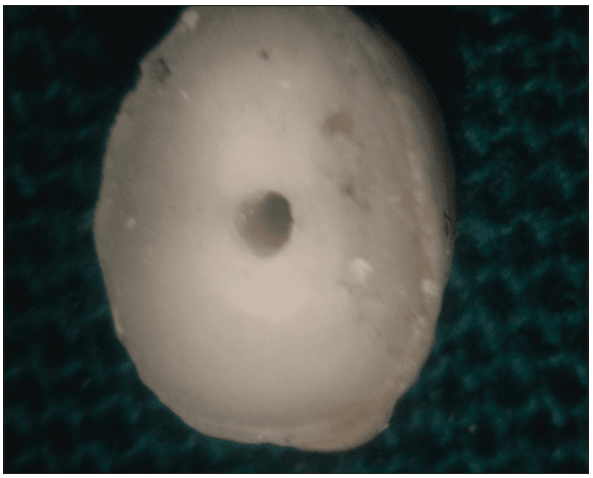

Figure 1: Stereomicroscope evaluation showing no defects

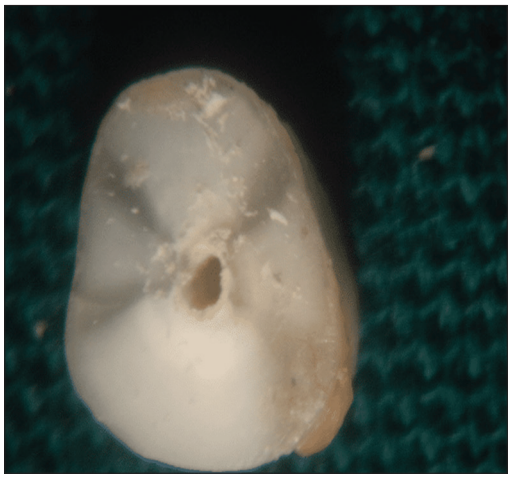

Figure 2: Stereomicroscope evaluation showing incomplete defects

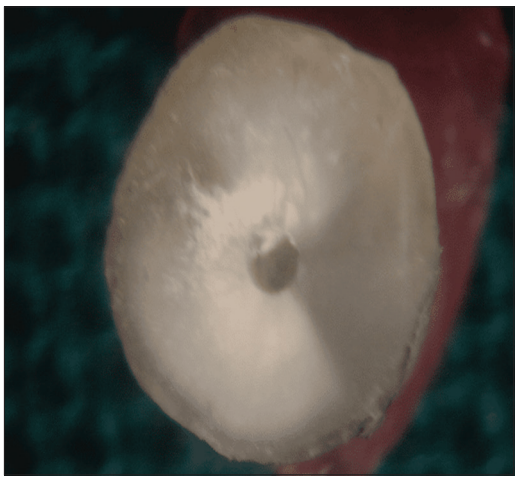

Figure 3: Stereomicroscope evaluation showing fracture

Root canal treatment includes proper diagnosis, treatment planning, anatomical evaluation, tooth debridement, shaping of root canal, and three-dimensional obturation.[1] Nonsurgical retreatment necessitates the complete removal of the previously existing endodontic restorative material to remove the necrotic tissues as well as the microbial populace.[2] Posttreatment disease after initial root canal treatment can occur due to the bacteria remaining in the root canal system due to inadequate cleaning, missed canals, inadequate root filling, or coronal leakage.[3]

Vertical root fractures (VRFs) have a poor prognosis for the affected tooth and should thus be avoided. The foundation of VRFs has been postulated to be local stress concentrations. Dentin defects caused by endodontic procedures can act as stress concentration areas, propagate from repeated stresses caused by subsequent endodontic and restorative procedures, and eventually develop into a VRF. Dentinal defects can be caused by a number of factors, including biomechanical preparation, root filling techniques, retreatment procedures, and postplacement. Retreatment procedures necessitate additional mechanical preparation of the root canal, which can result in additional damage to the root canal wall.[4,5]

It has been reported that canal preparation and obturation alone can damage root dentin and cause fracture, so repeating these procedures (retreatment) should increase the likelihood of defects.[6]

Conventional root canal retreatment is one of the most difficult technical challenges as it is necessary to reopen the root canal system by removing the original filling with endodontic hand files, heat instruments, ultrasonic instruments, or engine driven rotary files, followed by cleaning, shaping, and reobturation. For root filling removal and root canal retreatment the usage of nickel-titanium (NiTi) rotary instruments has been widely investigated as a promising approach. The ability to remove the root filling material without using gutta-percha solvents is an important feature of this method. On retreatment therapy, such a film may reduce the action of intracanal medicaments and the adhesion of the root canal sealer to the canal walls. Other advantages of rotary instruments are the nonutilization of potential carcinogenic products and the elimination of possible apical extrusion of gutta-percha by excessive dissolution of this material.[7]

The ProTaper Universal Retreatment system is a NiTi rotary instrument that is used for the removal of filling material from the root canal. The instruments have a convex triangular cross-section.[5] They have various tapers and diameters at the tip, which are size 30, 0.09 taper, size 25, 0.08 taper and size 20, 0.07 taper. These retreatment files have full lengths of 16 mm for D1, 18 mm for D2, and 22 mm for D3. To remove filling materials from the coronal, middle, and apical parts of the canals, D1, D2, and D3 are recommended. D1 has a working tip that facilitates its initial penetration into filling materials.[8]

Downloaded from http://journals.lww.com/jcde by BhDMf5ePHKav1zEoum1tQfN4a+kJLhEZgbsIHo4XMi0hCywCX1AWnYQp/IlQrHD3i3D0OdRyi7TvSFl4Cf3VC4/OAVpDDa8K2+Ya6H515kE= on 03/12/2024

Table 1: Comparison within experimental groups at 3 mm, 6 mm, and 9 mm from apex

Groups	Subgroups (mm)	*n*	Mean rank	Median	*P*
Control	3	15	24.50	0.133	0.351
	6	15	21.50	0	
	9	15	23.00	0.067	
	Total	45			
Conventional	3	15	23.50	0.333	0.326
	6	15	20.40	0.067	
	9	15	25.10	0.467	
	Total	45			
Protaper	3	15	26.23	0.6	0.318
	6	15	21.20	0.2	
	9	15	21.57	0.267	
	Total	45			
Reciproc blue	3	15	24.47	0.267	0.562
	6	15	21.43	0.067	
	9	15	23.10	0.267	
	Total	45			

The Reciproc blue system consists of three instruments. The Reciproc blue 25 has a tip diameter of 0.25 mm and an 8% taper over the first 3 mm from the tip. The Reciproc blue 40 has a tip diameter of 0.40 mm and a 6% taper over the first 3 mm. The Reciproc blue 50 has a tip diameter of 0.50 mm and a 5% taper over the first 3 mm. This file system is more resistant to cyclic fatigue and has greater flexibility. High efficiency and cutting performance are provided by the ideal combination of specific s-shaped cross section, variable taper, cutting angles, and thermally improved raw material.[9]

Safe and efficient removal of all root filling materials from the root canal system without compromising the radicular dentin structure is essential for the optimal nonsurgical retreatment. The aim of this study was to evaluate and compare the incidence of dentinal defects caused during root canal filling removal using conventional, rotary, and reciprocating retreatment file systems.

SUBJECTS AND METHODS

A detailed protocol explaining the purpose and procedures of the study was submitted to the Institutional Ethics Committee and ethical clearance was obtained.

Sixty intact human permanent maxillary central incisors were collected after being extracted for periodontal concerns. Teeth with severe curvatures, apical resorption, calcification, and fractures were excluded. The extracted teeth were collected and immediately stored in deionized water to which 0.1% thymol solution was added to prevent dehydration. All the teeth were thoroughly cleaned by removing the hard deposits and decoronated at the level of cemento-enamel junction using diamond disc, under water coolant, and root length of all the teeth was standardized to 12 mm.

The patency of each canal was confirmed with 15 size K-file and the working length (WL) determined by subtracting 1 mm from this measurement. The canals were prepared to a master apical size F3 with hand Protaper files following step-down technique. Each canal was irrigated with 2 mL of 2.5% sodium hypochlorite (NaOCl) using 27G side vented needle after every instrumentation and 2 mL of 17% ethylenediaminetetraacetic acid for 1 min as a final rinse irrigant and subsequently rinsed with 2 ml of distilled water. AH Plus sealer (Dentsply Maillefer) was coated into the canal using lentulospiral and obturated with Protaper gutta-percha points and allowed to set. Teeth were radiographed at different angulations to verify the quality of filling procedure and absence of voids. The obturated roots examined under the stereomicroscope at ×40 to ensure no visible cracks before the commencement of retreatment procedure. All the specimens were stored for 2 weeks at 37°C at 100% humidity to allow complete setting of the sealer. To simulate periodontal ligament space, the surfaces of sixty roots were coated with a silicone impression material. These teeth were then embedded in a tube filled with self-curing acrylic resin.

Sixty teeth were divided into four groups with 15 teeth per group as mentioned below:

- Group I – Control
- Group II – Conventional method
- Group III – ProTaper Universal Retreatment files (Rotary retreatment file)
- Group IV – Reciproc Blue (Reciprocating retreatment file).

Group I – Control group

Teeth in the control group were left undisturbed after obturation.

Group II – Conventional method

Gates Glidden drills size 3 and subsequently size 2 were used to remove the coronal filling material. The canals were then reinstrumented with Hedstrom files to remove filling material until the WL is achieved. After reaching the WL (with a size 15 file), sizes 20, 25, 30, 35, and 40 were used until the WL.

Group III – ProTaper universal retreatment files (rotary retreatment file)

ProTaper Universal retreatment files (Dentsply Maillefer, Ballaigues, Switzerland) were used to remove the root filling material. The D1 ProTaper instrument (size 30, 0.09 taper) was used for the removal of the coronal third of the root canal filling. The D2 ProTaper instrument (size 25, 0.08 taper) was used in the middle third of the root canal. Finally, the D3 ProTaper instrument (size 20, 0.07 taper) was used at the WL.

Downloaded from http://journals.lww.com/jcde by BhDMf5ePHKav1zEoum1tQfN4a+kJLhEZgbsIHo4XMi0hCywCX1AWnYQp/IlQrHD3i3D0OdRyi7TvSFl4Cf3VC4/OAVpDDa8K2+Ya6H515kE= on 03/12/2024

Group IV – Reciproc blue (reciprocating retreatment file)

Reciproc Blue (VDW, Munich, Germany) consists of Reciproc R25 instrument (size 25, 0.08 taper) was used to remove the root filling material. This procedure was repeated until the instrument reaches the WL. The retreatment procedure was concluded with the use of R40 instrument (size 40, 0.06 taper).

Each rotary, reciprocating, and hand instruments were discarded after being used in 1 sample. During retreatment, root canals were constantly irrigated with 1 mL 1% NaOCl at each instrument change. The retreatment procedure was considered complete when no gutta-percha or sealer is detected on the instrument surfaces or inside the root canal or dentinal walls.

The silicone impression material was removed, and all roots were cut horizontally at 3, 6, and 9 mm from the apex with a low-speed saw under water coolant. A total of 45 slices were examined in each group. The sectioned tooth was evaluated for the presence of dentinal defects under the stereomicroscope with ×40 magnification. Photographs were taken with digital camera attached to stereomicroscope.

Three distinct categories of root defects classified as follows:[10]

- "No defect" – Root dentine devoid of any lines or cracks and where both the external surface of the root and the internal root canal wall had No defect [Figure 1], Incomplete defects [Figure 2], Fracture [Figure 3]
- "Incomplete defects" – Lines that did not extend from the root canal to the outer root surface (e.g., a craze line, a line extending from the outer surface into the dentine but that did not reach the canal lumen, or a partial crack, a line extending from the canal walls into the dentine without reaching the outer surface)
- "Fracture" – A line extending from the root canal space to the outer surface of the root.

Statistics was performed using the SPSS, version, 25 (SPSS Inc., Chicago, IL, USA). Initially, normality test was done using Shapiro–Wilk test and was found that the data are not normally distributed. Then Kruskal–Wallis test was used to compare the groups. $P < 0.05$ is considered statistically significant.

RESULTS

Maximum percentage increase in dentinal defects was observed in Group III (Protaper Universal Retreatment Files) followed by Group II (Conventional method) and Group IV (Reciproc Blue) [Table 1].

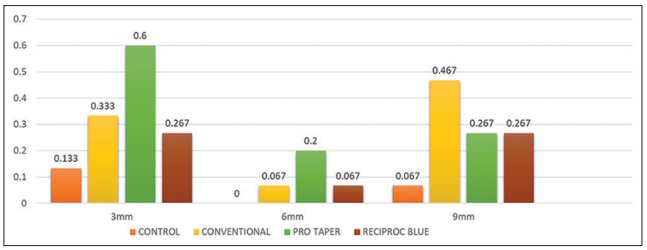

Graph 1: Median comparison within experimental groups at 3, 6, and 9 mm from apex

The incidence of defects was among the groups in the descending order [Graph 1].

Group III >Group II >Group IV >Group I.

When comparison was done for defects at 3 mm, 6 mm, and 9 mm, no statistical difference ($P < 0.05$) was observed:

3 mm from apex >9 mm from apex >6 mm from apex.

Statistically significant difference ($P < 0.05$) was observed in Group II, Group III, and Group IV as compared to Group I.

DISCUSSION

Endodontics prioritises resistance to tooth fracture because such fractures can reduce long-term survival rates.[11] Dentinal defects are considered as stress concentrators and a predisposing factor to VRF. The contact stress levels are determined by the design (cross-sectional and longitudinal) of the instruments and its kinematics.[12]

Rotary endodontics was created with the goal of reducing treatment time while increasing efficiency and accuracy in root canal preparation. Root canal preparation with various rotary NiTi endodontic instruments can cause stress and strain, which can result in the formation of micro cracks or craze lines in the root dentin.[13]

Reciprocating motion has several benefits, including increased durability, resistance to cyclic fatigue, and centred root canal preparation. This motion is also associated with clockwise and counter clockwise rotation, which aids in the release of the file when it is engaged in the radicular dentin during the preparation process.[14] As retreatment requires further mechanical manipulations in the canal, this can cause further damage to the root canal wall. Topçuoğlu *et al*.[3] who concluded that there was significant increase in the number of dentinal cracks after retreatment procedure.[15]

To prevent dehydration and to oavoid artifacts, the samples were stored in hydrated environment.[12,16] Decoronation of all the specimens was done using a diamond disc with

Downloaded from http://journals.lww.com/jcde by BhDMf5ePHKav1zEoum1tQfN4a+kJLhEZgbsIHo4XMi0hCywCX1AWnYQp/IlQrHD3i3D0OdRyi7TvSFl4Cf3VC4/OAVpDDa8K2+Ya6H515kE= on 03/12/2024

water coolant. By sectioning of samples which allowed to evaluate of the effect of root canal treatment procedures on the root dentine by direct inspection of the root canal wall and dentinal defects such as craze lines and incomplete cracks.[10,12]

In the present study, the roots were encapsulated with an elastomeric impression material and acrylic resin to mimic the periodontal ligament could influence the distribution of forces during the root canal preparation. According to Soros *et al.*, similar to the natural periodontal ligament, there is no artificial material capable of absorbing the forces on teeth. However, in the clinical situation, the presence of the periodontal ligament and the attempts to mimic this structure could contribute to the introduction of artificial changes in the force distribution.[17,18] Control Group A: When examined under a stereomicroscope before sectioning, samples revealed no cracks on the external surface. No cracks were discovered even after sectioning. This suggests that the study's sectioning approach did not cause any cracks. Hence, cracks in other groups should be related to the root canal preparation process.[13]

In a study investigating the effects of enlargement with Ni-Ti files on VRF, Kim *et al*.[19] found that greater stress increased dentin defect formation and that this formation was associated with the transverse section level (apical, middle, and coronal thirds). Versluis *et al*.[20] showed that sections from the middle and coronal thirds of the root were exposed to three-fold greater stress than were those from the apical third. Similarly, Üstün *et al*.[21] detected more frequent dentinal defects in the coronal third of roots.

Similarly, Bier *et al*.[22] and Yoldas *et al*.[23] reported no micro-cracking in specimens instrumented with hand-operated files. When coronal enlargement was performed with Gates-Glidden drills, micro-cracks have been observed in some studies. Through the effect of the burs on the dentine and the excessive removal of root structure that weakens the root, they may also play a role in the development of root defects during preparation.[17]

In our study, the use of the ProTaper Universal system was associated with the highest micro-crack formation rate, especially in the apical root area with subsequent crack initiation as compared to other rotary NiTi systems used in this study due to relative stiffness which led to more stress generation and concentration of stress, Craze line or microcracks created in root dentin due to rotational force applied to the canals of the root by NiTi rotary instruments.[24] Highly flexible endodontic instruments were associated with fewer dentinal defects since the high flexibility of the alloy generates not only less stresses on the root canal walls but also less pressure during instrumentation. ProTaper Universal files reduce debris efflux during enlargement due to their convex triangle shape in the transverse plane. In addition, these files have no radial area, which increases deviation from the center of the root. This characteristic may increase micro-crack formation by exerting more stress on the dentin. Due to taper design difference between hand and rotary files, preparation with rotary Ni-Ti files requires more rotations in the canal which contribute to the formation of dentinal defects.[25]

Liu *et al*.[26] observed more micro-crack formation with the use of the ProTaper Universal and OneShape systems than with the use of the Reciproc and self-adjusting file systems. Compared with specimens prepared with the ProTaper Universal system, less micro-crack formation was observed in specimens prepared with Reciproc rotary files in our study. The use of a single file during enlargement may reduce micro-crack formation compared with the use of multiple files.[12,27]

In the present study, the incidence of dentinal defects in RECIPROC blue was found to be with a statistically significant difference with Group II and III. The reason behind this result due to the fact that although RECIPROC blue is a reciprocating file with S shape cross-section design with two cutting edges and identical taper which are fixed at the apical 3 mm then the file has regressive taper and manufactured from blue NiTi alloy unlike RECIPROC instruments that manufactured using M-Wire NiTi alloy. Blue NiTi alloy obtained through a proprietary thermomechanical process that showed overall improved performances when compared with conventional M-Wire and superelastic NiTi alloy, demonstrating improved flexibility, reduced microhardness and produces a NiTi alloy that is softer and more ductile than the conventional one. Highly flexible endodontic instruments were associated with fewer dentinal defects since high flexibility of the alloy generates not only less stresses on the root canal walls but also less pressure on the instrument is required during instrumentation.[28]

According to Kumaran *et al*.,[29] significant effect on dentin defect formation and on fracture resistance due to instrumentation of root canals.

Moreover, the development of dentinal defects in different levels of the root canal wall may be influenced by the canal morphology; the narrow thickness of the canal in the apical area makes it more susceptible to crack formation because it has less ability to withstand the generated stresses during instrumentation. The results indicate that there might be an association between the designs and motions of the NiTi systems used in the present study and the incidence of dentinal defects.[5,28]

CONCLUSIONS

Within the limitation of this study, it can be concluded that

craze lines were also present in relation to uninstrumented roots and performing additional treatment during the gutta-percha removal procedure would increase the incidence of dentin defects. Protaper universal retreatment files resulted in maximum percentage increase in the number of dentinal defects formation followed by H-file and RECIPROC Blue.

Financial support and sponsorship

Nil.

Conflicts of interest

There are no conflicts of interest.

REFERENCES

1. Das D, Barai S, Kumar R, Bhattacharyya S, Maity AB, Shankarappa P. Comparative evaluation of incidence of dentinal defects after root canal preparation using hand, rotary, and reciprocating files: An *ex vivo* study. J Int Oral Health 2022;14:78-85.
2. Das M, Shivakumar S, Das A, Mailankote S, Naik S, Sathydevi P. Assessment of root dentin defect during retreatment procedure using various NiTi hand and rotary retreatment files: An *in vitro* study. J Pharm Bioallied Sci 2022;14:S573-6.
3. Topçuoğlu HS, Demirbuga S, Tuncay Ö, Pala K, Arslan H, Karataş E. The effects of Mtwo, R-Endo, and D-RaCe retreatment instruments on the incidence of dentinal defects during the removal of root canal filling material. J Endod 2014;40:266-70.
4. Yilmaz A, Helvacioglu-Yigit D, Gur C, Ersev H, Kiziltas Sendur G, Avcu E, *et al.* Evaluation of dentin defect formation during retreatment with hand and rotary instruments: A micro-CT study. Scanning 2017;2017:4868603.
5. Üstün Y, Topçuoğlu HS, Düzgün S, Kesim B. The effect of reciprocation versus rotational movement on the incidence of root defects during retreatment procedures. Int Endod J 2015;48:952-8.
6. AbuMostafa A, Almoqayyad H, Mohammad AO. A digital microscopic inspection of dentinal defects after using endodontic retreatment files. Int J Dent 2021;2021:6661387.
7. Fariniuk LF, Westphalen VP, Silva-Neto UX, Carneiro E, Baratto Filho F, Fidel SR, *et al.* Efficacy of five rotary systems versus manual instrumentation during endodontic retreatment. Braz Dent J 2011;22:294-8.
8. Gu LS, Ling JQ, Wei X, Huang XY. Efficacy of ProTaper Universal rotary retreatment system for gutta-percha removal from root canals. Int Endod J 2008;41:288-95.
9. Yared G, Blue R. The new generation of reciprocation. G Ital Endod 2017;31:96-101.
10. Shemesh H, Bier CA, Wu MK, Tanomaru-Filho M, Wesselink PR. The effects of canal preparation and filling on the incidence of dentinal defects. Int Endod J 2009;42:208-13.
11. Al-Zaka IM. The effects of canal preparation by different NiTi rotary instruments and reciprocating Waveone file on the incidence of dentinal defects. MDJ 2012;9:137-42.
12. Devi TP, Kaur A, Priyadarshini S, Deepak BS, Banerjee S, Sanjeeta N. Microscopic assessment of dentinal defects induced by ProTaper universal, ProTaper gold, and Hyflex electric discharge machining rotary file systems – An *in vitro* study. Contemp Clin Dent 2021;12:230-4.
13. Monga P, Bajaj N, Mahajan P, Garg S. Comparison of incidence of dentinal defects after root canal preparation with continuous rotation and reciprocating instrumentation. Singapore Dent J 2015;36:29-33.
14. Pawar AM, Thakur B, Kfir A, Kim HC. Dentinal defects induced by 6 different endodontic files when used for oval root canals: An *in vitro* comparative study. Restor Dent Endod 2019;44:e31.
15. Jain A, Nikhil V, Bansal P. Effect of root canal preparation, obturation, and retreatment on the induction of dentinal microcracks: A microcomputed tomography study. J Conserv Dent 2018;21:521-5.
16. Chandwani N, Ranka A, Jadhav GR, Jagyasi D, Bopche P, Golchha A. Effect of various single file systems on microcrack formation in root canals: Scanning electron microscope study. Dent Res J (Isfahan) 2021;18:52.
17. Martins JC, Oliveira BP, Duarte DA, Antonino AC, Aguiar CM, Câmara AC. Micro-computed tomographic assessment of dentinal microcrack formation in straight and curved root canals in extracted teeth prepared with hand, rotary and reciprocating instruments. Int Endod J 2021;54:1362-8.
18. Aksoy Ç, Keriş EY, Yaman SD, Ocak M, Geneci F, Çelik HH. Evaluation of XP-Endo Shaper, Reciproc Blue, and ProTaper Universal NiTi systems on dentinal microcrack formation using micro-computed tomography. J Endod 2019;45:338-42.
19. Kim HC, Lee MH, Yum J, Versluis A, Lee CJ, Kim BM. Potential relationship between design of nickel-titanium rotary instruments and vertical root fracture. J Endod 2010;36:1195-9.
20. Versluis A, Messer HH, Pintado MR. Changes in compaction stress distributions in roots resulting from canal preparation. Int Endod J 2006;39:931-9.
21. Ustun Y, Aslan T, Sagsen B, Kesim B. The effects of different nickel-titanium instruments on dentinal microcrack formations during root canal preparation. Eur J Dent 2015;9:41-6.
22. Bier CA, Shemesh H, Tanomaru-Filho M, Wesselink PR, Wu MK. The ability of different nickel-titanium rotary instruments to induce dentinal damage during canal preparation. J Endod 2009;35:236-8.
23. Yoldas O, Yilmaz S, Atakan G, Kuden C, Kasan Z. Dentinal microcrack formation during root canal preparations by different NiTi rotary instruments and the self-adjusting file. J Endod 2012;38:232-5.
24. Shori DD, Shenoi PR, Baig AR, Kubde R, Makade C, Pandey S. Stereomicroscopic evaluation of dentinal defects induced by new rotary system: "ProTaper NEXT". J Conserv Dent 2015;18:210-3.
25. Garg S, Mahajan P, Thaman D, Monga P. Comparison of dentinal damage induced by different nickel-titanium rotary instruments during canal preparation: An *in vitro* study. J Conserv Dent 2015;18:302-5.
26. Liu R, Kaiwar A, Shemesh H, Wesselink PR, Hou B, Wu MK. Incidence of apical root cracks and apical dentinal detachments after canal preparation with hand and rotary files at different instrumentation lengths. J Endod 2013;39:129-32.
27. Deveci Taç M, Kaya S, Falakaloğlu S. Evaluation of dentinal micro-cracks caused by the ProTaper Universal, ProTaper Next and Reciproc rotary file systems used in root canal preparation. Int Dent Res 2018;8:111-6.
28. Hussien SW, Al-Gharrawi HA. Incidence of dentinal root defects caused by RECIPROC Blue, ProTaper Gold, ProTaper NEXT and RECIPROC nickel titanium rotary instruments. J Contemp Dent Pract 2019;20:291-7.
29. Kumaran P, Sivapriya E, Indhramohan J, Gopikrishna V, Savadamoorthi KS, Pradeepkumar AR. Dentinal defects before and after rotary root canal instrumentation with three different obturation techniques and two obturating materials. J Conserv Dent 2013;16:522-6.

Downloaded from http://journals.lww.com/jcde by BhDMf5ePHKav1zEoum1tQfN4a+kJLhEZgbsIHo4XMi0hCywCX1AWnYQp/IlQrHD3i3D0OdRyi7TvSFl4Cf3VC4/OAVpDDa8K2+Ya6H515kE= on 03/12/2024