Original Article

Efficacy of Locally Delivered Herbal Chip Containing (8% *Mimusops elengi*) as an Adjunct to Scaling and Root Planing in Chronic Periodontitis: A Randomised Split-mouth Clinical Study

Udhya A S, Gopinath Vivekanandan, Gayathri Priyadharshini Elangovan, Settu Saranya, Duraisamy Surya, Karthik Krishna Munagala[1]

Department of Periodontics, Vivekanandha Dental College for Women, Tiruchengode, Tamil Nadu, [1]Department of Periodontics, Rungta College of Dental Sciences and Research, Bhilai, Chhattisgarh, India

Downloaded from http://journals.lww.com/adhb by BhDMf5ePHKav1zEoum1tQfN4a+kJLhEZgbsIHo4XMi0hCywCX1AWnYQp/IlQrHD3i3D0OdRyi7TvSFl4Cf3VC1y0abggQZXdgGj2MwlZLeI= on 09/09/2024

Abstract

Introduction: Conventional mechanical debridement does not remove all pathogenic bacteria from the subgingival environment. To overcome these limitations, local drug delivery systems enhance the curative effect by combining with drugs, which promote bone and tissue regeneration. Thus, this study aims to evaluate the efficacy of locally delivered herbal chips containing (8% *Mimusops elengi*) as an adjunct to scaling and root planing (SRP) and compared to SRP alone for the treatment of chronic periodontitis. **Materials and Methods:** A randomised split-mouth clinical study was conducted among chronic periodontitis patients undergoing periodontal therapy. Thirty subjects with 60 sites were divided into test and control groups. The control sites were treated with SRP alone, whereas the test sites were treated with SRP followed by placement of an 8% *M. elengi* herbal chip within the pockets. Patients were recalled on the 21st and 45th day, and clinical parameters were measured. **Results:** An inter-group comparison of all the clinical parameters between the control and test sides was statistically analysed. At all periods of the study, the mean difference was observed to be highly significant ($P < 0.001$). **Conclusion:** The 8% *M. elengi* chip is effective as an adjunct to non-surgical periodontal therapy in chronic periodontitis probing depth. Further clinical studies are needed to evaluate the long-term efficacy of *M. elengi*.

Keywords: Conventional mechanical debridement, local drug delivery systems, locally delivered herbal chip, *Mimusops elengi*, randomised split-mouth clinical study

Introduction

Periodontal diseases enclose a wide variety of inflammatory conditions of the gingiva, bone and ligament and the connective tissue collagen fibres supporting the teeth. It begins with gingivitis, which is the localised inflammation of the gingiva that is initiated by bacterial biofilm in the dental plaque. Periodontal diseases contribute to the overall inflammatory burden of the body by altering the immune inflammatory response.[1,2]

The first recommended therapy to control periodontal disease is non-surgical periodontal therapy (NSPT), the cornerstone of periodontal therapy.[3] The major goal of NSPT is to reduce or eliminate the subgingival pathogenic microbial flora and it is considered a 'gold standard' treatment method when compared to other procedures.[4] After scaling and root planing, there is a reduction of pocket depth and an improvement in clinical attachment level (CAL).[5]

Access this article online

Quick Response Code:

Website: www.aihbonline.com

DOI: 10.4103/aihb.aihb_33_24

Conventional mechanical debridement does not remove all pathogenic bacteria from the subgingival environment, especially in inaccessible areas such as furcations, grooves and deep pockets. To overcome these limitations, drug delivery systems are used to enhance the curative effect by combining with drugs that promote bone and tissue regeneration.[6]

Systemic administration and local administration are the two important methods of drug delivery. Systemic administration is

Address for correspondence: Dr. Gopinath Vivekanandan, Department of Periodontics, Vivekanandha Dental College for Women, Tiruchengode, Tamil Nadu, India.
E-mail: gopivivek1@gmail.com

Submitted: 04-Mar-2024 **Revised:** 01-Apr-2024
Accepted: 07-Apr-2024 **Published:** 21-Jun-2024

This is an open access journal, and articles are distributed under the terms of the Creative Commons Attribution-NonCommercial-ShareAlike 4.0 License, which allows others to remix, tweak, and build upon the work non-commercially, as long as appropriate credit is given and the new creations are licensed under the identical terms.

For reprints contact: WKHLRPMedknow_reprints@wolterskluwer.com

How to cite this article: Udhya AS, Vivekanandan G, Elangovan GP, Saranya S, Surya D, Munagala KK. Efficacy of locally delivered herbal chip containing (8% *Mimusops elengi*) as an adjunct to scaling and root planing in chronic periodontitis: A randomised split-mouth clinical study. Adv Hum Biol 2024;14:357-61.

Downloaded from http://journals.lww.com/adhb by BhDMf5ePHKav1zEoum1tQfN4a+kJLhEZgbsIHo4XMi0hCywCX1AWnYQp/IlQrHD3i3D0OdRyi7TvSFl4Cf3VC1y0abggQZXdgGj2MwlZLeI= on 09/09/2024

effective only when given sufficient doses to achieve the desired concentration. When used in higher concentrations, systemic delivery results in toxicity, gastrointestinal intolerance and drug resistance, which leads to problems such as dysbacteriosis and poor biodistribution.[7]

To overcome this disadvantage, local drug delivery (LDD) agents were introduced to enhance non-surgical therapy, which serves as an adjunct to scaling and root planing. LDD was introduced by Dr. Max Goodson in 1979. The main goal of LDD is to deliver the anti-microbial agents directly into the periodontal pockets, which release the drug in an immediate or controlled/sustained manner. It has various advantages such as minimally invasive, direct application and higher efficacy of drugs with the reduction in dose and frequency of drug, which results in no gastrointestinal issues and first-pass metabolism.[8]

Herbal medicines enclosing plant constituents have therapeutic benefits and are favoured over conventional drugs. Artificial antimicrobial agents cause anti-microbial resistance. Hence, natural phytochemicals are considered worthy substitutes for these synthetic agents.

Mimusops elengi, a small-to-large tree found in Andaman Island and the Deccan Peninsula, has contributed to the field of science from ancient times to modern research due to its large medicinal properties. *M. elengi* has anti-bacterial, anti-fungal, anti-inflammatory and analgesic properties in experimental animals at a dose of 200 mg/kg.[9] *M. elengi* aqueous extract-derived mouth rinse was found to be a plaque inhibitor. It helped treat oral complications such as dental caries and gum bleeding. Due to its diverse properties, *M. elengi* can be used as a potent ingredient in treatment for periodontal therapy and can be used as an adjunct to NSPT.[10]

Phogat *et al*.,[11] in 2014, in a clinical study, evaluated the bark of *M. elengi* gel in chronic periodontitis. They stated there were significant reductions in the probing depth (PD) of patients due to its anti-microbial effect. This study was designed to determine the efficacy of an 8% *M. elengi* chip as an adjunct to nonsurgical therapy (scaling and root planing [SRP]) in chronic periodontitis.

Thus, this study aims to evaluate the efficacy of locally delivered herbal chips containing (8% *M. elengi*) as an adjunct to SRP and compared to SRP alone for treating chronic periodontitis through clinical parameters.

Materials and Methods

A randomised split-mouth clinical study was conducted after approval from the institutional ethical committee in January 2022 (ETH/2022/234). This study was carried out according to Helsinki Declaration. The study was explained to patients, and informed consent was obtained from them. Thirty patients with 60 sites selected, aged 30–50, with chronic periodontitis undergoing periodontal therapy at the department of periodontics, were enroled.

Inclusion criteria included patients aged 30–50, medically healthy individuals, and patients with a pocket depth of 5–6 mm bilaterally as examined by the Williams probe.

Exclusion criteria were smoking or tobacco use in any form, medications that affect the periodontal treatment and blood coagulation, use of anti-biotics, anti-inflammatory drugs 3 months before the study, use of mouthwash and plaque controlling agents, diabetic patients or other immunocompromised patients, any form of tobacco, alcohol users, patients who are allergic to certain drugs and pregnant and lactating women.

Thirty subjects with 60 sites were divided into test and control groups. Control sites will be treated with SRP alone, whereas the test sites will be treated with SRP followed by placement of herbal chip within the pockets.

Extraction of 8% *Mimusops elengi*

The fresh leaves of *M. elengi* were procured and approved by a botanist from Alpha Omega Hi-tech Bio research Centre Salem. Fresh leaves of *M. elengi* were cleaned using 500 mL of distilled water, dried and stored in a clean, airtight container for further use. Ethanol extract of leaves was obtained using the Soxhlet apparatus. 0.08 g of dried leaves of *M. elengi* is placed in the thimble of the Soxhlet apparatus. One hundred millilitre of ethanol will be used as a solvent.[12] The extract was stored in a clean airtight container until further use.

Preparation of 8% *Mimusops elengi* chip

The formulation was done at JSS College of Pharmacy, Ooty. Hydrolysed collagen (HealthyHey Pure Hydrolysed Collagen) and chitosan (BFCLAB CHITOSAN 10 g powder) were mixed to form a gel base. A mixture of hydrolysed collagen and chitosan is then added with polyvinyl alcohol to make it soluble in the liquid form to make a gel base. Gel-based mixtures containing all three components are poured into the plates for drying [Figure 1]. After it had been dried, 5 g of ethanolic extract of 8% *M. elengi* prepared from (Alpha Omega Hi-tech Bio research Centre Salem) was added to the dried film in plates and allowed to dry at room temperature. After complete drying, the sheets were uniformly sliced into 4 mm × 5 mm rectangular chips with one rounded end, resembling a *U* shape [Figure 2]. It was packed and submitted for gamma radiation.[13]

Determination of release kinetics of prepared chip by Franz diffusion cell method

It is used to assess drug dissolution. It is done for drug in liquid form incorporated in polymer. The maximum release pattern was calculated and taken for the duration [Figure 3]. The maximum release of the drug occurs in 72–96 h, and there was a sustained release of the drug.[14]

Clinical procedure

In 1st visit baseline, clinical parameters were recorded and patients were randomised into test and control sites and scaling was done using ultrasonic scaler tips.

Patients were recalled after 7 days; root planing was done under local anaesthesia (LOX 2%) using Gracey curettes (Hu-Friedy)

Downloaded from http://journals.lww.com/adhb by BhDMf5ePHKav1zEoum1tQfN4a+kJLhEZgbsIHo4XMi0hCywCX1AWnYQp/IlQrHD3i3D0OdRyi7TvSFl4Cf3VC1y0abggQZXdgGj2MwlZLeI= on 09/09/2024

in both control and test sites. After root planing selected test sites were isolated and dried using sterile gauze. After drying prepared 4 mm × 5 mm 8% *M. elengi* chip were gently positioned using tweezers and placed into the periodontal pockets of 5–6 mm. After insertion, they are secured in the pockets. The complete release of drug from the periodontal chip occurs for a period of 72-96 hrs thus the periodontal pack is placed over the region of chip placement to secure the chip in the periodontal pocket. Post-therapy instructions were given and patients were recalled after 7 days.



Figure 1: Film.



Figure 2: Eight per cent *Mimusops elengi* chip.

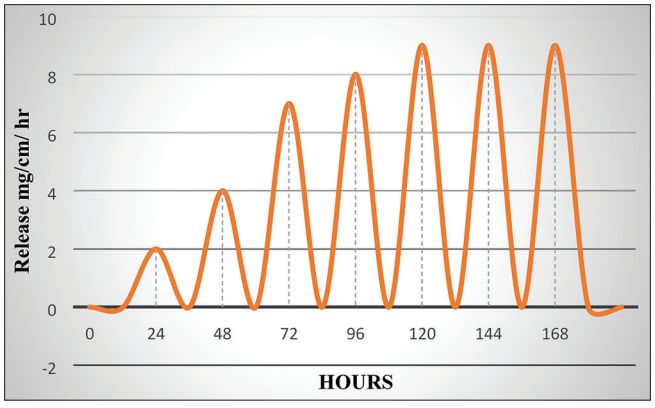

Figure 3: Release kinetics of chip.

Coe pack was removed after 7 days and saline irrigation was done. Test sites were examined for any complications. Clinical parameters (plaque, gingival, gingival bleeding index, PD and CAL) were measured at 7 days in both control and test sites and patients were instructed to reinforce oral prophylaxis. Patients were recalled again on the 21st and 45th day and clinical parameters were measured.

Results

Statistical analysis was done using SPSS software version 25.0. Comparison between four-time intervals baseline, 7 days, 21 days and 45 days for plaque, gingival, gingival bleeding index and CAL was done using repeated measures analysis of variance. Comparison between test and control sites was done using unpaired *t*-tests. A comparison of PD between four-time intervals was analysed using the Friedman test. Comparison between test and control sites was done using the Mann–Whitney *U* test.

Table 1 shows inter-group comparison of the mean plaque index between the control and test sides. At all periods of the study, the difference in means was observed to be highly significant ($P < 0.001$).

Table 2 shows the inter-group comparison of the mean gingival index between the control and test sides. At baseline, the

Table 1: Inter-group comparison of mean plaque index between control and test sides using unpaired *t*-test at all periods of the study

	Groups	*n*	Mean±SD	Mean difference	*P*
Baseline	Control	30	2.500±0.264	−0.294	<0.001*
	Test	30	2.794±0.184		
After 7 days	Control	30	2.142±0.315	0.425	<0.001*
	Test	30	1.717±0.312		
After 21 days	Control	30	1.662±0.296	0.679	<0.001*
	Test	30	0.983±0.271		
After 45 days	Control	30	1.994±0.288	0.712	<0.001*
	Test	30	1.282±0.282		

*Significant. SD: Standard deviation

Table 2: Inter-group comparison of mean gingival index between control and test sides using unpaired *t*-test at all periods of the study

	Groups	*n*	Mean±SD	Mean difference	*P*
Baseline	Control	30	2.547±0.326	−0.230	0.002*
	Test	30	2.777±0.183		
After 7 days	Control	30	2.374±0.298	0.285	<0.001*
	Test	30	2.088±0.179		
After 21 days	Control	30	1.879±0.277	0.542	<0.001*
	Test	30	1.337±0.234		
After 45 days	Control	30	1.560±0.288	0.567	<0.001*
	Test	30	0.993±0.251		

*Significant. SD: Standard deviation

Downloaded from http://journals.lww.com/adhb by BhDMf5ePHKav1zEoum1tQfN4a+kJLhEZgbsIHo4XMi0hCywCX1AWnYQp/IlQrHD3i3D0OdRyi7TvSFl4Cf3VC1y0abggQZXdgGj2MwlZLeI= on 09/09/2024

difference between mean values was found to be statistically significant ($P < 0.05$) with a mean difference of 0.230. At all other periods, the difference between the means of control and test groups was highly significant ($P < 0.001$).

Table 3 shows the inter-group comparison of the mean gingival bleeding index between the control and test sides. At baseline and 7th day of the study, the comparison result was found to be statistically significant ($P < 0.05$), while after 21 and 45 days of the study, the comparison result was observed to be highly significant ($P < 0.001$).

Table 4 shows inter-group comparison of the means of the CAL between baseline, after 7 days, 21 days and 45 days for SRP and CHIP groups. SRP group at baseline, after 7, 21 and 45 days of CAL, which shows that the CAL was reduced on the 7th day (4.823 ± 0.1924), 21st day (4.290 ± 0.2857) when compared to baseline (5.083 ± 0.1949) and again increased on 45th day (4.523 ± 0.2932). The result was statistically significant, with a $P = 0.000$. The CHIP group at baseline, after 7, 21 and 45 days of CAL shows that the CAL was reduced on the 45th day (3.897 ± 0.3189) when compared to baseline (5.290 ± 0.2090). The CAL gradually reduced from baseline to the 45th day, and the result was statistically significant with a $P = 0.000$.

Table 5 shows a group comparison of the means of CAL between the SRP and CHIP, revealing that at baseline, the CHIP groups showed increased CAL compared to the SRP group, with a significant $P = 0.002$. After 7 days, 21 days and 45 days, the CAL was reduced more in the CHIP group than the SRP group, and the P value is also statistically significant at about 0.000, respectively.

Table 3: Inter-group comparison of mean gingival bleeding index between control and test sides using unpaired *t*-test at all periods of the study

	Groups	*n*	Mean	SD	Mean difference	*P*
Baseline	Control	30	2.405	0.343	−0.182	0.021*
	Test	30	2.587	0.244		
After 7 days	Control	30	2.201	0.330	0.197	0.015*
	Test	30	2.003	0.279		
After 21 days	Control	30	1.798	0.313	0.438	<0.001*
	Test	30	1.360	0.246		
After 45 days	Control	30	1.454	0.292	0.465	<0.001*
	Test	30	0.989	0.247		

*Significant. SD: Standard deviation

Table 4: Inter-group comparison of the means of the clinical attachment level between baseline, after 7 days, 21 days and 45 days for scaling and root planing and CHIP group (repeated measures ANOVA)

CAL	*n*	Mean±SD	*P*
SRP			
Baseline	30	5.083±0.1949	0.000*
After 7 days	30	4.823±0.1924	
After 21 days	30	4.290±0.2857	
After 45 days	30	4.523±0.2932	
CHIP			
Baseline	30	5.290±0.2090	0.000*
After 7 days	30	4.557±0.2176	
After 21 days	30	3.767±0.3209	
After 45 days	30	3.897±0.3189	

*Significant. SD: Standard deviation, SRP: Scaling and root planing, CAL: Clinical attachment level

Table 5: Comparison of the means of pocket depth at baseline, after 7 days, 21 days and 45 days between scaling and root planing and CHIP groups (Mann–Whitney *U*-test)

Pocket depth	Study groups	Mean±SD	*P*
Baseline	SRP	4.923±0.1977	0.002*
	CHIP	5.103±0.2025	
After 7 days	SRP	4.677±0.1977	0.000*
	CHIP	4.460±0.2044	
After 21 days	SRP	4.050±0.1978	0.000*
	CHIP	3.633±0.2279	
After 45 days	SRP	3.723±0.2063	0.000*
	CHIP	3.120±0.2657	

*Significant. SD: Standard deviation, SRP: Scaling and root planing

Discussion

Periodontal disease is a plaque-induced disease entity and a majority of patients are not trained in mechanical plaque removal. Hence, professional cleaning is needed to maintain the long-term stability of the periodontium.[15,16]

Systemically administered antibiotics reinforce mechanical debridement and help the host's defense mechanism overcome the subgingival pathogenic infection that remains after conventional therapy. Major disadvantages of systemic therapy lead to superinfections from previous use of antibiotics. Periodontal disease does not resolve and aggravates further if the resistant bacteria constitute potential pathogens.[16]

LDD, the concept of controlled and sustained delivery of drugs into subgingival pockets, was introduced by Dr. Max Goodson. Various anti-microbials are given in the form of injectable systems, gels, chips, ointment, strips, micro and nanoparticle systems. In recent times, novel drugs such as herbal products have been tried in LDD, which includes chamomile, neem extract, turmeric and pomegranate.[17]

Microbiological evaluation and minimum inhibitory concentration of *M. elengi* have been evaluated. The fruit, seed, stem bark and leaf extract are anti-bacterial against Gram-positive and Gram-negative bacteria.[18] They are also effective in wound healing and ulcers and increase the tensile strength of the incision.[19]

Phogat *et al*.[11] in 2014, evaluated the zones of inhibition for Chlosite and Carbopol-based herbal gel containing (*M. elengi* –

Downloaded from http://journals.lww.com/adhb by BhDMf5ePHKav1zEoum1tQfN4a+kJLhEZgbsIHo4XMi0hCywCX1AWnYQp/IlQrHD3i3D0OdRyi7TvSFl4Cf3VC1y0abggQZXdgGj2MwlZLeI= on 09/09/2024

8%, Acacia Arabica – 7% and *Punica granatum* – 8%) using liquid agar nutrient medium. The study concluded after 30 h of incubation, both chlorite and herbal gel have an inhibition zone of 4.09 ± 0.73 mm and 3.89 ± 1.27 mm and have anti-microbial activity. Eight percent *M. elengi* will eliminate the periodontal pathogens in subgingival pockets. Hence, LDD of 8% *M. elengi* chip is used in the present study.

The decrease in the bleeding index is due to the anti-oxidant properties of *M. elengi* leaves, which have the ability to scavenge free radicals by dismuting superoxide radicals to H202 and also diminish the toxic effects produced by the free radicals. This is in concordance with an experimental study on diabetic rats by Shaik *et al*.[20]

Significant reduction in PD in test sites is due to the placement of an 8% *M. elengi* chip, which shows the chip has better wound healing and regenerative properties and reduction in inflammatory load, which was in concordance with a study with Gupta *et al*.[21]

Mean CALs were significantly reduced on the 21st day. The gain in attachment level on the 21st day in this study is concordance in with the study of Phogat *et al*.[11] where she compared the SRP, Chlosite gel and herbal gel.

Limitations of the study include a need for microbiological, radiographic and histological evidence for regenerative assessment. Small sample size and there was only a single-time placement of chip with no repeated application and a short period for follow-up. Long-term follow-up investigations are needed for further evaluation.

Conclusion

Eight per cent *M. elengi* chip is effective as an adjunct to NSPT in chronic periodontitis and reduction in PD. Further, clinical studies are needed to evaluate the long-term efficacy of *M. elengi*.

Financial support and sponsorship

Nil.

Conflicts of interest

There are no conflicts of interest.

References

1. Dubey P, Mittal N. Periodontal diseases- a brief review. Int J Oral Health Dent 2020;6:177-87.
2. Kinane DF, Stathopoulou PG, Papapanou PN. Periodontal diseases. Nat Rev Dis Primer 2017;3:17038.
3. Shetty B, Divakar DD, Jameel AH, Almalki SA, Gowdar IM, Dewan H. Effect of non-surgical periodontal therapy with adjunct photodynamic therapy on periodontal and glycemic statuses in prediabetic patients with periodontal disease. Photodiagnosis Photodyn Ther 2023;42:103362.
4. Chung WC, Huang CF, Feng SW. Clinical benefits of minimally invasive non-surgical periodontal therapy as an alternative of conventional non-surgical periodontal therapy-a pilot study. Int J Environ Res Public Health 2022;19:7456.
5. Tanwar J, Hungund SA, Dodani K. Nonsurgical periodontal therapy: A review. J Oral Res Rev 2016;8:39.
6. Ehizele A, Akhionbare O. Effect of non-surgical periodontal therapy on the concentration of volatile sulfur compound in mouth air of a group of Nigerian young adults. Ann Med Health Sci Res 2013;3:433-7.
7. Rajeshwari HR, Dhamecha D, Jagwani S, Rao M, Jadhav K, Shaikh S, *et al.* Local drug delivery systems in the management of periodontitis: A scientific review. J Control Release 2019;307:393-409.
8. Wei Y, Deng Y, Ma S, Ran M, Jia Y, Meng J, *et al.* Local drug delivery systems as therapeutic strategies against periodontitis: A systematic review. J Control Release 2021;333:269-82.
9. – Kadam PV. *Mimusops elengi*: A review on ethnobotany; phytochemical and pharmacological profile.Phytojournal. 2012;1:64-74.
10. Salve AV, Malik R, Ansari S, Uike S. *Mimusops elengi* (Linn.): An effective aid in dental care. J Glob Oral Health 2022;5:54-7.
11. Phogat M, Rana T, Prasad N, Baiju CS. Comparative evaluation of subgingivally delivered xanthan-based chlorhexidine gel and herbal extract gel in the treatment of chronic periodontitis. J Indian Soc Periodontol 2014;18:172-7.
12. Redfern J, Kinninmonth M, Burdass D, Verran J. Using soxhlet ethanol extraction to produce and test plant material (essential oils) for their antimicrobial properties. J Microbiol Biol Educ 2014;15:45-6.
13. Tyagi P, Dodwad V, Kukreja BJ, Kukreja P. A comparison of the efficacy of scaling and root planning with application of pomegranate chip, pomegranate gel, and scaling and root planing in sufferers with adult periodontitis – A prospective study. J Indian Soc Periodontol 2021;25:41-6.
14. Supe S, Takudage P. Methods for evaluating penetration of drug into the skin: A review. Skin Res Technol 2021;27:299-308.
15. Könönen E, Gursoy M, Gursoy UK. Periodontitis: A multifaceted disease of tooth-supporting tissues. J Clin Med 2019;8:1135.
16. Drisko CH. Nonsurgical periodontal therapy. Periodontol 2000 2001;25:77-88.
17. Mundinamane D, Suchetha A, Venkataraghavan K, Garg A. Newer trends in local drug delivery for periodontal problems – A preview. Int J Contemp Dent 2011;2:59-62.
18. Sahu NP, Koike K, Jia Z, Nikaido T. Triterpenoid saponins from *Mimusops elengi*. Phytochemistry 1997;44:1145-9.
19. Ali MA, Mozid MA, Yeasmin MS, KhanAM, Sayeed MA. An Evaluation of Antimicrobial Activities of Mimusops elengi Linn. Research Journal of Agriculture and Biological Sciences 2008;4:871-4.
20. Shaik J, Khasim S, Parim B. Protective activity of ethanolic leaf extract of *Mimusops elengi* Linn on lipid peroxidation and antioxidant enzymes in experimental diabetic rats. An International Journal of Advances in Pharmaceutical Sciences 2011;2:2231-541.
21. Gupta N, Jain UK. Investigation of wound healing activity of methanolic extract of stem bark of *Mimusops elengi* Linn. Afr J Tradit Complement Altern Med 2011;8:98-103.